



## HEALTH SCIENCES

# Fisetin Attenuates Paracetamol-Induced Hepatotoxicity by Regulating CYP2E1 Enzyme

RUSTEM A. UGAN, ELIF CADIRCI, HARUN UN, IRFAN CINAR, MUHAMMET A. GURBUZ

**Abstract:** Paracetamol is one of the drugs that cause hepatic damage. Fisetin has wide pharmacological effects such as anticancer, antiinflammatory and antioxidant. We aimed to evaluate the possible protective effect of fisetin on paracetamol-induced hepatotoxicity. Fisetin was administered at 25 and 50 mg/kg doses. Paracetamol was administered orally at a dose of 2 g/kg for induce hepatotoxicity 1 h after the fisetin and NAC treatments. The rats were sacrificed 24h after the Paracetamol administration. Tumor necrosis factor-alpha (TNF- $\alpha$ ), NFkB and CYP2E1 mRNA levels and Superoxide dismutase (SOD) activity, glutathione (GSH) and malondialdehyde (MDA) levels of livers were determined. Serum ALT, AST and ALP levels were measured. Histopathological examinations were also performed. Fisetin administration significantly decreased the ALT, AST and ALP levels in a dose dependent manner. In addition, SOD activity and GSH levels increased, and the MDA level decreased with the treatment of fisetin. The TNF- $\alpha$ , NFkB and CYP2E1 gene expressions were significantly lower in both doses of the fisetin groups compared with the PARA group. Histopathological examinations showed that fisetin has hepatoprotective effects. This study showed that fisetin has the liver protective effects by increasing GSH, decreasing inflammatory mediators and CYP2E1.

**Key words:** Fisetin, rat, paracetamol, hepatotoxicity, TNF- $\alpha$ , CYP2E1.

## INTRODUCTION

Various diseases are now being treated with cost-effective herbal remedies. Expensive synthetic drugs have led developing and poor countries to cheaper drugs. Therefore, it is important to clarify the action mechanisms of natural medicines. Because it reveals new information about alternative treatment approaches of diseases (Kashyap et al. 2018). Fisetin (3,7,3',4'-tetrahydroxy flavone) is a new product of natural origin. It is a dietary, polyphenolic flavonoid found in fruits and vegetables such as onions, cucumbers, apples, grapes, persimmons, nuts and strawberries (Kashyap et al. 2018). Fisetin is known to have broad pharmacological effects such as antitumor (Suh et al. 2010), neurotrophic

(Maher 2006), anti-inflammatory (Higa et al. 2003), antioxidant (Kashyap et al. 2018) and antiangiogenic (Prasath & Subramanian 2013).

Paracetamol (acetaminophen) is one of the most used analgesic and antipyretic drugs in the world. It has a safe profile when used in therapeutic doses (White et al. 2018). However, it can cause hepatotoxicity and even liver transplantation needs when taken in high doses (Larson et al. 2005). Paracetamol is mostly metabolized by sulfate and glucuronide conjugation. A little part (10-15%) of paracetamol is converted into a hepatotoxic substance N-acetyl-para-benzoquinone (NAPQI) if by hepatic cytochrome P450 isoenzymes (most of them are CYP2E1 enzymes) (Bessems &

Vermeulen 2001). NAPQI is deactivated by conjugate with glutathione (GSH) in the liver. In case of paracetamol overdose, the glucuronide and sulfate pathway are saturated, and normal GSH levels in liver cells are not sufficient to inactivate the NAPQI (Koppen et al. 2014, Krenkel et al. 2014). Administration of N-acetyl cysteine (NAC), a GSH precursor, as an antidote in paracetamol toxicity increases the hepatic GSH and detoxifies NAPQI (Lauterburg et al. 1983). However, mortality and morbidity rates are high in paracetamol toxicity despite the use of NAC. Therefore, it would be beneficial to use a reliable food supplement in addition to NAC for the treatment of paracetamol toxicity.

The fact that fisetin is of natural origin and has many beneficial effects brings to mind that it can be applied as a supportive agent for NAC treatment. Namely, fisetin has been shown to have direct antioxidant activity and can also increase intracellular levels of GSH (Murtaza et al. 2009). This effect will be useful when GSH depletion occurs in paracetamol toxicity. Fisetin also reduces the levels of inflammatory cytokines such as tumor necrosis factor- $\alpha$  (TNF- $\alpha$ ), interleukin-6 (IL-6) and IL-1 $\beta$  and inhibits NF- $\kappa$ B activation (Pal et al. 2015, Sakai et al. 2013). In addition, Zhao et al. and Zhang et al. investigated the effects of fisetin on ALT and AST enzymes, and antioxidant parameters in the paracetamol-induced hepatotoxicity model and they found that fisetin alleviates ALT and AST enzymes and increases GSH levels (Zhang et al. 2020, Zhao et al. 2019). In these studies, antioxidant activity of fisetin was demonstrated in paracetamol-induced hepatotoxicity, but its anti-inflammatory effect and its effects on CYP enzyme were not investigated. In our study, we also examined the effects of fisetin on the CYP2E1 enzyme, which plays an important role in the formation of NAPQIs, and the inflammatory mediators on paracetamol-induced hepatotoxicity.

## MATERIALS AND METHODS

### Animals

In our study, 36 male Albino wistar rats weighing 250-300 grams were used. The rats were obtained from Ataturk University Medical Experimental Application and Research Center. The Institutional Animal Care and Use Ethics Committee of Ataturk University approved the study under the protocol number 2018-1/20. The rats were hosted in groups throughout the experiment, under sawdust in plastic cages and a 12/12-hour day/night cycle and a  $22\pm 1^{\circ}\text{C}$  temperature. Standard feed and tap water were given *ad libitum*.

### Chemicals

Fisetin (Alfa Aesar, Haverhill, Massachusetts, ABD), Paracetamol (4-Acetamidophenol, Acros Organisc, Geel, Belgium) N-Acetyl Cysteine (Muconex, Abdi Ibrahim, Istanbul, Turkey), Ketamine (Ketalar, Pfizer), Xylazine (Xylazinbio, Bioveta) were used in our study. Fisetin and NAC were suspended in saline; Paracetamol was suspended in 1% carboximetilcelulos in 1X Phosphate Buffered Saline (PBS). The same amount of saline was administered to the healthy group.

### Experimental groups

Rats were randomly divided into 6 groups (6 rats in each group).

- Group 1: Healthy (Vehicle only)
- Group 2: FIS50 (Only 50 mg/kg Fisetin)
- Group 3: PARA (Only 2 g/kg Paracetamol)
- Group 4: PARA+NAC (140 mg/kg N-Acetyl Cysteine + 2 mg/kg Paracetamol)
- Group 5: PARA+FIS25 (25 mg/kg Fisetin + 2 mg/kg Paracetamol)
- Group 6: PARA+FIS50 (50 mg/kg Fisetin + 2 mg/kg Paracetamol)

### Paracetamol Toxicity Model in Rats

Rats were fasted overnight but with free access to water. Paracetamol was given 1 hour after Fisetin (Hemanth Kumar et al. 2017, Jacob & Thangarajan 2017) and NAC administration to the experimental groups. Fisetin, NAC, and paracetamol were administered orally by gastric gavage. Waited for 24 hours after administration of paracetamol. At the end of the experiment, serum and tissue were obtained. For this purpose, anesthetized animals (with an intraperitoneal administration of a combination of 50 mg/kg ketamine and 15 mg/kg xylazine) were cut through the sternum. The diaphragm was cut without damaging the lungs and approximately 5 cc blood was taken from the heart. Then, the abdomen was cut and the liver was removed and half of the liver was stored at -80°C for biochemical and molecular analysis and the other half was stored in 10% formalin for histopathologic investigations. The blood samples were centrifuged and the serums were stored at -80°C.

### Biochemical analysis

For serum ALT, AST and ALP measurements, a commercial kit (suitable for rat) was purchased from BEN, Milano, Italy and measurements were made on Chemwell Automated Chemistry Analyzer device (Awareness Technology).

Each liver tissue was ground using liquid nitrogen. For this purpose, TissueLyser II (Qiagen, Hilden, Germany) device and stainless-steel balls and jars provided with this device were used. Tissue, liquid nitrogen and steel ball were placed in the jar and immediately the jar tightly closed. Then, it was embedded on the device. The device operated until the tissue was pulverized.

After this process, approximately 100 mg of powdered tissue and 1 ml of PBS in a 2 ml tube was homogenized by TissueLyser II device and then centrifuged. Superoxide dismutase (SOD)

activity (Sun et al. 1988), GSH (Sedlak & Lindsay 1968) and malondialdehyde (MDA) levels (Ohkawa et al. 1979) from each supernatants of liver tissues were measured manually. The modified methods were performed according to our previous studies (Cadirci et al. 2019, Tatar et al. 2015). Briefly, different reagents and standards for SOD, GSH and MDA and supernatants of all samples were added to the wells. They were measured at room temperature by spectrophotometer (Biotek, Epoch, Germany). The absorbances were measured according to the color density and the concentration was determined according to the graphic created with the standards. Protein amounts in the supernatants were measured manually using the Lowry method. The mean absorbance of each sample and standard was calculated. All data were shown as mean  $\pm$  standard deviation (SD) relative to each mg protein.

### Molecular analysis

#### *Liver tissue mRNA extraction and cDNA synthesis*

mRNA extraction and complementary DNA (cDNA) synthesis were performed according to the methods described in our previous studies (Bayir et al. 2019, Ugan et al. 2018). mRNA extraction was performed from previously homogenized liver tissue. The tissue samples in the same group were pooled. 20 mg pooled tissue samples were used for mRNA extraction. Total mRNA was purified using the RNeasy Mini Kit on the QIACUBE (Qiagen, Hilden, Germany) device according to the manufacturer's instructions. RNA samples were reverse transcribed to cDNA using the High Capacity cDNA Reverse Transcription Kit (Applied Biosystems, CA, USA).

#### *Relative quantification of gene expression*

Relative mRNA expressions of TNF- $\alpha$ , NF $\kappa$ B and CYP2E1 were determined from cDNAs obtained from RNAs of rat livers by using the Taqman Gene Expression kit on StepOne Plus Real Time PCR instrument (Applied Biosystems).  $\beta$ -actin was used as housekeeping gene. The mRNA expression was carried out for 40 cycles. All primers are suitable for rat. The assay ID of the taqman primers are as follows: TNF- $\alpha$  (Thermo Fisher Rn00562055\_m1), NF $\kappa$ B (Thermo Fisher Rn01399583\_m1), CYP2E1 (Thermo Fisher Rn00580624\_m1) and  $\beta$ -actin (Thermo Fisher Rn00667869\_m1). Relative mRNA expressions were made using 9  $\mu$ l cDNA (100 ng), 1  $\mu$ l Primer Perfect Probe mix, and 10  $\mu$ l QuantiTect Probe PCR Master mix (Qiagen, Hilden, Germany) for each sample. All data were expressed as fold change in expressions compared to the control (healthy) group using the  $2^{-\Delta\Delta Ct}$  method (Livak & Schmittgen 2001, Ugan et al. 2018).

### Histopathological examination of liver tissues

Histopathological examinations were conducted by rapidly fixing all liver tissues in 10% solution formalin for 48 h. After fixation, all livers samples for histological tissue processing were routinely performed described as previously (Aksak Karamese et al. 2015). After tissue processing, the paraffin blocks were placed

on the semi-automatic microtome device and 5 micrometers thick sections were taken from each block for histopathological examination. Liver tissue slides were performed with hematoxylin and eosin staining according to procedures. Histopathological scoring was performed considering the presence of necrotic and apoptotic cells and signs of inflammation observed in hepatocytes. According to this; finding density symbolized as none (-), mild (+), medium (++) and severe (+++).

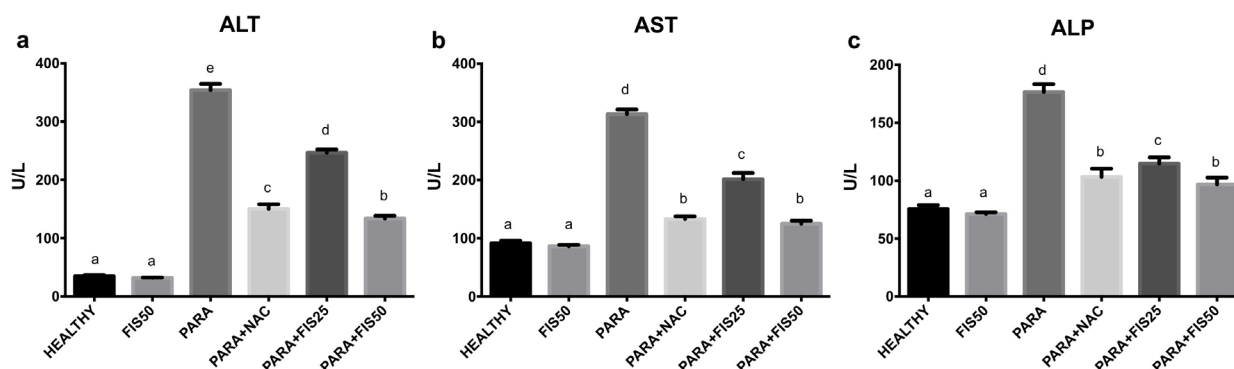
### Statistical analysis

Biochemical and molecular data were applied to one-way analysis of variance (ANOVA) test using the IBM SPSS 20.0 statistical program. The differences between the groups were determined by Duncan multiple comparison test ( $p < 0.05$ ). All results are expressed as mean  $\pm$  SD for each group.

## RESULTS

### The results of serum ALT, AST and ALP levels

The parameters showing liver damage (serum ALT, AST and ALP levels) are summarized in figure 1. When compared to the healthy group, we found that ALT, AST and ALP levels significantly increased in the PARA group. When



**Figure 1. The Results of Serum ALT, AST and ALP Levels.** a: ALT, b: AST, c: ALP. Means with the same letter are not significantly different; means with different letters indicate significant differences between the groups according to the Duncan test ( $p < 0.05$ ). Results are means  $\pm$  SD.

we compared with the PARA group, we found that ALT, AST and ALP levels decreased significantly in the PARA+NAC group. Looking at PARA+FIS25 and PARA+FIS50 groups, we found that ALT, AST and ALP levels significantly decreased in a dose dependent manner. We did not observe a significant difference in ALT, AST and ALP levels of the PARA+NAC and PARA+FIS50 groups when compared with the healthy group.

### The results of SOD activity, GSH and MDA levels in the liver tissue

The results of SOD activity, GSH and MDA levels in the liver tissue of rats are shown in figure 2. When compared to the healthy group, we found that the SOD activity and GSH level significantly decreased and the MDA level significantly increased in the PARA group. When compared to the PARA group, we found that the SOD activity and GSH level significantly increased and the MDA level significantly decreased in the PARA+NAC group. Looking at PARA+FIS25 and PARA+FIS50 groups, we found that SOD activity and GSH level significantly increased and MDA level significantly decreased in a dose dependent manner. We found that there was no statistical difference on MDA level of the PARA+FIS50 group when compared to the healthy group. We did not observe any significant difference in SOD

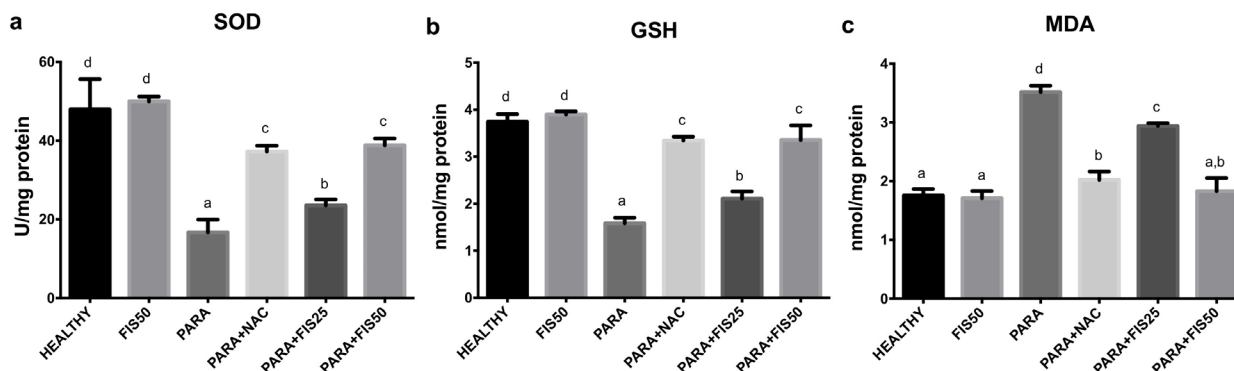
activity, GSH and MDA levels of the PARA+NAC and PARA+FIS50 groups when compared with the healthy group.

### The results of TNF- $\alpha$ , NF $\kappa$ B and CYP2E1 mRNA expression in the liver tissue

The results of TNF- $\alpha$ , NF $\kappa$ B and CYP2E1 mRNA expression are shown in figure 3. Compared to the healthy group, we found that TNF- $\alpha$ , NF $\kappa$ B and CYP2E1 mRNA expressions in the PARA group significantly increased. Compared with the PARA group, we found that TNF- $\alpha$ , NF $\kappa$ B and CYP2E1 mRNA expressions in the PARA+NAC group significantly decreased. Looking at PARA+FIS25 and PARA+FIS50 groups, we found that TNF- $\alpha$ , NF $\kappa$ B and CYP2E1 mRNA expressions decreased significantly in a dose dependent manner. We did not observe a significant difference in TNF- $\alpha$  and NF $\kappa$ B mRNA expressions of the PARA+NAC and PARA+FIS50 when compared with the healthy group.

### Histopathological results

In the healthy group, we observed that the appearance of hepatocytes, central vein and portal areas were normal and sinusoidal ranges were evident. No abnormality was observed in the number and location of Kuppfer cells (Figure 4a). We could not detect any major differences



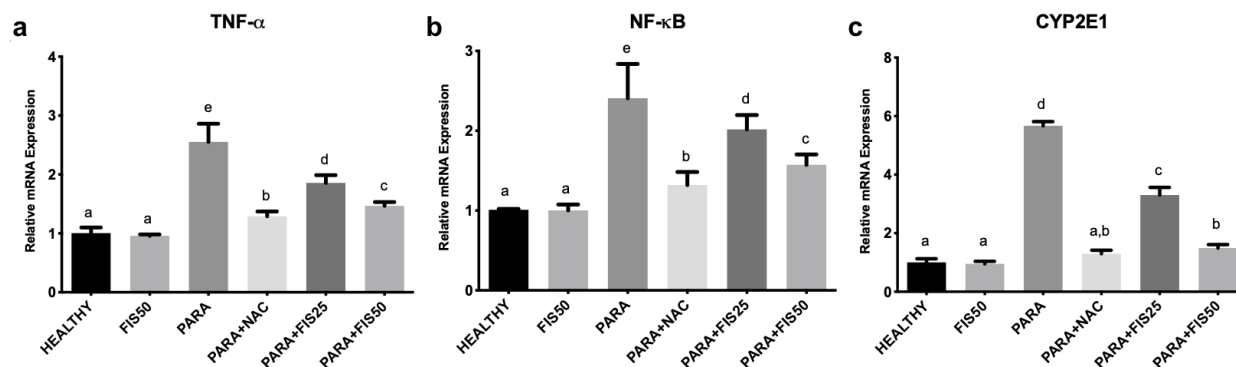
**Figure 2.** The Liver Tissue Oxidative Stress Results. a: SOD, b: GSH, c: MDA. Means with the same letter are not significantly different; means with different letters indicate significant differences between the groups according to the Duncan test ( $p < 0.05$ ). Results are means  $\pm$  SD.

on the histological appearance of the lobules between the FIS50 group and the healthy group (Figure 4b). In the PARA group, severe eosinophilic stained areas were observed in some regions consistent with severe hepatocyte damage and local oriented necrosis findings. Contrary to the severity of parenchymal necrosis, portal inflammation symptoms were very mild. The sinusoidal areas were not prominent except for regions close to the central vein. In some hepatocytes, apoptotic objects with pyknotic nuclei have been identified. The appearance of portal areas was normal (Figure 4c). In the PARA+NAC group, although the general appearance of the section is similar to the healthy group, balloon degeneration characterized by diffuse swelling, pale staining and empty appearance of the cytoplasm was detected in hepatocytes located around the central vein (Figure 4d). In the PARA+FIS25 group, eosinophilic appearance without necrotic findings was observed in the regions of the lobule close to the periportal area. The appearance and cellular integrity of the hepatocytes was normal. Hepatic sinusoids were still not apparent. The appearance of portal areas was normal. Although there were signs of improvement, histopathological findings similar to the PARA group persist in the sectional area (Figure 4e). The general view in the PARA+FIS50 group is

similar to the healthy group. Cellular integrity and staining characteristics of hepatocytes were equivalent to healthy group. Sinusoidal areas were evident. Portal areas and central vein were normally observed. It was analyzed that the high dose fisetin prevented the destructive effects of paracetamol (Figure 4f). The histopathological findings are summarized in table I.

## DISCUSSION

The increase in GSH level is important for preventing paracetamol induced liver damage. NAC is used as an antidote for paracetamol toxicity due to its GSH precursor feature (Yayla et al. 2014). However, despite the use of NAC, mortality and morbidity rates are high in paracetamol toxicity. For this reason, it would be beneficial to use an alternative treatment strategy combined with NAC for the treatment of paracetamol toxicity (Raskovic et al. 2019). For this purpose, we examined the effects of natural origin fisetin on paracetamol-induced hepatotoxicity. We examined the effects of fisetin on liver enzymes. We have seen that it ameliorates liver enzymes such as ALT, AST, ALP, and CYP2E1. In addition, we found that it increases GSH levels and SOD activity and decreases MDA levels. We have seen that fisetin reduces the levels of TNF- $\alpha$  and NF- $\kappa$ B.

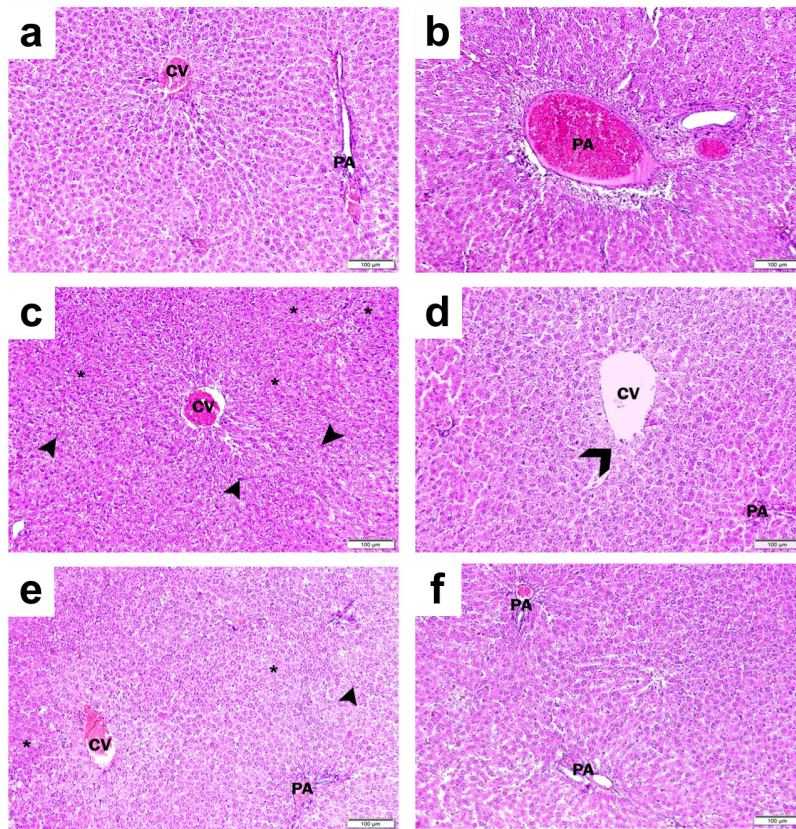


**Figure 3.** The Results of Relative mRNA Expression of TNF- $\alpha$ , NF- $\kappa$ B and CYP2E1. a: TNF- $\alpha$ , b: NF- $\kappa$ B, c: CYP2E1. Means with the same letter are not significantly different; means with different letters indicate significant differences between the groups according to the Duncan test ( $p < 0.05$ ). Results are means  $\pm$  SD.



The important parameters in the evaluation of general liver damage and paracetamol toxicity are liver enzymes (Khodayar et al. 2020). For this purpose, we firstly detected ALT, AST and ALP serum levels, which are biomarkers of liver damage. These enzymes are very sensitive markers and should be determined first in the liver damage (Rajesh & Latha 2004, Yayla et al. 2014). On the other hand, Cytochrome P450 (especially CYP2E1) enzymes also have important roles in paracetamol metabolism and it has been reported that the formed metabolites may cause to severe hepatotoxicity (Laine et al. 2009). Looking at our current study, we found that paracetamol increased the mRNA expressions of CYP2E1 and fisetin administration reduced the mRNA expressions of CYP2E1 in a dose dependent manner. We demonstrated that fisetin reduces mRNA expression of the CYP2E1 enzyme of the liver tissue. It is known

that the amount of CYP2E1 enzyme increases in cases of paracetamol hepatotoxicity and when the amount of CYP2E1 enzyme decreases, the liver damage reduces (Walubo et al. 2004). On the other hand, we found that the serum levels of ALT, AST and ALP enzymes increased in the PARA group. We observed that the serum levels of liver enzymes decreased with administration of both doses of fisetin. In a study on liver toxicity that is similar to our study, Hussein et al. found that ALT, AST and ALP enzyme values increased in the liver toxicity and this increase improved with fisetin treatment (Hussein et al. 2018). In another study, fisetin decreased ALT, AST levels in mice with liver toxicity (Zhao et al. 2019). Consequently, these reductions in liver enzymes are evidence of the liver-protective effect of fisetin. Additionally, we also performed histological examination to support our finding. We found that fisetin improves the histological



**Figure 4. Results of Histopathological Hematoxylin-Eosin Staining of (CV: Central Vein, PA: Portal Area, \*: Necrotic Areas, Arrow Heads: Apoptotic Bodies). a: Healthy, b: FIS50, c: PARA, d: PARA+NAC, e: PARA+FIS25, f: PARA+FIS50.**

parameters in paracetamol induced liver damage.

Other possible markers of liver damage are GSH depletion and oxidative stress (Kaya et al. 2018). Fisetin has been shown to have direct antioxidant activity and can also directly increase intracellular levels of GSH (Murtaza et al. 2009). In the light of this information, we aimed to show that fisetin plays an important role in paracetamol-induced liver toxicity in our current study. For this purpose, we measured the amount of GSH, which is the main mechanism for preventing paracetamol hepatotoxicity. GSH plays a key role in detoxification of NAPQI against liver damage, as well as sweeping reactive oxygen species (Jaeschke 1990). Because of these features, GSH has two mechanisms to prevent liver toxicity. In our measurements, we found that the GSH level decreased in the PARA group compared with the healthy group. We found that GSH levels increased with both doses of fisetin. The increasing of GSH level with fisetin administration provides the metabolism of large amounts of paracetamol and prevents the development of hepatotoxicity. Fisetin also provides additional protection by showing antioxidant activity. Paracetamol toxicity causes the production of reactive oxygen species, which can cause a hydrogen atom to be isolated from an unsaturated lipid and initiate lipid peroxidation. The lipid peroxidation causes significant

changes in membrane structure and cell functions, and causes DNA damage, cytotoxicity and eventually cell death. As an indicator of lipid peroxidation, measuring MDA levels is essential in determining oxidative stress (Fouad & Jresat 2012). In this study, when we compared with the healthy group, we found that the MDA level increased in the PARA group. However, we found that increased MDA levels decreased with the administration of fisetin. Also, antioxidant enzymes are of importance to prevent oxidative damage in paracetamol-induced hepatotoxicity (Chiu et al. 2003). In this study, we also measured the SOD activity, an antioxidant enzyme. We found that the SOD enzyme activity in the liver also decreased in the PARA group. On the other hand, we found that administration of fisetin at both doses increased SOD activity. All these effects may be due to the potential antioxidant activities of fisetin. In a study that supports our present study, fisetin has been shown to reduce reactive oxygen radicals and restore the level of GPX, GST and other antioxidant enzymes (Zhao et al. 2019). In addition, fisetin has been shown to reduce myeloperoxidase levels in another study (Pal et al. 2015).

In addition to oxidative stress, various complex mechanisms such as inflammatory mediators have been found to be pathways associated with paracetamol toxicity (Yayla et al. 2014). TNF- $\alpha$  is one of the most important

**Table I. Histopathological Results.**

GROUPS	Necrotic Areas	Apoptotic Objects	Inflammation
HEALTHY	-	-	-
FIS50	-	-	-
PARA	+++	++	+
PARA+NAC	+	+	-
PARA+FIS 25	++	+	-
PARA+FIS 50	-	-	-



pro-inflammatory cytokines that mediate acute phase responses of various hepatotoxic substances such as paracetamol (Uzkeser et al. 2012). The rise of TNF- $\alpha$  levels is also closely related to NF- $\kappa$ B levels (Ugan et al. 2018). In the study researching the effects of fisetin on paracetamol toxicity, Licong et al. have investigated corrective effects of fisetin on the antioxidants and liver enzymes (Zhao et al. 2019). However, the levels of cytokines, which are important pathways in paracetamol toxicity, were not examined. In our current study, we also examined the effects of fisetin on TNF- $\alpha$  and NF- $\kappa$ B levels, which have important roles in paracetamol-induced hepatotoxicity. We found that TNF- $\alpha$  and NF- $\kappa$ B levels increased in the PARA group. Compared with the PARA group, we found that the TNF- $\alpha$  and NF- $\kappa$ B levels were decreased in the PARA+NAC and PARA+FIS groups. The previous studies support our present work. It has been shown that TNF- $\alpha$  inhibition can protect paracetamol induced liver toxicity in a previous study (Yayla et al. 2014). It has been shown in many studies that fisetin has anti-inflammatory potential via the NF- $\kappa$ B signal pathway and reduces TNF- $\alpha$  levels. (Kashyap et al. 2018, Pal et al. 2015, Wu et al. 2011).

The findings in these studies and in our current study showed that fisetin not only has antioxidant properties but also decreases liver toxicity by reducing the mRNA expressions of CYP2E1 enzymes and cytokines such as TNF- $\alpha$  and NF- $\kappa$ B. As a result of these effects of fisetin, we can say that it contributes to normalization of liver enzymes in biochemical examination and liver structures in histopathological examination.

All these results demonstrate that fisetin is effective to protect paracetamol-induced liver damage. Fisetin shows the liver protective effects by increasing GSH and improving liver enzymes such as ALT and AST, as well as cytochrome

P450 enzymes such as CYP2E1. Moreover, fisetin improves antioxidant defense system, decreases oxidative stress and TNF- $\alpha$  and NF- $\kappa$ B mRNA expression levels. More research is needed to better clarify the protective effects of fisetin on paracetamol hepatotoxicity.

### Acknowledgments

This study was supported by Ataturk University Scientific Research Projects Coordination office. Project number: TSA-2018-6612.

### REFERENCES

- AKSAK KARAMESE S, TOKTAY E, UNAL D, SELLI J, KARAMESE M & MALKOC I. 2015. The protective effects of beta-carotene against ischemia/reperfusion injury in rat ovarian tissue. *Acta Histochem* 117(8): 790-797.
- BAYIR Y, UN H, UGAN RA, AKPINAR E, CADIRCI E, CALIK I & HALICI Z. 2019. The effects of Beeswax, Olive oil and Butter impregnated bandage on burn wound healing. *Burns* 45(6): 1410-1417.
- BESSEMS JG & VERMEULEN NP. 2001. Paracetamol (acetaminophen)-induced toxicity: molecular and biochemical mechanisms, analogues and protective approaches. *Crit Rev Toxicol* 31(1): 55-138.
- CADIRCI E, UGAN RA, DINCER B, GUNDOGDU B, CINAR I, AKPINAR E & HALICI Z. 2019. Urotensin receptors as a new target for CLP induced septic lung injury in mice. *Naunyn Schmiedebergs Arch Pharmacol* 392(2): 135-145.
- CHIU H, GARDNER CR, DAMBACH DM, BRITTINGHAM JA, DURHAM SK, LASKIN JD & LASKIN DL. 2003. Role of p55 tumor necrosis factor receptor 1 in acetaminophen-induced antioxidant defense. *Am J Physiol Gastrointest Liver Physiol* 285(5): G959-966.
- FOUAD AA & JRESAT I. 2012. Hepatoprotective effect of coenzyme Q10 in rats with acetaminophen toxicity. *Environ Toxicol Pharmacol* 33(2): 158-167.
- HEMANTH KUMAR B, ARUN REDDY R, MAHESH KUMAR J, DINESH KUMAR B & DIWAN PV. 2017. Effects of fisetin on hyperhomocysteinemia-induced experimental endothelial dysfunction and vascular dementia. *Can J Physiol Pharmacol* 95(1): 32-42.
- HIGA S, HIRANO T, KOTANI M, MATSUMOTO M, FUJITA A, SUEMURA M, KAWASE I & TANAKA T. 2003. Fisetin, a flavonol, inhibits TH2-type cytokine production by activated human basophils. *J Allergy Clin Immunol* 111(6): 1299-1306.

- HUSSEIN SA, RAGAB OA, EL SENOSI YA & ABDEL-MUTTALIB SA. 2018. Biochemical Effect of Fisetin on Experimentally Induced Liver Damage in Rats. *Benha Veterinary Medical Journal* 34(3): 98-107.
- JACOB S & THANGARAJAN S. 2017. Effect of Gestational Intake of Fisetin (3,3',4',7-Tetrahydroxyflavone) on Developmental Methyl Mercury Neurotoxicity in F1 Generation Rats. *Biol Trace Elem Res* 177(2): 297-315.
- JAESCHKE H. 1990. Glutathione Disulfide Formation and Oxidant Stress during Acetaminophen-Induced Hepatotoxicity in Mice *In Vivo* - the Protective Effect of Allopurinol. *J Pharmacol Exp Ther* 255(3): 935-941.
- KASHYAP D, SHARMA A, SAK K, TULI HS, BUTTAR HS & BISHAYEE A. 2018. Fisetin: A bioactive phytochemical with potential for cancer prevention and pharmacotherapy. *Life Sci* 194: 75-87.
- KAYA H, POLAT B, ALBAYRAK A, MERCANTEPE T & BUYUK B. 2018. Protective effect of an L-type calcium channel blocker, amlodipine, on paracetamol-induced hepatotoxicity in rats. *Hum Exp Toxicol* 37(11): 1169-1179.
- KHODAYAR MJ, KALANTARI H, KHORSANDI L, RASHNO M & ZEIDOOONI L. 2020. Upregulation of Nrf2-related cytoprotective genes expression by acetaminophen-induced acute hepatotoxicity in mice and the protective role of betaine. *Hum Exp Toxicol* 39(7): 948-959.
- KOPPEN A, VAN RIEL A, DE VRIES I & MEULENBELT J. 2014. Recommendations for the paracetamol treatment nomogram and side effects of N-acetylcysteine. *Neth J Med* 72(5): 251-257.
- KRENKEL O, MOSSANEN JC & TACKE F. 2014. Immune mechanisms in acetaminophen-induced acute liver failure. *Hepatobiliary Surg Nutr* 3(6): 331-343.
- LAINE JE, AURIOLA S, PASANEN M & JUVONEN RO. 2009. Acetaminophen bioactivation by human cytochrome P450 enzymes and animal microsomes. *Xenobiotica* 39(1): 11-21.
- LARSON AM ET AL. 2005. Acetaminophen-induced acute liver failure: results of a United States multicenter, prospective study. *Hepatology* 42(6): 1364-1372.
- LAUTERBURG BH, CORCORAN GB & MITCHELL JR. 1983. Mechanism of action of N-acetylcysteine in the protection against the hepatotoxicity of acetaminophen in rats *in vivo*. *J Clin Invest* 71(4): 980-991.
- LIVAK KJ & SCHMITTGEN TD. 2001. Analysis of relative gene expression data using real-time quantitative PCR and the 2(-Delta Delta C(T)) Method. *Methods* 25(4): 402-408.
- MAHER P. 2006. A comparison of the neurotrophic activities of the flavonoid fisetin and some of its derivatives. *Free Radic Res* 40(10): 1105-1111.
- MURTAZA I, ADHAMI VM, HAFEEZ BB, SALEEM M & MUKHTAR H. 2009. Fisetin, a natural flavonoid, targets chemoresistant human pancreatic cancer AsPC-1 cells through DR3-mediated inhibition of NF-kappaB. *Int J Cancer* 125(10): 2465-2473.
- OHKAWA H, OHISHI N & YAGI K. 1979. Assay for lipid peroxides in animal tissues by thiobarbituric acid reaction. *Anal Biochem* 95(2): 351-358.
- PAL HC, ATHAR M, ELMETS CA & AFAQ F. 2015. Fisetin inhibits UVB-induced cutaneous inflammation and activation of PI3K/AKT/NFkappaB signaling pathways in SKH-1 hairless mice. *Photochem Photobiol* 91(1): 225-234.
- PRASATH GS, & SUBRAMANIAN SP. 2013. Fisetin, a tetra hydroxy flavone recuperates antioxidant status and protects hepatocellular ultrastructure from hyperglycemia mediated oxidative stress in streptozotocin induced experimental diabetes in rats. *Food Chem Toxicol* 59: 249-255.
- RAJESH MG & LATHA MS. 2004. Preliminary evaluation of the antihepatotoxic activity of Kamilari, a polyherbal formulation. *J Ethnopharmacol* 91(1): 99-104.
- RASKOVIC A ET AL. 2019. Hepatoprotective and antioxidant potential of Pycnogenol(R) in acetaminophen-induced hepatotoxicity in rats. *Phytother Res* 33(3): 631-639.
- SAKAI E, SHIMADA-SUGAWARA M, YAMAGUCHI Y, SAKAMOTO H, FUMIMOTO R, FUKUMA Y, NISHISHITA K, OKAMOTO K & TSUKUBA T. 2013. Fisetin inhibits osteoclastogenesis through prevention of RANKL-induced ROS production by Nrf2-mediated up-regulation of phase II antioxidant enzymes. *J Pharmacol Sci* 121(4): 288-298.
- SEDLAK J & LINDSAY RH. 1968. Estimation of total, protein-bound, and nonprotein sulfhydryl groups in tissue with Ellman's reagent. *Anal Biochem* 25(1): 192-205.
- SUH Y, AFAQ F, KHAN N, JOHNSON JJ, KHUSRO FH & MUKHTAR H. 2010. Fisetin induces autophagic cell death through suppression of mTOR signaling pathway in prostate cancer cells. *Carcinogenesis* 31(8): 1424-1433.
- SUN Y, OBERLEY LW & LI Y. 1988. A simple method for clinical assay of superoxide dismutase. *Clin Chem* 34(3): 497-500.
- TATAR A, PARLAK SN, YAYLA M, UGAN RA, POLAT E & HALICI Z. 2015. Effects of allergic rhinitis and desloratadine on the submandibular gland in a rat allergy model. *Int Forum Allergy Rhinol* 5(12): 1164-1169.

UGAN RA, CADIRCI E, HALICI Z, TOKTAY E & CINAR I. 2018. The role of urotensin-II and its receptors in sepsis-induced lung injury under diabetic conditions. *Eur J Pharmacol* 818: 457-469.

UZKESER M, KARAKUS E, ALBAYRAK A, KIKI I, BAYIR Y, CADIRCI E, UNAL D, HALICI Z & KARADENIZ A. 2012. Protective effect of Panax ginseng against N-acetyl-p-aminophenol-induced hepatotoxicity in rats. *Afr J Pharm Pharmacol* 6(36): 2634-2642.

WALUBO A, BARR S, ABRAHAM AM & COETSEE C. 2004. The role of cytochrome-P450 inhibitors in the prevention of hepatotoxicity after paracetamol overdose in rats. *Hum Exp Toxicol* 23(1): 49-54.

WHITE WB, KLONER RA, ANGIOLILLO DJ & DAVIDSON MH. 2018. Cardiorenal Safety of OTC Analgesics. *J Cardiovasc Pharmacol Ther* 23(2): 103-118.

WU MY, HUNG SK & FU SL. 2011. Immunosuppressive effects of fisetin in ovalbumin-induced asthma through inhibition of NF-kappaB activity. *J Agric Food Chem* 59(19): 10496-10504.

YAYLA M, HALICI Z, UNAL B, BAYIR Y, AKPINAR E & GOCER F. 2014. Protective effect of Et-1 receptor antagonist bosentan on paracetamol induced acute liver toxicity in rats. *Eur J Pharmacol* 726: 87-95.

ZHANG J ET AL. 2020. Fisetin Prevents Acetaminophen-Induced Liver Injury by Promoting Autophagy. *Front Pharmacol* 11: 162.

ZHAO L, ZHANG J, PAN L, CHEN L, WANG Y, LIU X, YOU L, JIA Y & HU C. 2019. Protective effect of 7,3',4'-flavon-3-ol (fisetin) on acetaminophen-induced hepatotoxicity in vitro and in vivo. *Phytomedicine* 58: 152865.

#### How to cite

UGAN RA, CADIRCI E, UN H, CINAR I & GURBUZ MA. 2023. Fisetin Attenuates Paracetamol-Induced Hepatotoxicity by Regulating CYP2E1 Enzyme. *An Acad Bras Cienc* 95: e20201408. DOI 10.1590/0001-3765202320201408.

*Manuscript received on August 31, 2020;  
accepted for publication November 14, 2020*

#### RUSTEM A. UGAN<sup>1,3</sup>

<https://orcid.org/0000-0002-4837-2343>

#### ELIF CADIRCI<sup>2,3</sup>

<https://orcid.org/0000-0003-0836-7205>

#### HARUN UN<sup>4</sup>

<https://orcid.org/0000-0003-1772-282X>

#### IRFAN CINAR<sup>5</sup>

<https://orcid.org/0000-0002-9826-2556>

#### MUHAMMET A. GURBUZ<sup>6</sup>

<https://orcid.org/0000-0001-8750-2393>

<sup>1</sup>Ataturk University, Faculty of Pharmacy, Department of Pharmacology, 25240, Erzurum, Turkey

<sup>2</sup>Ataturk University, Faculty of Medicine, Department of Pharmacology, 25240, Erzurum, Turkey

<sup>3</sup>Ataturk University, Clinical Research, Development and Design Application and Research Center, 25240, Erzurum, Turkey

<sup>4</sup>Agri Ibrahim Cecen University, Faculty of Pharmacy, Department of Biochemistry, 04100, Agri, Turkey

<sup>5</sup>Kafkas University, Faculty of Medicine, Department of Pharmacology, Kars, 36200, Turkey

<sup>6</sup>Ataturk University, Faculty of Medicine, Department of Histology and Embryology, 25240, Erzurum, Turkey

Correspondence to: **Rustem Anil Ugan**

E-mail: [anil.ugan@atauni.edu.tr](mailto:anil.ugan@atauni.edu.tr)

#### Author contributions

RAU conceived and designed research. RAU, HU, IC and MAG conducted experiments. EC contributed new reagents or analytical tools. RAU and EC analyzed data. RAU wrote the manuscript. All authors read and approved the manuscript.

