

Ebstein's Anomaly. Results of the Conic Reconstruction of the Tricuspid Valve

José Pedro da Silva, José Francisco Baumgratz, Luciana da Fonseca, Jorge Yussef Afiune, Sônia Meiken Franchi, Lillian Maria Lopes, Daniel Marcelo Silva Magalhães, José Henrique Andrade Vila

São Paulo, SP - Brazil

Objective - To assess the results of a technical modification of tricuspid valvuloplasty in Ebstein's anomaly.

Methods - From November 1993 to August 2002, 21 patients with Ebstein's anomaly of the tricuspid valve, with ages ranging from 20 months to 37 years (mean, 23 years), underwent a new technique of tricuspid valvuloplasty. This technique consisted of total or almost total detachment of the anterior tricuspid megaleaflet from the ventricular wall and valvular ring, transforming it into a cone, whose vertex remained fixed in the right ventricular tip, and the base was sutured to the tricuspid ring, after its plication, adjusting it to the size of the base of the cone (tricuspid ring), including the septal region.

Results - One (4.7%) patient with cardiomyopathy caused by chronic hypoxia died in the hospital due to low cardiac output. The mean follow-up lasted 4 years, and the recent echocardiograms showed good morphology of the right ventricle and tricuspid valve with mild or minimal insufficiency in 18 patients and moderate insufficiency in 2 patients. In 2 of the 3 patients with an anomalous bundle, it could be located and sectioned during surgery. No atrioventricular block occurred.

Conclusion - The technique used was efficient in repairing tricuspid insufficiency and restoring right ventricular morphology, being applicable to all anatomic types of Ebstein's anomaly, except for Carpentier classification type D.

Key words: Ebstein's anomaly, tricuspid insufficiency, tricuspid valvuloplasty

Ebstein's anomaly of the tricuspid valve is a rare congenital heart disease, treated with various surgical techniques since 1958^{1,2}. Until the 1970s, valvular replacement was the treatment of choice, despite its association with severe complications, such as arrhythmias, thrombosis, prosthetic dysfunction, in addition to a high mortality rate³.

The Danielson method⁴ was the most used tricuspid valvuloplasty procedure for correcting Ebstein's anomaly in the 1980s. However, as that surgery does not provide good geometry for the right ventricle and is not applicable to a large number of patients, tricuspid valve replacement with a prosthesis is required in 35.6% of the cases.

Carpentier et al⁵ classified the various anatomical presentations of the disease and proposed a new technique, which consists of the reconstruction of the right ventricle form and repositioning of the tricuspid valve at the normal level with the routine use of a prosthetic ring. This surgery was carefully described and reported on in 1988⁵. Quagebeur et al⁶ used a similar surgery, but without the prosthetic ring, in a younger population.

Since 1989, we have been using a surgical technique consisting of total or almost total detachment of the anterior tricuspid megaleaflet from the ventricular wall and valvular ring, transforming it into a cone, whose vertex remained fixed in the right ventricular tip and the base was sutured to the tricuspid ring, after its plication, adjusting it to the size of the base of the cone (tricuspid ring), including the septal region. This study aimed at analyzing the late results of this technique, whose principle is similar to that of the Carpentier technique, but with reconstruction of the septal portion of the tricuspid valve, not requiring the use of a prosthetic ring.

Methods

From November 1993 to August 2001, 21 patients with Ebstein's anomaly of the tricuspid valve were operated on at our institution by using the technique described below. The ages ranged from 20 months to 37 years (mean of 23 years), and 10 (48%) patients were men.

Hospital São Joaquim da Real e Benemerita Sociedade Portuguesa de Beneficência
Mailing address: José Pedro da Silva - Rua Maestro Cardim, 769 - S/202
Cep 01323-001 - Paraíso - São Paulo, SP, Brazil - E-mail: clinicajpgdasilva@uol.com.br
Received: 12/30/02
Accepted: 04/07/03
English version by Stela Maris C. e Gandour

The clinical presentations were as follows: dyspnea in 17 (80%) patients, cyanosis in 15 (71%), arrhythmia in 6 (28%), and low cardiac output syndrome in 3 (14%). In regard to associated diseases, 8 (21%) patients had patent oval foramen, 9 (42%) had interatrial septal defect, and 3 (14%) had anomalous atrioventricular bundle [Wolf-Parkinson-White syndrome (WPW)]. Pulmonary stenosis was observed in 1 (4.7%) patient, significant mitral insufficiency in 1, and interventricular septal defect in another patient.

The preoperative echocardiographies showed significant tricuspid insufficiency in 12 (57.8%) patients and moderate insufficiency in 9 (42.7%).

Surgical technique - After installing extracorporeal circulation with bicaval cannulation, and infusing blood cardioplegia for myocardial protection, an oblique right atriotomy was performed (fig. 1). The anterior tricuspid megaleaflet was totally or partially detached from the ventricular wall and valvular ring, its free margin being rotated clockwise, transforming it into a cone whose vertex remained fixed in the tip of the right ventricle by the chordae tendineae and papillary muscles. The base (tricuspid leaflets) was then sutured in the tricuspid ring in its true position, in the threshold between the right atrium and the atrialized right ventricle, after plication of the ring, which had its diameter adjusted to the size of the base of the cone (tricuspid ring). This technique also reconstructs the septal portion of the tricuspid valve, in which a delicate and superficial suture is used in the proximity of the atrioventricular conduction system. In 5 patients, some fenestrations were created in the leaflet to facilitate the entrance of blood into the right ventricle. In 2 cases, misplaced papillary muscles needed to be transferred to the proximities of the right ventricular apex. No prosthetic ring was used for the tricuspid valve in this series of patients.

A valved interatrial communication was left, allowing the passage of blood from right to left. This was obtained with the partial closure of the oval foramen and the interatrial septal defect with appropriate techniques and the oblique opening in the superior margin of the fossa ovalis in the cases of intact interatrial septum. The following surgical procedures were associated with tricuspid valvuloplasty: section of the anomalous bundle in 2 patients; ventriculoseptoplasty in 1 patient; and enlargement of the right ventricular outflow tract with a valved graft (monocuspid) of bovine pericardium and mitral valvuloplasty in another.

Results

One (4.7%) patient with biventricular cardiomyopathy caused by chronic hypoxia died during hospitalization. Although the tricuspid valvuloplasty was effective, the biventricular insufficiency with low cardiac output led to multi-system organ failure, culminating in death on the fourth postoperative day.

The first patient in this series underwent surgery at the age of 11 years and required reoperation 4 years later, when a new valvuloplasty was performed. Currently, the patient is in excellent clinical condition, with age-appropriate height

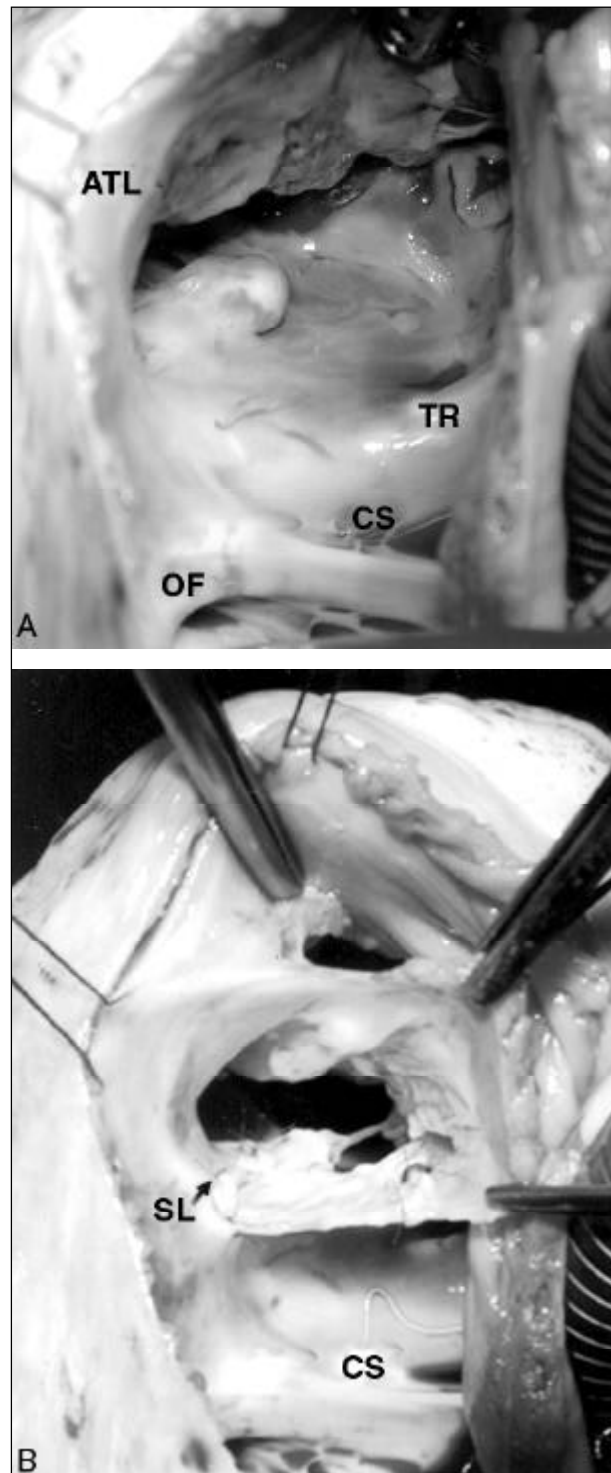


Fig. 1 - Surgical features of tricuspid valvuloplasty in Ebstein's anomaly. A) Anatomic features of the anomalous insertion of the posterior and septal leaflets of the tricuspid valve; B) Tricuspid valve partially detached from the ventricular wall, clockwise rotated, forming a cone.

CS - coronary sinus; TR - tricuspid ring; OF - oval foramen; ATL - anomalous tricuspid leaflet; SL - suture line.

and weight development. Another patient developed severe biventricular cardiomyopathy after 7 years. The other patients evolved with no intercurrent events and remained asymptomatic.

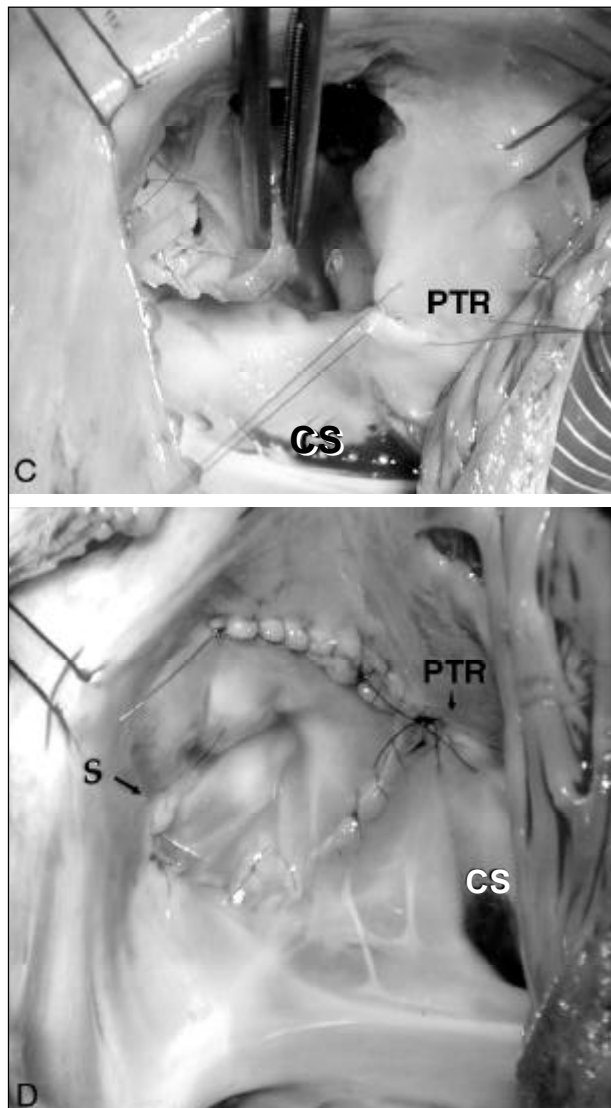


Fig. 1 - Surgical features of tricuspid valvuloplasty in Ebstein's anomaly. C) Plication of the true tricuspid ring; D) Tricuspid valve sutured in the true ring, correcting the insufficiency.

CS - coronary sinus; PTR- plication of the tricuspid ring.

One patient gave birth to a healthy baby after an uneventful pregnancy 2 years after surgery.

Two patients with WPW in the preoperative period had successful sectioning of the anomalous bundle, while, in a third patient, the bundle could not be located during surgery. No atrioventricular block was observed in the patients.

The recent echocardiograms showed a good surgical result in all patients, with a good morphology of the tricuspid valve and right ventricle, and minimum or mild tricuspid insufficiency (fig. 2) after a mean follow-up of 4 years. One (4.7%) patient had moderate tricuspid insufficiency on the postoperative echocardiography, with no clinical symptoms.

Discussion

The surgical indications in Ebstein's anomaly are well defined for the following patients: 1) symptomatic, in NYHA

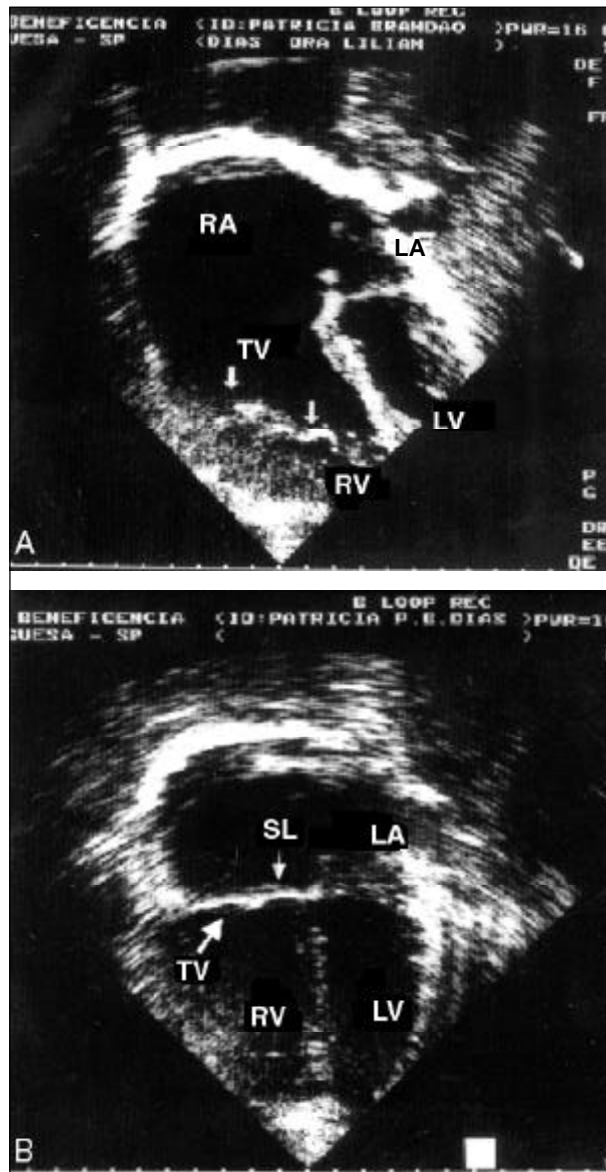


Fig. 2 - A) Preoperative echocardiogram showing the anomalous insertion of the tricuspid valve leaflet. B) Postoperative echocardiogram of the same patient, showing the good position of the tricuspid valve at the same level as that of the mitral valve. RA - right atrium; LA - left atrium; RV - right ventricle; LV - left ventricle; TV - tricuspid valve; SL - septal leaflet.

functional class III or IV; 2) in functional class I or II, with cardiomegaly and a cardiothoracic index of 0.65 or greater; 3) significant cyanosis and polycythemia; 4) presence of paradoxical embolism; 5) presence of uncontrollable tachycardia and accessory AV bundle.

In the natural history of the disease, a significant increase in mortality is observed in adulthood due to the development of congestive heart failure or arrhythmias^{7,8}. The sudden death caused by arrhythmias not related to WPW occurs in 60% (CL 43%-77%) of the patients with Ebstein's anomaly who die due to cardiac causes^{9,10}. Sudden death correlates more with cardiomegaly than with functional class (NYHA)⁹. Paradoxical embolism or cerebral abscess is an important cause of death, mainly in patients > 50 years¹¹.

The nonoperated on asymptomatic patients, when

compared with healthy people, have a limited tolerance for exercise and a reduction in the capacity to work¹², being, therefore, indicated for serial exercise tests to objectively define their physical limitations and their long-term evolution. The development of simpler techniques of valvuloplasty, with lower surgical risks, remodeling of the right ventricle, and lower index of valvular replacement may broaden the surgical indication for this group of patients.

Anatomical and echocardiographic studies, as well as surgical experience, suggest that the right ventricle (its form, compliance, and contractility) may be a factor as important as tricuspid dysfunction in the pathophysiology of this disease. The main objective of the surgery proposed by Carpentier et al⁵ was to restore right ventricular volume and form.

The technique here described uses the innovative principle of Carpentier et al, which consists of detaching the dislocated tricuspid valve from the interior of the right ventricle, bringing it to the normal level of the tricuspid ring, ie, leaving the atrialized portion of the right ventricle in the subvalvular position. However, the technique used in this study is different in regard to the clockwise rotation of the lateral margin of the tricuspid valve megaleaflet, forming a cone, and ignoring the septal leaflet when it is anomalous. The suture of the base of this cone is performed at the normal level of the tricuspid ring, including its septal portion, where the suture line has to be very superficial, avoiding atrioventricular block, a complication not observed in this series of patients. Another difference is the non use of the prosthetic tricuspid ring in any of the cases, while Carpentier recommended its use in most cases⁵. Quaegebeur et al⁶ reported a technique similar to that of Carpentier, which was used in younger patients, with no prosthetic ring, but also without covering the septal portion of the tricuspid ring.

Our technique assures the reconstruction of the tricuspid valve in its septal portion, avoiding significant regurgitation in the short- and long-term. These results were demonstrated in the postoperative echocardiograms (fig.2), which evidenced good positioning of the tricuspid valve and restoration of the normal ventricular morphology.

No atrioventricular block occurred in any patient, which coincides with the experience of Wu and Huang¹³, who, in a more recent series, used fresh autologous pericardium in some patients to reconstruct the septal portion of the tricuspid valve, suturing it in the septal part of the ring. Similarly to our case series, no case of atrioventricular block was observed after manipulation of the septal portion. However, this suture should be very superficial. Due to the total coverage of the area of the tricuspid orifice and to restoration of the tricuspid ring to its normal position and size, the valve became competent, with mild insufficiency in 6 patients, all being in functional class I.

None of the authors showed concern in regard to the interatrial septal defect, performing its routine closure. In our case series, we always left a valved interatrial communication, allowing flow only from right to left when the right atrial pressure increased. This was useful in the postoperative period of 3 patients, who had significant right ventricular dysfunction, but maintained good cardiac output due to mild oxygen desaturation.

The results obtained with this technique in this group of patients, from the anatomic and functional points of view, are encouraging. The early death in our series does not relate to the surgical technique, but to the preoperative state of the patient, which indicates that surgical intervention should have been taken earlier before deterioration of right and left ventricular function.

In conclusion, the technique reported is efficient for correcting tricuspid insufficiency and restoring right ventricular morphology, being applicable to all anatomic types of Ebstein's anomaly, except for Carpentier classification type D.

This technique, which does not require the use of prosthesis, may extend the surgical indication to asymptomatic or oligosymptomatic patients to prevent the appearance of late complications, such as arrhythmia and ventricular dysfunction.

Further studies with larger case series are required to determine the probable advantages of this technique as compared with that of Carpentier.

References

1. Hunter SW, Lillehei CW. Ebstein malformation of the tricuspid valve. Study of a case together with suggestions of a new form of surgical therapy. *Chest Disease* 1958; 33: 297-304.
2. Hardy KL, May IA, Webster CA, Kimball KG. Ebstein's anomaly: a functional concept and successful definitive repair. *J Thorac Cardiovasc Surg* 1964; 48: 927-940.
3. Barbero-Marcial M, Verginnelli G, Awad M, Ferreira S, Ebaïd m, Zerbini EJ. Surgical treatment of Ebstein's anomaly. Early and late results in twenty patients subjected to valve replacement. *J Thorac Cardiovasc Surg* 1979; 78: 416-422.
4. Danielson GK, Driscoll DJ, Mair DD, Warnes CA, Oliver WC Jr. Operative treatment of Ebstein anomaly. *J Thorac Cardiovasc Surg.* 1992; 104: 1195-1202.
5. Carpentier A, Chauvaud S, Mace L, Relland J, Mihaileanu S, Marino JP, et al. A new reconstructive operation for Ebstein anomaly of the tricuspid valve. *J Thorac Cardiovasc Surg.* 1988; 96: 92-101.
6. Quaegebeur JM, Sreenam N, Fraser AG, Bogers AJ, Stumper OF, Hess J, et al. Surgery for Ebstein anomaly: the clinical and echocardiographic evaluation of a new technique. *J Am Coll Cardiol.* 1991; 17: 722-8.
7. Giuliani ER, Fuster V, Brandenburg RO, Mair DD. Ebstein's anomaly: the clinical features and natural history of Ebstein's anomaly of the tricuspid valve. *Mayo Clin Proc* 1977; 54: 163-173.
8. Hansen JF, Leth A, Dorp S, Wennevold A. The prognosis in Ebstein's disease of the heart: long term follow up of 22 patients. *Acta Med Scand* 1977; 201: 331-335.
9. Gentles TL, Calder AL, Clarkson PM, Neutze JM. Predictors of long term survival with Ebstein's anomaly of the tricuspid valve. *Am J Cardiol* 1992; 69: 377-381.
10. Watson H. Natural history of Ebstein's anomaly of the tricuspid valve in childhood and adolescence: An international cooperative study of 505 cases. *Br Heart J* 1974; 36: 417-427.
11. Mathews JL, Pennington WS, Isobe JH, Gaskin TA, Dumas JH, Kahn DR: Paradoxical embolization with Ebstein's anomaly. *Arch Surg* 1983; 118: 1101.
12. Barber G, Danielson GK, Heise CT, Driscoll DJ. Cardiorespiratory response to exercise in Ebstein's anomaly. *Am J Cardiol* 1985; 56: 509-514.
13. Wu Q and Huang Z. Anatomic correction of Ebstein anomaly. *J Thorac Cardiovasc Surg.* 2001; 122: 1237-8.