

## Ventricular Septal Rupture Following Blunt Chest Trauma

Ronaldo Peixoto de Mello, Maria Virginia Santana, Maria Aparecida de Paula Silva, César Esteves, Carlos Pedra, Anneliese Thom, Paulo Chacur, Marly Akiko Miara, Pedro Beraldo Andrade, Alejandra Borges Rodrigues  
Instituto Dante Pazzanese de Cardiologia - São Paulo, SP, Brazil

We report a case of ventricular septal rupture following chest trauma resulting from a car accident. The outcome was relatively favorable despite the extension of the anatomic lesion.

Cardiac contusion is the most common form of nonpenetrating cardiac trauma and is responsible for the ventricular septal rupture (VSR) resulting from this condition. It was first described by Hewett in 1847<sup>1</sup>. However, nonpenetrating chest trauma is a rare cause of VSR with a usually non-fatal progression and is associated with high-energy impacts. Early diagnosis is infrequent because the condition is disregarded<sup>2</sup>.

### Case Report

#### Medical history

Male, 18 years old, 75 Kg, with no relevant past history, reports recent car accident (40 days prior to hospital admission) followed by head trauma and blunt chest trauma. He was seen in an emergency service where he progressed with prolonged loss of consciousness and multiple pulmonary contusions which did not require intervention and was discharged after a short period of observation. At that time, he reported no cardiovascular complaints. In the recovery period, 10 days after the event, he reported the sudden and progressive onset of dyspnea on moderate exertion associated with an intense chest vibration following the heart rhythm. He sought medical care and was diagnosed with a heart murmur and was soon referred to this service. In the first visit he presented with dyspnea after a 100-m walk and had a severe difficulty to walk on inclined surfaces. This would force him to stop several times along the way, and he showed a markedly incapacity for functional performance. However, he could easily stand the supine position. At that time he denied palpitations, chest pain, dizziness or dyspnea on mild exertion. He reported a regular consumption of marijuana and alcoholic beverages, and denied use of inject drugs.

#### Physical examination

Blood pressure 120/70mmHg in the arms, pulse 80bpm,

#### Key words

Ventricular septal rupture, post-traumatic ventricular septal defect.

good general conditions, good color, well hydrated, no cyanosis or clubbing. Pulmonary examination showing normal vesicular breath sounds with no adventitious sounds. Cardiovascular examination revealed hyperkinetic apical impulse, a grade 2/4 palpable thrill in the left lower sternal border, and a grade 4/6 holosystolic, decrescendo heart murmur in the left sternal border radiating to the right. Normal S2 with physiologic splitting. Abdominal examination showed no liver enlargement, normal bowel sounds, no tenderness or guarding. Pulses were palpable, symmetric and normal.

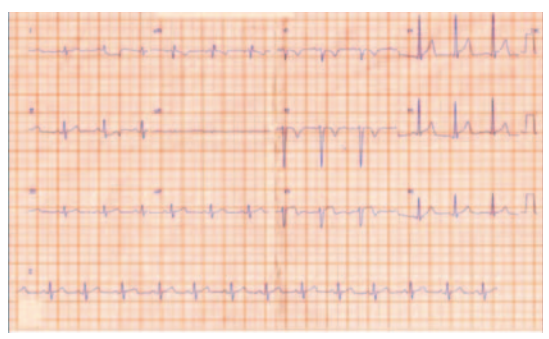#### Laboratory tests

The electrocardiogram, chest radiograph, echocardiogram, and schematic drawing are shown in Figures 1 to 4. By the time the diagnosis was made, the two-dimension echocardiogram showed a large muscular trabecular VSR extending to the infundibular region, EF = 0.74, left ventricular systolic diameter (LVSD) of 39mm and left ventricular diastolic diameter (LVDD) of 70mm. Left and right cardiac catheterization confirmed the suspected diagnosis of VSR showing a large left-to-right shunt. Pressure measurements (Tab. 1) revealed a significantly increased pulmonary blood flow with no associated pulmonary hypertension (Rp/Rs ratio = 0.05 and Qp/Qs = 4:1).

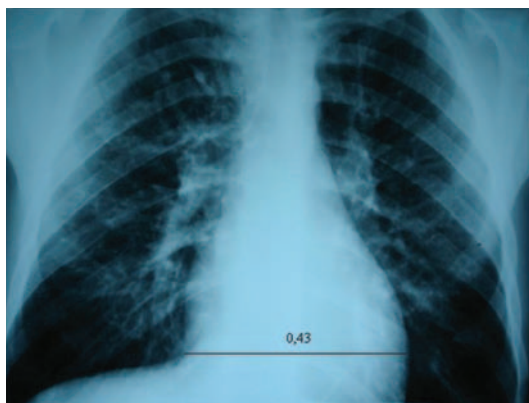The ventricular septal rupture was corrected via median sternotomy with myocardial protection and perfusion using crystalloid cardioplegia. Cardiomegaly resulting from right atrium, right ventricle and pulmonary trunk enlargement, and an approximately 3-cm VSR located below the moderator band in the mid-septal region were identified. A ventriculoseptoplasty was performed with bovine pericardial patch using 15 2-0 Ethibond sutures (U stitches) anchored with Teflon. In the immediate postoperative period the patient presented surgical bleeding requiring surgical intervention for hemostasis. He has been followed on a regular outpatient basis, asymptomatic and in functional class I. Control two-dimension echocardiogram in the third postoperative month revealed an EF of 0.72 and a significant decrease in the left ventricular chamber to a LVDD of 55mm, in addition to a residual 3-mm VSR in the mid-septal muscular region. Control chest radiograph showed no increased pulmonary blood flow.

#### Discussion

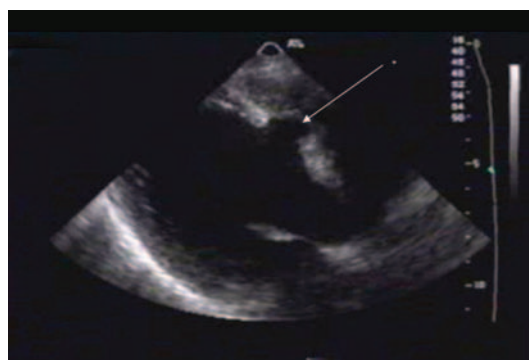## Case Report



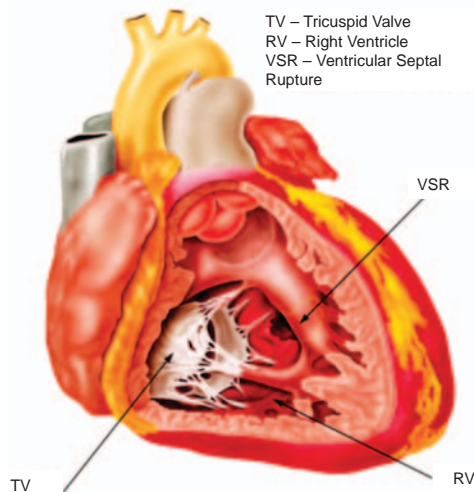
**Fig. 1** - Resting electrocardiogram showing sinus rhythm, axis at 60 degrees, no overload, no progression of R-wave, and permanent T-wave inversion in V1 to V3.



**Fig. 2** - Chest radiograph showing situs solitus, cardiac silhouette with normal diameters (Danzer's ratio of 0.43), grade 4/4 increased pulmonary blood flow, and flat pulmonary trunk.



**Fig. 3** - Doppler echocardiogram showing viscerocardiac situs solitus with levocardia and levoposition of the apex, presence of patent oval foramen with left-to-right shunt and large 30-mm muscular trabecular ventricular septal defect (\*) extending to the infundibular region, with left-to-right shunt. Moderated increase of the left ventricle with preserved systolic function.



**Fig. 4** - An approximately 3-cm VSR located below the moderator band in the mid-septal region.

	Pressures (mmHg)	O2 Saturation
Superior vena cava		69
Right atrium (mean)	8	75
Right ventricle	60/8 (25)	90
Pulmonary artery	45/13 (26)	92
Left ventricle	110/15 (46)	99
Aorta	90/50 (63)	97

**Table 1** - Cardiac catheterization data

Cardiac contusion culminating with VSR may be the consequence of several factors resulting from the interaction between forces that act on the cardiac tissue at the moment of the impact. Parmley classified the causes of cardiac injury in seven categories: (a) direct action forces, (b) indirect action forces, (c) bidirectional or compressive forces, (d) deceleration, (e) explosive forces, (f) concussion, and (g) combination of the previous, acting directly over the thorax or back as a consequence of a sudden change in the linear movement due to a deceleration or sudden change in movement<sup>2,3</sup>.

The compression exerted by the rib cage on the heart, more specifically between the sternum and the thoracic column with a resulting sudden increase in the intracardiac pressure during late diastole or isovolumetric systole, when the heart chambers are full and the valves are closed, makes an immediate relief of the inner pressure impossible, and thus resulting the major event in the genesis of tissue contusion and rupture. However, coronary lesion secondary to contusion is another possible mechanism and could account for the cases with late clinical presentation, as a consequence of infarction, local necrosis and further muscle rupture<sup>3-5</sup>.

The real incidence of VSR following chest trauma, as well as the participation of the etiologic agents in particular, remains unknown in the literature. However, in addition to blunt

trauma, penetrating lesions, acute coronary lesions, bacterial endocarditis and iatrogenic endocarditis due to diagnostic or therapeutic procedures have been described as acquired forms of VSR. Previous publications analyzing autopsies of 207548 cases of death secondary to car accidents identified VSR in 30 (0.01%) of the cases, and in only 0.002% the defects were isolated. In this series, rupture of the free ventricular wall was the most common form of presentation<sup>1,6</sup>. On the other hand, the incidence in clinical series has ranged from 10% to 75% in the presence of severe chest trauma<sup>2</sup>. The presence of myocardial contusion has been estimated at 15% of fatal chest trauma victims assessed in autopsy series<sup>7</sup>. In Brazil, in 2002, for example, there were 33288 deaths by car accidents according to data from DATASUS<sup>8</sup>. Of these, 22928 deaths occurred among individuals between 15 and 49 years of age. In the State of Sao Paulo alone 1046 deaths occurred among individuals from 15 to 24 years of age in 2000. Many of these individuals died secondarily to multiple trauma including head and/or chest trauma. Despite the lack of reliable data on the incidence of cardiac complications related to blunt chest trauma, these numbers can offer conditions to assess the magnitude of the problem, especially if we take into account that in Parmley's review cardiac rupture was the most common form of injury, accounting for 64% of the cases<sup>2,6</sup>.

In the present case, several elements corroborate the diagnosis of a traumatic etiology for the septal defect: (a) past medical history negative for cardiac symptoms, recalling the nature of the patient's professional activity; (b) no signs of ventricular overload in the electrocardiogram; (c) chest radiograph showing a normal cardiac silhouette, incompatible with the extension of the VSR found in the echocardiogram. When Campbell studied the natural history of the congenital defect, he demonstrated that 27% of individuals with large defects die of ventricular dysfunction and secondary pulmonary hypertension before 20 years of age, and 53% before 40 years of age, if not properly treated<sup>9</sup>. These data suggest that the likelihood of this patient to have progressed until adolescence without being diagnosed or to have had a fatal progression due to heart failure is very remote.

To facilitate the diagnosis, a high index of clinical suspicion is necessary, aiming primarily at preventing the potential lethal consequences of the ventricular rupture. Several methods such as ECG, enzyme markers, myocardial perfusion scintigraphy and echocardiography (whether conventional or transesophageal) are currently available.

The clinical presentation may be acute, subacute or late, depending on the extension of the injury and subsequent local necrosis<sup>2</sup>. In Rotman's review, cardiac murmur was detected in the initial presentation in few cases, and in the majority it became apparent between four and 12 days, whereas the occurrence of more than one point of rupture was an uncommon presentation. Symptoms are very wide ranging. There may be asymptomatic cases, atypical chest pain, anginal pain, dyspnea or palpitation, or more severe presentations with progressive heart failure, cardiogenic shock and death. The clinical presentation rapidly progressing to dyspnea on moderate exertion (FC II) without progressing to dyspnea in the supine position or overt heart failure despite the large septal defect is worth noting in the present case. When Rotman et al<sup>3</sup> analyzed this issue, they advised that the range of symptoms may not necessarily be oriented to the cardiovascular system, and the impairment of other organs affected may be more prominent with a consequent occurrence of cardiovascular symptoms when resuming daily

activities in the recovery period. In this case, when reviewing 38 cases of traumatic VSR, we found eight asymptomatic individuals and 24 individuals with symptoms compatible with heart failure, dyspnea or palpitations. Anginal chest pain, rapidly progressive heart failure, cardiogenic shock, and death were less common presentations.

The clinical signs detected in the physical examination are similar to those in the congenital defect. Chest radiograph usually shows cardiomegaly, increased pulmonary blood flow and/or pulmonary congestion proportional to the degree of the defect<sup>3</sup>.

Electrographic alterations are unspecific for contusion and include ST segment and T wave abnormalities. Ventricular and atrial arrhythmias may be present, and atrioventricular block is hardly ever reported<sup>3</sup>. Despite being useful in the initial assessment, they have a low sensitivity and specificity, and are especially masked by unspecific and/or previous alterations. In a series of 50 patients, serial plasma determinations of CPK/CKMB were not normal in 20% of the patients studied, detecting only 50% of the cases of cardiac injury, further diagnosed by transthoracic echocardiogram. In this series, the ratio CPK/CKMB had a sensitivity and specificity of 10% and 77.5%, respectively<sup>10</sup>.

Transthoracic echocardiogram is a useful method and may identify a segmentary motion deficit and chamber dilation, in addition to assessing the extension of the lesion and myocardial width. It can provide important information on the right and left ventricular function and rule out potential complications such as hematomas and tamponade. However, on account of several influences, technical difficulties may be present in approximately 20% of the cases<sup>3</sup>, in addition to being of limited value in the assessment of the right ventricular motion, as well as in the study of the right ventricular outflow tract. Weiss studied 22 patients with myocardial contusion diagnosed by transesophageal echocardiogram and verified that only 27% of the patients had a highly suggestive ECG; he recommends the routine use of this method for all patients under clinical suspicion. In his study, the presence of signs compatible with myocardial contusion was associated with a significant mortality. Transesophageal echocardiogram has the advantage of being a minimally invasive procedure, assessing motion abnormalities locally, and both left and right ventricular function<sup>10</sup>. Therapeutic decision regarding surgical treatment follows the same parameters used in congenital defects.

---

### References

1. Rutherford EJ, White KS, Maxwell JG, Clancy TV. Immediate isolated interventricular septal defect from nonpenetrating thoracic trauma. *Am Surg*. 1993; 59: 353-4.
2. Stahl RD, Liu JC, Walsh JF. Blunt cardiac trauma: atrioventricular valve disruption and ventricular septal defect. *Ann Thorac Surg*. 1997; 64:1466-8.
3. Rotman M, Peter RH, Sealy WC, Morris JJ Jr. Traumatic ventricular septal defect secondary to nonpenetrating chest trauma. *Am J Med*. 1970; 48: 127-31.
4. Aris A, Delgado LJ, Montiel J, Subirana MT. Multiple intracardiac lesions after blunt chest trauma. *Ann Thorac Surg*. 2000; 70: 1692-4.
5. Stajer D, Kariz S. Ventricular septal rupture following blunt chest trauma after a long delay: a case report. *Int J Cardiol*. 1994; 47: 187-8.
6. Parmley LF, Manion WC, Mattingly TW. Nonpenetrating traumatic injury of the heart. *Circulation*. 1958; 18: 371-96.
7. Ministério da Saúde [homepage na Internet]. Secretaria Executiva. Datasus [citado 2005 maio 6]. Disponível em: <http://www.datasus.gov.br>.
8. Campbell M. Natural history of ventricular septal defect. *Br Heart J*. 1971; 33: 246-57.
9. Lidenbaum GA, Carroll SF, Block EF, Kapusnick RA. Value of creatine phosphokinase isoenzyme determinations in the diagnosis of myocardial contusion. *Ann Emerg Med*. 1988; 17: 885-9.
10. Weiss RL, Brier JA, O'Connor W, Ross S, Brathwaite CM. The usefulness of transesophageal echocardiography in diagnosing cardiac contusions. *Chest*. 1996; 109: 73-7.