

## Angiographic Evaluation of Plaque Volume and Cardiovascular Events after Coronary Stent Implantation

Erlon Oliveira de Abreu-Silva, Alexandre Schaan de Quadros, Marco Tulio Zanettini, Carlos Antonio Gottschall

Instituto de Cardiologia do Rio Grande do Sul/Fundação Universitária de Cardiologia, Porto Alegre, RS - Brazil

### Abstract

**Background:** Plaque volume (PV) is related to major cardiovascular events (MACE) after coronary stent implantation.

**Objective:** To evaluate the association between PV before the procedure evaluated by angiography and clinical outcomes.

**Methods:** This is a prospective cohort study of patients undergoing coronary stent implantation in a referral center. PV before the stent implantation was evaluated by the formula described by Giugliano (Am J Cardiol 2005, 95:173):  $VP = \pi \times X \text{ (lesion length)} \times [(\text{vessel diameter}/2)^2 - (\text{minimum luminal diameter}/2)^2]$ . The MACE were registered at clinical follow-up of one year and multiple linear regression analysis was performed to identify predictors of events.

**Results:** The sample consisted of 824 patients, mean age  $60 \pm 11$  years, 70.0% were male. Diabetes mellitus was present in 21.0% and triple vessel involvement in 12.0%. Average reference diameter was  $3.3 \pm 3.2$  mm, average lesion length was  $10.2 \pm 4.7$  mm and mean residual stenosis was  $1.0\% \pm 12.0\%$ . Patients with MACE had higher PV than those without events ( $92.84 \pm 42.85$  vs  $85 \pm 46.85$ ,  $p = 0.03$ ). Other variables associated with MACE in the univariate analysis were triple vessel involvement, myocardial infarction, vessel diameter and length of the lesion treated. PV maintained a significant association with MACE after adjusting for the variables described and diabetes mellitus.

**Conclusion:** The volume of atheromatous plaque before stenting was higher in patients with MACE on clinical follow-up in one year, regardless of other predictors of events. (Arq Bras Cardiol 2010;95(6):679-684)

**Keywords:** Angioplasty, transluminal, percutaneous coronary/prognosis; coronary artery disease; stents; coronary angiography.

### Introduction

Percutaneous coronary interventions (PCI) are the primary method of myocardial revascularization in current clinical practice<sup>1</sup>. Aiming to estimate the risk and clinical outcome of these patients, various models of risk prediction and therapeutic success have been tested<sup>2-6</sup>. However, the prognostic evaluation of such patients is limited due to the low predictive accuracy of models and risk scores currently available<sup>3-6</sup>. This suggests the need to identify new clinical and angiographic characteristics associated with major cardiovascular events (MACE) in long-term clinical follow-up in patients undergoing PCI.

Studies evaluating the quantity, area, consistency and volume of coronary atherosclerotic plaque, both by angiography and by intravascular ultrasound (IVUS), have been performed<sup>7-13</sup> and reveal that the amount of plaque, both pre and post-PCI may play a prognostic value in disease

progression and outcomes<sup>14-18</sup>. Although the evaluation of atherosclerotic plaque by IVUS is one of the most sensitive methods for evaluation, this technology is costly, and is not available in several centers and cannot be used in subtotal lesions without predilatation with balloon<sup>19-21</sup>.

The assessment of plaque volume by an estimate based on angiography has been recently described<sup>22</sup>. However, the influence of atherosclerotic plaque volume assessed by angiography on clinical outcomes in patients undergoing coronary stent implantation has not been studied and is purpose of this study.

### Methods

#### Patients

A prospective cohort study in which patients undergoing PCI with coronary stents, from Apr/1997 to Dec/2001 in our institution were considered for inclusion. We excluded patients with cardiogenic shock, implantation of intra-aortic balloon or those with residual stenosis > 30.0% after stent implantation. Clinical, angiographic characteristics, data on procedures and in-hospital complications were prospectively recorded in the Access database.

Mailing address: Alexandre Schaan de Quadros •

Av. Princesa Isabel, 370 - Santana - 90620-000 - Porto Alegre, RS - Brazil

E-mail: editoracao-pc@cardiologia.org.br, alesq@terra.com.br

Manuscript received October 13, 2009; revised manuscript received June 23, 2010; accepted July 06, 2010.

The study was approved by the Institutional Ethics Board and participants signed a consent form.

### Clinical characteristics

Hypertension was considered present when the patient reported history or was taking antihypertensive drugs. Diabetes mellitus and dyslipidemia were defined as previous history or use of oral hypoglycemic agents or insulin, or statins, respectively. Family history was defined by the occurrence of AMI or sudden death by the father (< 45 years) or by the mother (< 55 years). Stable angina was defined as a stable pattern of onset of pain in the last two months before the procedure. Unstable angina was defined as worsening of the intensity and/or frequency of the pattern of angina in the last two months before the procedure, with or without chest pain at rest. Acute myocardial infarction (AMI) as an indication for stent implantation was defined as chest pain and ST-segment elevation requiring immediate revascularization of the infarct-related artery.

### Procedure for coronary stenting

The patients were receiving aspirin and thienopyridine upon the PCI. Intravenous bolus of unfractionated heparin were administered to achieve an ACT > 300 seconds, and intracoronary nitroglycerin was administered prior to angiography. The procedures for stent implantation were performed as described in literature<sup>23</sup>, and conventional stents were implanted in all cases.

The clinical success of the procedure was defined as coronary flow TIMI 3 and residual stenosis < 30.0% after stent implantation, without occurrence of death, myocardial infarction or emergency coronary artery bypass grafting. Acute myocardial infarction was defined as elevation of creatine kinase MB fraction (CK-MB) > 3 times the upper limit of normality or development of new pathological Q waves on electrocardiogram.

### Angiographic analysis

All analyzes were performed with angiographic quantitative coronary angiography (Siemens Axiom Artis, Munich, Germany). The diameter of the target vessel was defined as the average diameter of the segments proximal and distal to the lesion. The severity of stenosis was measured in two orthogonal projections. Longer lesions were considered as a single lesion only when a segment < 10 mm in length was between them. The stenoses were classified according to criteria established by the American College of Cardiology (ACC)<sup>24</sup>, and complex lesions were defined as those of type B2/C.

Artherosclerotic plaque volume was calculated by the formula proposed by Giugliano et al<sup>22</sup>:  $VP = \pi X (\text{lesion length}) X [(DRV/2)^2 - (MLD/2)^2]$ . We considered  $\pi = 3.14$ , DRV = reference vessel diameter in mm, MLD = minimal luminal diameter in mm.

### Follow-up and clinical outcomes

Patients were followed for one year by clinical evaluation in the office, contact with the responsible physician or phone interview. Angiographic control was performed for suspected

recurrent myocardial ischemia.

The primary outcome of this study was a combination of MACE including death related to cardiac causes, myocardial infarction (AMI), coronary artery bypass grafting (CABG) and percutaneous revascularization of the target vessel (TVR) within one year after the initial procedure of stent implantation.

### Statistical analysis

Categorical variables were expressed as percentages and continuous variables as the mean  $\pm$  standard deviation (SD). The differences between the two groups were evaluated by chi-square (categorical variables) and t test (continuous variables). Survival free of MACE during follow-up period of one year was analyzed and the difference between survival curves was evaluated by log-rank test.

Multivariate analysis by multiple linear regression was performed to identify predictors of MACE in one year. The variables included in the model were associated with MACE in the univariate analysis (plaque volume, lesion length, reference diameter, AMI, and triple vessel involvement) or with biological significance demonstrated in previous studies (diabetes mellitus, lesion length, reference diameter, AMI, and triple vessel involvement).

For all tests associations with  $p < 0.05$  were considered statistically significant.

### Results

In this study, 824 patients who underwent implantation of 891 stents met the inclusion criteria and were followed for one year post-PCI.

The clinical characteristics are presented in Table 1, observing that the individuals were predominantly middle-aged men who presented unstable angina. The clinical presentation of MI was more frequent in patients who had MACE, with no statistical significance in comparison with the other variables analyzed.

The angiographic evaluation showed that the average diameter of the vessel studied was  $3.3 \pm 0.32$  mm, the mean length of the lesion that suffered intervention was  $10.2 \pm 4.7$  mm, and the percentage of residual stenosis after stent implantation was  $1 \pm 12.0\%$  (Table 2). Those patients who had MACE had more often three-vessel involvement, thinner vessels and longer lesions.

The atherosclerotic plaque volume before the procedure was significantly higher in individuals who, one year after PCI, showed an outcome consisting of MACE compared to those without events ( $93 \pm 43 \times 85 \text{ mm}^3 \pm 46 \text{ mm}^3$ ,  $p = 0.03$ ). This result was irrespective of other variables analyzed in the multivariate analysis model (reference diameter, lesion length, triple vessel involvement, diabetes mellitus and myocardial infarction) (Table 3 and Figure 1).

### Discussion

Our results demonstrate that individuals who had major cardiovascular events (MACE) within one year after stent implantation, plaque volume had before the procedure

## Original Article

significantly greater than those individuals who showed no events in the same period. This result was maintained independent of other predictors of events after percutaneous coronary intervention, as demonstrated by multivariate analysis.

**Table 1 - Clinical characteristics of patients**

	All patients (n = 824)	MACE (n = 81)	No MACE (n = 743)	P
Male gender, %	70	80	70	0.07
Age (years)	60 ± 11	58.7 ± 11.5	60.3 ± 10.7	0.28
Hypertension, %	64	65	64	0.90
Diabetes mellitus, %	23	28	22	0.25
Dyslipidemia, %	46	42	46	0.48
Family history, %	36	37	36	0.72
Smoking, %	42	38	43	0.41
Previous history				
AMI, %	25	28	24	0.40
PCI, %	9	12	9	0.34
CABG, %	11	15	11	0.29
Ejection fraction, %	67 ± 13.1	64 ± 16.2	67 ± 12.6	0.12
Clinical presentation				
Stable angina, %	24	17	25	0.07
Unstable angina, %	62	62	62	0.98
AMI, %	14	18	10	0.04

MACE - major cardiovascular events, AMI - acute myocardial infarction, PCI - percutaneous coronary intervention, CABG - coronary artery bypass grafting.

**Table 2 - Angiographic characteristics of procedures**

	All patients (n = 891)	MACE (n = 82)	No MACE (n = 809)	p
Vessel treated				
Anterior descending, %	53	50	53	0,7
Circumflex, %	13	13	10	0,8
Right, %	28	31	28	0,8
Bypass surgery, %	5	8	5	0,7
Triple vessel involvement, %	12	21	11	0,03
Vessel diameter, mm	3.32 ± 0.32	3.21 ± 0.34	3.32 ± 0.41	0.01
Lesion length, mm	10.21 ± 4.7	12.06 ± 5.32	9.98 ± 4.52	< 0.001
Minimal luminal diameter, mm	0.53 ± 0.36	0.57 ± 0.42	0.53 ± 0.35	0.06
Deployment pressure, ATM	13.20 ± 2.56	13.27 ± 2.54	13.19 ± 2.57	0.77
Stenosis %				
Before implantation, %	84.10 ± 10.63	82.64 ± 12.45	84.28 ± 10.45	0.23
After implantation, %	1 ± 12	0.42 ± 8.37	0.70 ± 8.37	0.24

MACE - major cardiovascular events, ATA - atmospheres.

The intracoronary ultrasound is more accurate than angiography for assessment of atherosclerotic plaque volume<sup>13,19</sup>, but it is not available in all centers and adds costs to the procedures. Besides this, in subtotal stenosis it is not possible to introduce the ultrasound catheter without prior balloon dilatation, which prevents the accurate evaluation of more severe stenosis. To test the hypothesis of association between the plaque volume before the procedure and events in the follow-up period, the exclusion of more severe stenoses would represent a significant bias, since these are the cases in which a higher incidence of events would be expected.

The assessment of atherosclerotic plaque by angiography, as used in this study, was described by Giuliano et al<sup>22</sup> and does not have the limitations described above. The mathematical formula proposed estimates the plaque volume based on the reference diameter, minimal luminal diameter and lesion length. In our study, the plaque volume assessed by angiography presented an independent predictive value for

**Table 3 - Multivariate analysis**

	Odds ratio	Confidence interval 95%		P
		Inferior	Superior	
Plaque volume, mm <sup>3</sup>	1.04	1.02	1.07	0.03
Diabetes mellitus	1.45	.75	1.95	0.26
Lesion length	1.28	1.066	1.54	0.01
Reference diameter	1.36	.342	5.42	0.66
AMI	2.23	1.199	4.14	0.01
Triple vessel	2.15	1.186	3.90	0.01
Constant	.014			0.07

mm<sup>3</sup> - cubic millimeters, AMI - acute myocardial infarction.

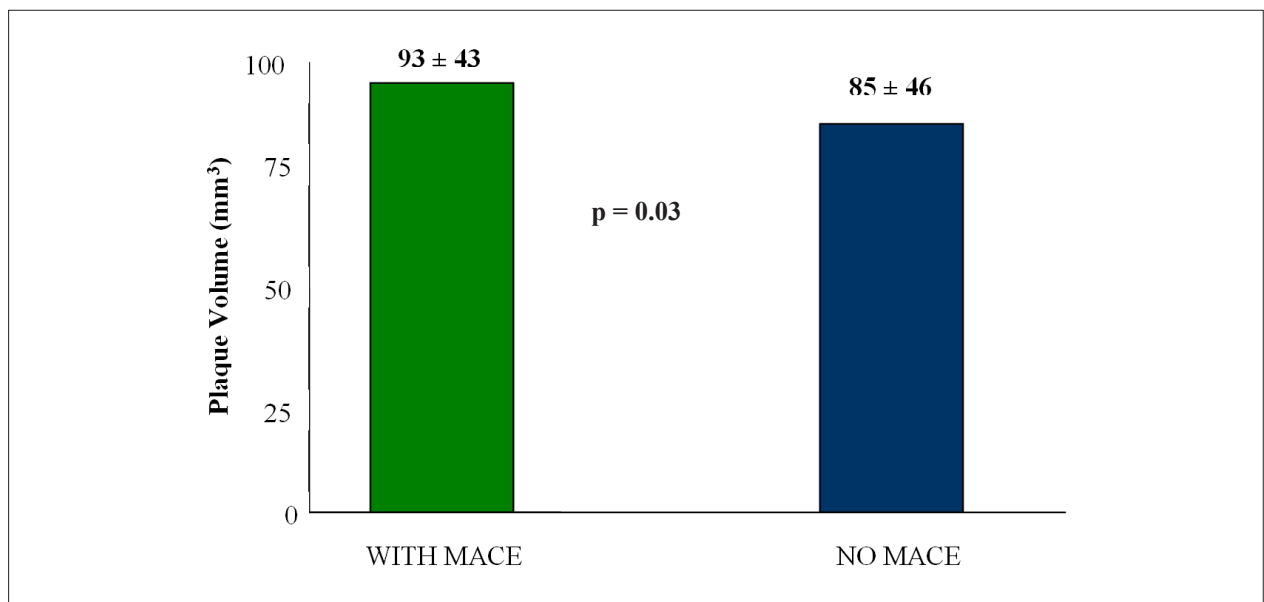


Figure 1 - Comparison of plaque volume in patients with and without major cardiovascular events (mean  $\pm$  SD).

cardiovascular events, and the risk adjusted by multivariate analysis was 1.04 (CI = 1.02 to 1.07).

Although an excess risk of 4.0% may be considered borderline, it is important to consider that the variable “plaque volume” was expressed in cubic millimeters, ranging from  $93 \pm 43 \text{ mm}^3$  and  $85 \pm 46 \text{ mm}^3$  in each group. Therefore, the 4.0% increase of risk refers to each cubic millimeter of plaque, which is much lower than the standard deviation of each group. If this variable had been used as increments of  $10 \text{ mm}^3$ , for example, we would have a 40.0% increase in risk.

In this trend, Prati et al<sup>18</sup> described the significant direct relationship between the plaque - assessed by angiography - and the same volume assessed by IVUS with the intensity of neointimal proliferation. Similar findings correlating the percentage area of residual plaque and restenosis have been described in the studies OARS<sup>25</sup>, ABACAS<sup>26</sup> and GUIDE II<sup>27</sup>. Berry et al<sup>13</sup> compared angiographic and ultrasound findings of 525 patients, revealing significant correlation in the measurement of plaque volume by both methods. The same study reported that individuals with angiographic evolution of the disease had greater plaque volume measurements by IVUS.

In our study, we did not explore the mechanisms responsible for the association between atherosclerotic plaque volume before the procedure and the incidence of clinical events. A possible explanation could be related to a higher content of atheroma and inflammatory cells in the arteries with bulkier atheroma. Restenosis and the need for new revascularizations of the target vessel are the main events after PCI, and the association between neointimal proliferation and inflammatory phenomena is well known<sup>28,29</sup>.

The clinical implications of the association between plaque volume before the procedure and the risk of cardiovascular events in patients undergoing PCIs with stent refer to the stratification of long-term risk in this clinical scenario, as discussed by many previous studies<sup>2-6,27,30-33</sup>. In most studies,

the predictors of new events were diabetes mellitus, reference vessel diameter and lesion length treated.

Our group developed and validated a score system for evaluation of events in which it was possible to identify subgroups of high and low risk for new revascularizations of target-vessel<sup>6</sup>. The angiographic assessment of plaque volume could be a new variable to be included in risk stratification algorithms, considering that the diagnostic accuracy of such models is relatively limited.

Another important aspect is that the plaque volume would also be predictive of events in patients undergoing implantation of drug-eluting stents, which have been used with increasing frequency in recent years. The capacity of these new devices in reducing intimal hyperplasia that occurs after vascular damage imposed by the stent or balloon, provided a significant reduction in the rates of restenosis and revascularization of target-vessel<sup>34,35</sup>, and the predictors of cardiovascular events in patients treated with drug-eluting stents are similar to those who received conventional stents<sup>36-38</sup>. However, to show an additional predictive value of the plaque volume to known predictors in patients treated with drug-eluting stents would require a much larger number of patients than the present study, since the incidence of events with drug-eluting stents is much smaller.

In conclusion, we demonstrated that the atherosclerotic plaque volume assessed before stenting by an angiographic method was associated with cardiovascular events in the long term. These results may be used for subsequent evaluations, to investigate whether the plaque volume may increase the diagnostic accuracy of risk stratification algorithms already established, and whether this association also occurs in patients treated with drug-eluting stents.

Limitations in study design should be considered and include lack of randomization, blinding, and long-term follow-up. Randomized trials comparing this technique for assessment of atherosclerotic plaque with the conventional

## Original Article

techniques currently available are becoming essential for the consolidation and validation of this method for diagnosis and prognosis of coronary artery disease.

### Potential Conflict of Interest

No potential conflict of interest relevant to this article was reported.

## References

1. Lloyd-Jones D, Adams R, Carnethon M, De Simone G, Ferguson TB, Flegal K, et al. Heart disease and Stroke Statistic-2009 update: a report from the American Heart Association Statistics Committee and Stroke Statistics Subcommittee. *Circulation*. 2009; 119 (3): e21-e181.
2. Gottschall CA, Miler VV, Yordi LM, Cardoso CR, Rodrigues LC. Detection of restenosis after percutaneous transluminal coronary angioplasty by an angiographic score. *J Invasive Cardiol*. 1998; 10 (1): 1-11.
3. de Feyter PJ, Kay P, Disco C, Serruys PW. Reference chart derived from post-stent-implantation intravascular ultrasound predictors of 6-month expected restenosis on quantitative coronary angiography. *Circulation*. 1999; 100 (17): 1777-83.
4. Ellis SG, Bajzer CT, Bhatt DL. Real-world bare metal stenting: identification of patients at low or very low risk of 9-month coronary revascularization. *Catheter Cardiovasc Interv*. 2004; 63 (2): 135-40.
5. Singh M, Gersh BJ, McClelland RL. Clinical and angiographic predictors of restenosis after percutaneous coronary intervention: insights from the prevention of restenosis with tranilast and its outcomes (PRESTO) trial. *Circulation*. 2004; 109 (22): 2727-31.
6. Quadros AS, Diemer F, Welter D, Modkovski T, Sarmento-Leite R, Gottschall CA. Validation of a risk score for target vessel revascularization after coronary stent implantation. *J Invasive Cardiol*. 2009; 21 (12): 618-22.
7. Frimerman A, Miller HI, Siegel RJ, Rosenschein U, Roth A, Keren G. Intravascular ultrasound imaging of myocardial-infarction-related arteries after percutaneous transluminal coronary angioplasty reveals significant plaque burden and compensatory enlargement. *Int J Cardiovasc Intervent*. 1999; 2 (2): 101-7.
8. Hartmann M, von Birgelen C, Mintz GS, Verhorst PM, Erbel R. Relation between baseline plaque burden and subsequent remodeling of atherosclerotic left main coronary arteries: a serial intravascular ultrasound study with long-term (> or = 12 months) follow-up. *Eur Heart J*. 2006; 27 (15): 1778-84.
9. Wong CB, Porter TR, Xie F, Deligonul U. Segmental analysis of coronary arteries with equivalent plaque burden by intravascular ultrasound in patients with and without angiographically significant coronary artery disease. *Am J Cardiol*. 1995 15; 76 (8): 598-601.
10. Honda Y, Yock PG, Fitzgerald PJ. Impact of residual plaque burden on clinical outcomes of coronary interventions. *Catheter Cardiovasc Interv*. 1999; 46 (3): 265-76.
11. Sahara M, Kirigaya H, Oikawa Y, Yajima J, Nagashima K, Hara H, et al. Soft plaque detected on intravascular ultrasound is the strongest predictor of in-stent restenosis: an intravascular ultrasound study. *Eur Heart J*. 2004; 25 (22): 2026-33.
12. Sabate M, Marijnissen JP, Carlier SG, Kay IP, van der Giessen WJ, Coen VL, et al. Residual plaque burden, delivered dose, and tissue composition predict 6-month outcome after balloon angioplasty and beta-radiation therapy. *Circulation*. 2000 30; 101 (21): 2472-7.
13. Berry C, L'Allier PL, Grégoire J, Lespérance J, Levesque S, Ibrahim R, et al. Comparison of intravascular ultrasound and quantitative coronary angiography for the assessment of coronary artery disease progression. *Circulation*. 2007; 115 (14): 1851-7.

### Sources of Funding

There were no external funding sources for this study.

### Study Association

This study is not associated with any post-graduation program.

14. Hong MK, Park SW, Lee CW, Kim YH, Song JM, Kang DH, et al. Relation between residual plaque burden after stenting and six-month angiographic restenosis. *Am J Cardiol*. 2002; 89 (4): 368-71.
15. Shiran A, Weissman NJ, Leiboff B, Kent KM, Pichard A, Satler LF, et al. Effect of preintervention plaque burden on subsequent intimal hyperplasia in stented coronary artery lesions. *Am J Cardiol*. 2000; 86 (12): 1318-21.
16. Alfonso F, García P, Pimentel G, Hernández R, Sabaté M, Escaned J, et al. Intravascular ultrasound study. Predictors and implications of residual plaque burden after coronary stenting: an intravascular ultrasound study. *Am Heart J*. 2003; 145 (2): 254-61.
17. Hong YJ, Mintz GS, Kim SW, Okabe T, Lu L, Bui AB, et al. Peri-stent reference segment plaque burden is associated with disease progression in saphenous vein grafts (a serial intravascular ultrasound assessment). *Am J Cardiol*. 2007; 100 (8): 1233-8.
18. Prati F, Di Mario C, Moussa I, Reimers B, Mallus MT, Parma A, et al. In-stent neointimal proliferation correlates with the amount of residual plaque burden outside the stent: an intravascular ultrasound study. *Circulation*. 1999; 99 (8): 1011-4.
19. Schoenhagen P, Nissen SE. Assessing coronary plaque burden and plaque vulnerability: atherosclerosis imaging with IVUS and emerging noninvasive modalities. *Am Heart Hosp J*. 2003; 2 (2): 164-9.
20. Tuzcu EM, Schoenhagen P. Atherosclerosis imaging: intravascular ultrasound. 2004; 64 (12): 1-7.
21. Nissen S. Coronary angiography and intravascular ultrasound. *Am J Cardiol*. 2001; 87 (4A): 15A-20A.
22. Giugliano GR, Kuntz RE, Popma JJ, Cutlip DE, Baim DS, on behalf of the Saphenous Vein Graft Angioplasty Free of Emboli Randomized (SAFER) Trial Investigators. Determinants of 30-day adverse events following saphenous vein graft intervention with and without a distal occlusion embolic protection device. *Am J Cardiol*. 2005; 95 (2): 173-7.
23. Mattos LA, Lemos Neto PA, Rassi A Jr, Marin-Neto JA, Sousa AGMR, Devito FS, et al. Sociedade Brasileira de Cardiologia. Diretrizes sobre intervenção coronária percutânea e métodos adjuntos diagnósticos em cardiologia intervencionista. *Arq Bras Cardiol*. 2008; 91 (6 supl.1): 1-58.
24. Smith Jr SC, Feldman TE, Hirshfeld JW. Percutaneous coronary intervention: ACC/AHA/SCAI 2005 Guideline. *J Am Coll Cardiol*. 2006; 47 (1): 121.
25. Simonton CA, Leon MB, Baim DS, Hinohara T, Kent KM, Bersin RM, et al. Optimal directional coronary atherectomy: final result of the Optimal Directional Atherectomy Study (OARS). *Circulation*. 1998; 97 (4): 332-9.
26. Hosokawa H, Suzuki T, Ueno K, Aizawa T, Fujita T, Takase S, et al. Clinical and angiographic follow-up of Adjunctive Balloon Angioplasty following Coronary Atherectomy Study (ABACAS). *Circulation*. 1996; 94: 1-318.
27. The GUIDE Trial Investigator. IVUS-determined predictors of restenosis in PTCA and DCA: final report from the GUIDE trial, phase II. (abstract) *J Am Coll Cardiol*. 1996; 29: 156A.
28. Quadros AS, Ribeiro JP, Manfroi WC, Leitão C, Ordovás K, Weiss L, et al. Níveis plasmáticos de marcadores imunoinflamatórios na aterosclerose coronariana primária e na reestenose coronariana pós-angioplastia. *Arq Bras Cardiol*. 2001; 76 (5): 379-89.

29. Libby P, Schwartz D, Brogi E, Tanaka H, Clinton SK. A cascade model for restenosis: a special case of atherosclerosis progression. *Circulation*. 1992; 86 (6 Suppl): 47-52.
30. Greenberg D, Bakhai A, Cohen DJ. Can we afford to eliminate restenosis? Can we afford not to? *J Am Coll Cardiol*. 2004; 43: 513-8.
31. Kastrati A, Schömig A, Elezi S, Schühlen H, Dirschinger J, Hadamitzky M, et al. Predictive factors of restenosis after coronary stent placement. *J Am Coll Cardiol*. 1997; 30 (6): 1428-36.
32. Bauters C, Hubert E, Prat A. Predictors of restenosis after coronary stent implantation. *J Am Coll Cardiol*. 1998; 31 (6): 1291-8.
33. Elezi S, Kastrati A, Neumann FJ, Hadamitzky M, Donchinger J, Schömig A. Vessel size and long-term outcome after coronary stent placement. *Circulation*. 1998; 98 (18): 1875-80.
34. Moses JW, Leon MB, Popma JJ, Fitzgerald PJ, Holmes DR, O'Shaughnessy C, et al.; (SIRIUS Investigators). Sirolimus-eluting stents versus standard stents in patients with stenosis in a native coronary artery. *N Engl J Med*. 2003; 349 (14): 1315-23.
35. Stone GW, Ellis SG, Cox DA, Hermiller J, O'Shaughnessy C, Mann JT, et al; (TAXUS-IV Investigators). A polymerbased, paclitaxel-eluting stent in patients with coronary artery disease. *N Engl J Med*. 2004; 350 (3): 221-31.
36. Elezi S, Dibra A, Mehilli J, Pache J, Wessely R, Schomig A, et al. Vessel size and outcome after coronary drug-eluting stent placement: results from a large cohort of patients treated with sirolimus- or paclitaxel-eluting stents. *J Am Coll Cardiol*. 2006; 48 (7): 1304-9.
37. Kastrati A, Dibra A, Mehilli J, Mayer S, Piniack S, Pache J, et al. Predictive factors of restenosis after coronary implantation of sirolimus- or paclitaxel-eluting stents. *Circulation*. 2006; 113 (19): 2293-300.
38. Rathore S, Terashima M, Katoh O, Matsuo H, Tanaka N, Kinoshita Y, et al. Predictors of angiographic restenosis after drug eluting stents in the coronary arteries: contemporary practice in real world patients. *EuroIntervention*. 2009; 5 (3): 349-54.