

Case 2 – For Index Purposes: A 50 Year Old and Past Heavy Drinker Man Admitted to Treat Decompensated Heart Failure

Wilma Noia Ribeiro, Alice Tatsuko Yamada, Luiz Alberto Benvenuti

Instituto do Coração (InCor) HC-FMUSP, São Paulo - SP, Brazil

Male patient with 50 years of age from Atibaia (SP), obese, was admitted for decompensated heart failure.

At 47 (April 2002), the patient was admitted with dyspnea on exertion and hypotension. He had had dyspnea on exertion for three years and progressed in the last three months before admission.

Physical examination on that date revealed weight of 130 kg; height 1.72 m; BMI = 43.9 kg/m², tachypnea 36 breaths per minute, heart rate 80 bpm, blood pressure 100 x 90 mmHg. There were crackles in both lung bases; heart sounds were arrhythmic and systolic murmurs ++/6+ in the mitral area; the abdomen was distended, visceromegalies were not palpated and there was edema ++++/4+ in the lower limbs. The patient was an ex-drinker (six beers/day for 20 years) and had hip osteoarthritis.

ECG showed atrial tachycardia with 2:1 atrioventricular block, low QRS voltage in frontal leads (Figure 1) and electrical cardioversion with 100 J was reverted to sinus rhythm with left atrial enlargement (Figure 2).

Laboratory tests (April 4 2002) revealed hemoglobin 15, g/dl, hematocrit 47%, leucocytes 9800/mm³ (79% neutrophils, 1% basophils, 13% lymphocytes, 7% monocytes), platelets 225000/mm³, glucose 111 mg/dL, gammaGT 12 U/L, AST 15 U/L, ALT 21 U/L, amylase 71 U/L, alkaline phosphatase 53 U/L, bilirubin 0.41 mg/dL (direct 0.09 mg/dL), urea 68 mg/dL, creatinine 1.5 mg/dL; PT-coagulation (INR) 1.42, APTT (rel times) 0.99; potassium 4.1 mEq/L, sodium 141 mEq/L; urine I: 1009 density, proteinuria 0.16 g/L, sediment: leukocytes 6000/mL, erythrocytes, 3000, hyaline casts 330/mL. Serology for Chagas disease was negative. TSH was 11.2 U/L, T4-free 1.3 microg/L, total cholesterol 240 mg/dL, HDL-C 48 mg/dL LDL-c 147 mg/dL and triglycerides 225 mg/dL.

Keywords:

Heart failure; obesity; cardiomyopathy; dilated; alcoholism; tachycardia; ectopic atrial.

Section Editor: Alfredo José Mansur (ajmansur@incor.usp.br)

Associate Editors: Desidério Favarato (dclfavarato@incor.usp.br)

Vera Demarchi Aiello (anpvera@incor.usp.br)

Mailing Address: Vera D. Aiello •

InCor – Av. Dr. Enéas de Carvalho Aguiar, 44. Postal Code 05403-000,

São Paulo, SP - Brazil

E-mail: anpvera@incor.usp.br

In subsequent days, creatinine decreased to 0.8 mg/dL and urea to 32 mg/dL.

Pulmonary perfusion scintigraphy (5 April 2002) revealed slight irregularities of distribution of tracer in the anterior and lateral basal segments of the right lower lobe and enlargement of the mediastinum and enlarged cardiac silhouette, and was considered not suggestive of pulmonary thromboembolism (Figure 3).

Echocardiography (April 8 2002) revealed aortic diameter of 40 mm, left atrium 50 mm, left ventricle 38 mm; septum thickness 10 mm (with asynchronous drive); posterior wall 9 mm; diastolic diameter of left ventricle 64 mm and marked decrease in left ventricular ejection fraction due to diffused hypokinesia. The right ventricle was dilated and hypokinetic and there was no valve abnormality.

Even after cardioversion, the patient remained hypotensive and required intravenous dobutamine.

The diagnoses were: cardiomyopathy with ventricular dilation (dilated alcoholic? cardiomyopathy), atrial tachycardia, morbid obesity, hypothyroidism and gout.

Cardiac decompensation was controlled and the patient was discharged on April 26 2002 with prescription of 150 mg captopril, 25 mg spironolactone, 40 mg furosemide, 0.25 mg digoxin and 25 micrograms of levothyroxine.

On July 24, 2002, radiocardiography and gated blood pool showed slight increase in right ventricle, with normal kinetics (EF = 43%); normal left ventricular volume and moderate hypokinesia of the septal wall (LVEF = 47%); bulging pulmonary trunk, and pulmonary transit time was 8 s.

Echocardiography (Jul 17 2002): septum and posterior wall thickness of 8 mm; aorta 41 mm, left atrium 44 mm, left ventricular systole/diastole 61/45 mm; ejection fraction 59%; right ventricle 36 mm, dilated and hypokinetic; enlarged right atrium; The left ventricle showed diffuse hypokinesia; right ventricular systolic pressure was 40 mmHg; there was change in left ventricular filling flow wave E<A; valves were normal.

In October of that year, there was recurrence of atrial flutter or atrial tachycardia and oral anticoagulation was initiated for subsequent cardioversion. The patient was asymptomatic at that time.

The patient presented with dyspnea on major exertion until he sought medical attention for dyspnea that had worsened on the previous day, on minimal exertion, without orthopnea, cough or fever.

Physical examination (March 14 2005, 11:00 p.m.) the patient was in good general condition, sleepy, irregular pulse

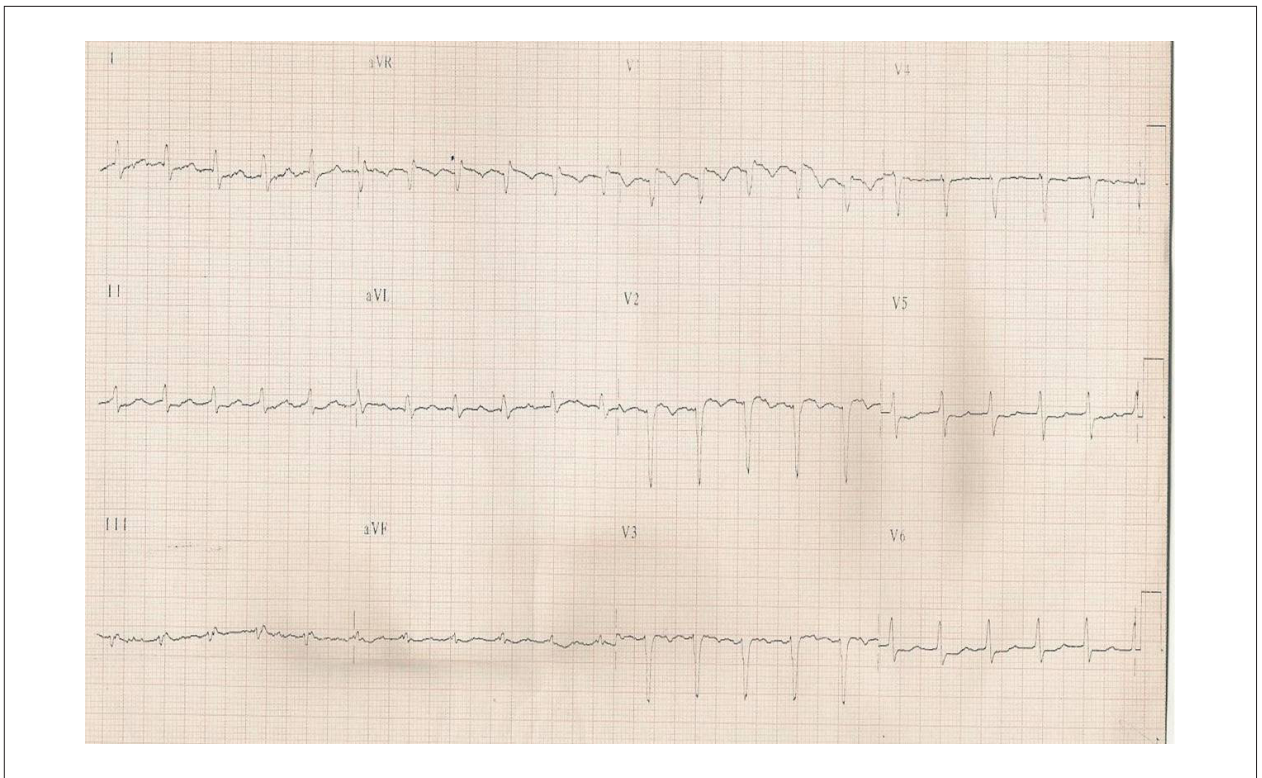


Figure 1 - ECG. Atrial tachycardia 2:1; low QRS voltage in frontal leads; intraventricular conduction disorder of the stimulus.

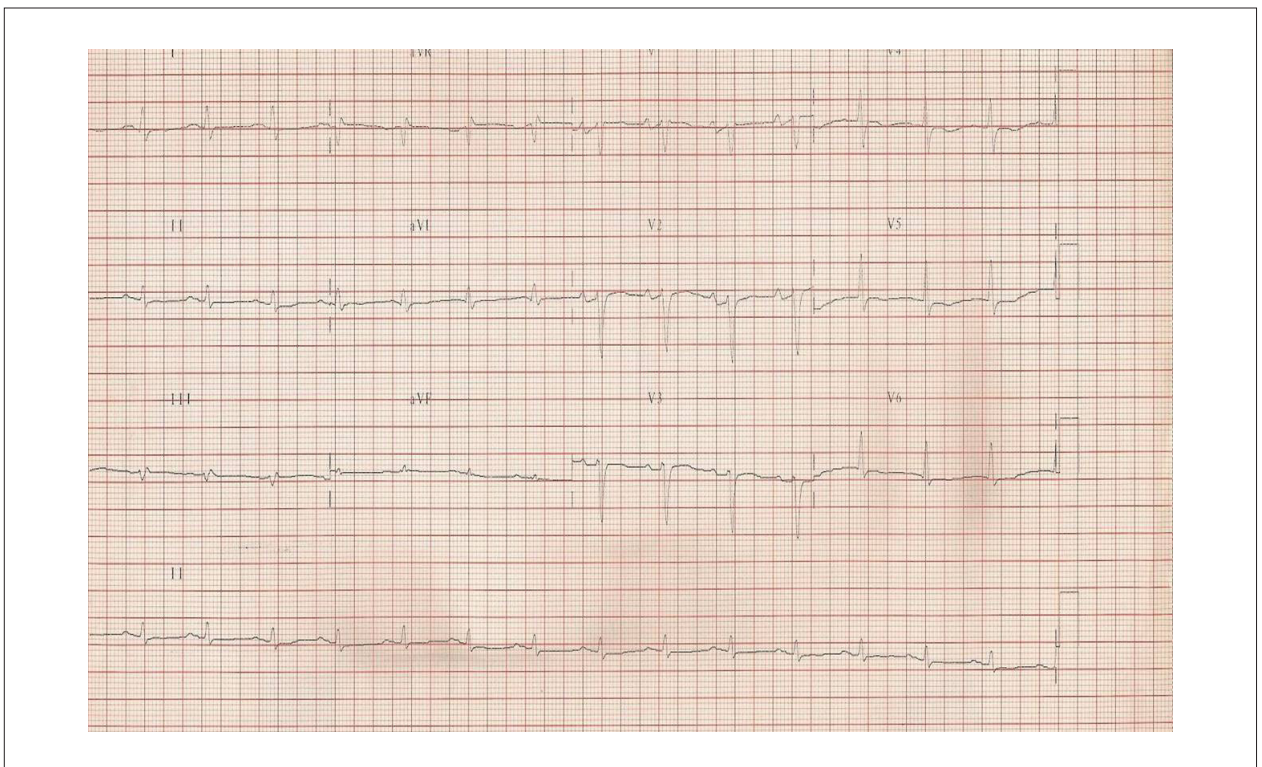


Figure 2 - ECG. Sinus rhythm, low QRS voltage in frontal leads; left atrial enlargement.

Anatomopathological Session

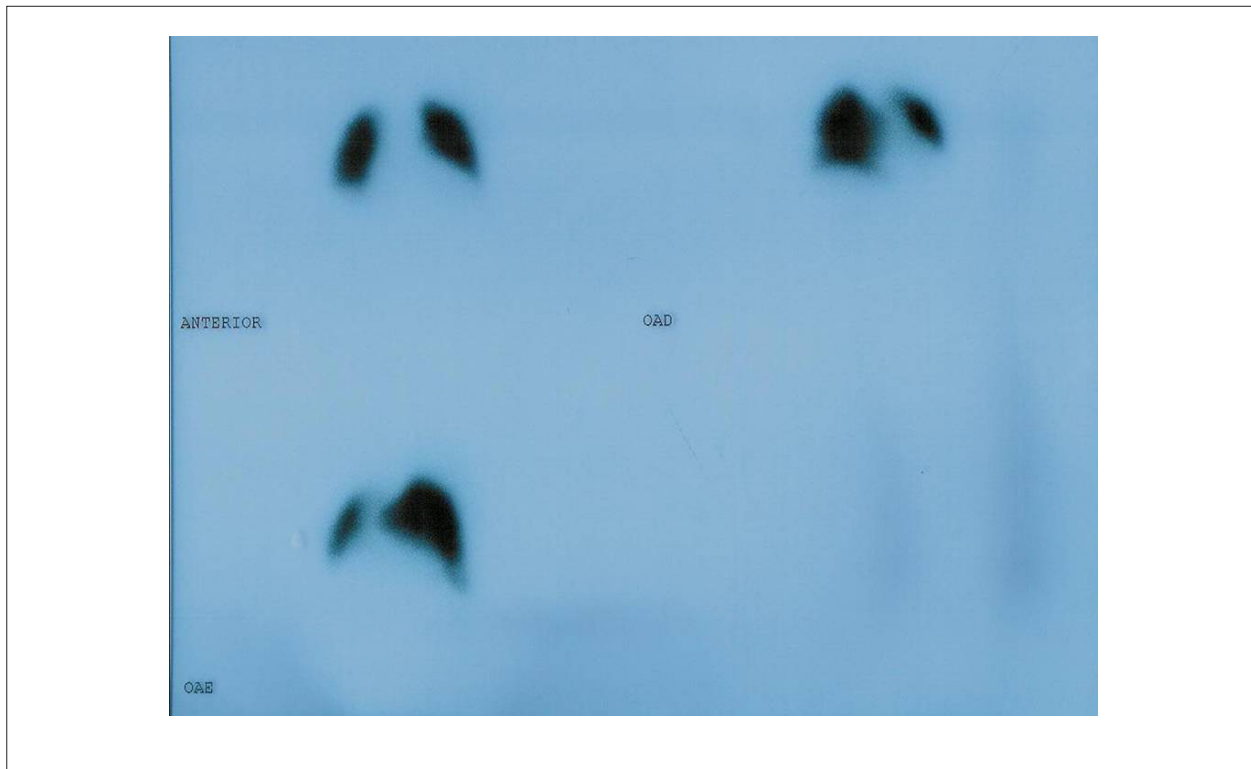

Figure 3 - Scintigraphy. Increased cardiac silhouette, slight abnormalities in the distribution of the tracer in the anterior and lateral basal segments of the right lower lobe. Abnormalities not suggestive of pulmonary thromboembolism; compatible with heart failure.

of 120 bpm, blood pressure 80 x 60 mmHg, respiratory rate 24 breaths per minute. Lung auscultation revealed diminished breath sounds and crackles at the bases of both lung fields; arrhythmic heart sounds were muffled and without the presence of murmurs or friction or 3rd or 4th heart sounds. The abdomen was distended, no masses or visceromegalies were palpated; lower limbs were swollen (+++/4+), with poor perfusion and stasis dermatitis.

Continuous mask ventilation was installed with positive pressure (CPAP), with intravenous administration of volume, dopamine and heparin.

ECG (March 15 2010) revealed constant atrial tachycardia, average heart rate of 134 bpm, low QRS voltage in frontal leads, no progression of left ventricular potential from V₁ to V₄ (Figure 4).

Echocardiography (March 15 2005) revealed aorta 35 mm, left atrium 55 mm, right ventricle systolic/diastolic diameter 64/57 mm, septal and upper wall thickness of 11 mm. Moderate increase in left ventricle and marked systolic dysfunction due to diffuse hypokinesia. The right ventricle was dilated and hypokinetic. Moderate mitral regurgitation and pulmonary artery systolic pressure was estimated at 35 mmHg.

Laboratory tests showed hemoglobin 13.1 g/dL, hematocrit 41%, leukocytes 8000/mm³ (neutrophils 80%, lymphocytes 8%, monocytes 10.7%), platelets 241000/mm³, urea 64 mg/dL, creatinine 0.7 mg/dL, sodium 136 mEq/L, potassium

4.6 mEq/L; urine EAS- leukocytes 15000/mL, erythrocytes 2000/mL. Arterial blood gas (CPAP) showed pH 7.36, paO₂ 116 mmHg, O₂ saturation 98%, paCO₂ 42 mm Hg, bicarbonate 23 mEq/L, base excess (-) 1.6 mEq/L; venous blood gas measurements revealed pH 7.32, pvO₂ 43 mmHg, O₂ saturation 67.7%, pvCO₂ 53 mmHg, bicarbonate 26 mEq/L and base excess (-) 0.3 mEq/L.

There was hemodynamic and respiratory improvement and electrical cardioversion was performed successfully with a shock of 100 J reversion to sinus rhythm (24 March 2005).

However, there was worsening of pulmonary ventilation with CO₂ retention and need for intubation (April 1 2005).

On April 1st, the patient developed fever and worsening of blood pressure, antibiotics were empirically introduced: vancomycin and ceftriaxone. New laboratory tests (April 3 showed hemoglobin 10.6 g/dL; hematocrit 33%; leukocytes 11300/mm³ (neutrophils 84%, eosinophils 3%; lymphocytes 6%; monocytes 7%) platelets 250000/mm³; potassium 3.8 mEq/L; sodium 138 mEq/L; urea 54 mg/dL; creatinine 2 mg/dL. The clinical picture remained unchanged and tracheostomy was performed (April 14, 2005).

Laboratory tests (April 16, 2005) revealed hemoglobin 6.8 g/dL, hematocrit 22%, leukocytes 9200/mm³ (neutrophils 93%; lymphocytes 3%; monocytes 4%), platelets 255000/mm³; creatinine 1.9 mg/dL, urea 99 mg/dL, potassium 3.5 mEq/L, sodium 138 mEq/L; PT (INR) 1.18; APTT rel 1.28; lactate 11 mg/dL.

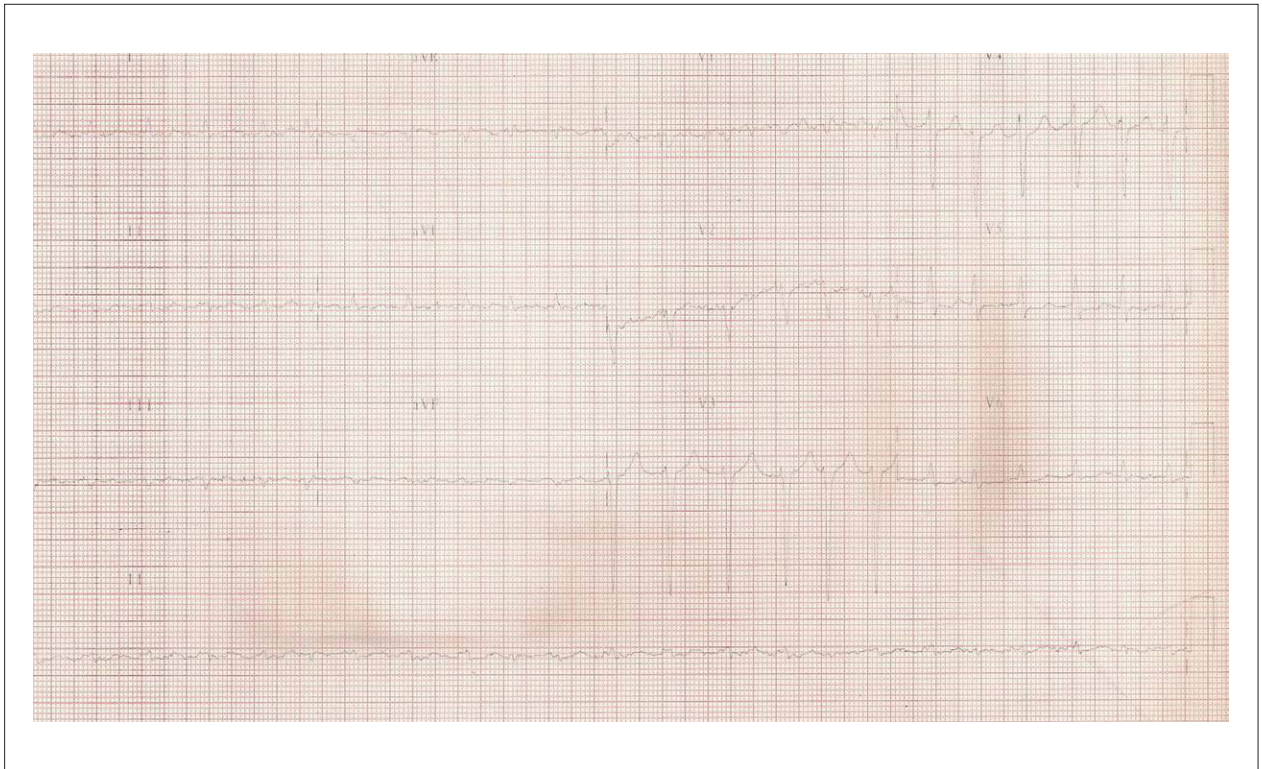


Figure 4 - ECG. Incessant atrial tachycardia; low QRS voltage in frontal leads, no progression of left ventricular potential from V_1 to V_4

Arterial blood gas revealed pH 7.19; pO_2 56 mmHg; pCO_2 55 mmHg; O_2 saturation 79.2%; bicarbonate 21 mEq/L and base excess (-) 6.6 mEq/L. Arterial blood gas revealed pH 7.21; pCO_2 40 mmHg, pCO_2 119 mmHg; O_2 saturation 97.8%; bicarbonate 15 mEq/L and base excess (-) 11 mEq/L.

Packed red blood cells were administered and upper digestive endoscopy was performed (April 22, 2005) which revealed moderate hemorrhagic erosive esophagitis and mild enanthematic pangastritis.

New tests (April 24, 2005) revealed hemoglobin 8.5 g/dl; hematocrit 27%; leucocytes $13200/mm^3$ (neutrophils 95%; lymphocytes 2%; monocytes 3%); platelet $157000/mm^3$; sodium 144 mEq/L; potassium 2.0 mEq/L; urea 41 mg/dl, creatinine 0,5 mg/dl, lactate 12 mg/dL, ionized calcium 0.97 nmol/L, magnesium 1.16 mEq/L; PT (INR) 1.23; APTT (rel) 2.17.

The patient continued with fever and hypotension and there was growth of yeasts in blood cultures (April 30).

The patient evolved with oliguria, tachypnea, recurrent fever, poor perfusion, diagnosis of mixed shock, suffering irreversible cardiac arrest in asystole on May 2, 2005.

Clinical aspects

This case presents a 50-year-old patient with signs and symptoms of heart failure syndrome associated with a history of excessive alcohol consumption. The primary diagnosis for the case is an alcoholic cardiomyopathy.

The origin of alcoholic cardiomyopathy is the leading cause of non-ischemic dilated cardiomyopathy in the Western world, accounting for 21% to 36% of all cases of dilated non-ischemic cardiomyopathy¹. It is estimated that two thirds of the adult population consume alcohol to some degree and more than 10% consume alcohol excessively².

Thus, no wonder that alcoholic cardiomyopathy is a big problem nowadays and people who consume > 90 g alcohol/day for more than five years are at risk for developing alcoholic cardiomyopathy³. Importantly, not only the quantity but also the type of beverage, genetic predisposition and the presence of comorbidities such as hypertension are factors associated with the triggering of this type of cardiomyopathy⁴.

The pathogenesis of alcoholic cardiomyopathy is not completely established. Studies have shown that acute alcohol intake is associated with depression in myocardial contractility and chronically to dysfunction in myocytes and activation of neurohumoral systems such as increase of catecholamines⁵.

Alcoholic cardiomyopathy is manifested by symptoms similar to other cardiomyopathies of other etiologies, such as dyspnea, orthopnea and paroxysmal nocturnal dyspnea. Palpitations and syncope due to tachyarrhythmia, especially supraventricular, may also be present. Chest pain is not common, unless there is concomitant coronary artery disease or aortic stenosis⁵.

Physical examination reveals convergent pulse pressure, often with high diastolic pressure by excessive peripheral vasoconstriction, as noted in the case above. The following

Anatomopathological Session

events are also common: Protodiastolic (B3) and presystolic (B4) galloping and apical systolic murmur of mitral regurgitation due to papillary muscle dysfunction. The degree of impairment of the right ventricle is variable⁵.

Biochemical and hematological laboratory tests often requested in patients under HF investigation serve both to assist in the diagnosis and to detect the presence of diseases or risk factors associated, such as: BNP, thyroid hormones, serology for Chagas disease, lipid determination. This patient also presented a case of hypothyroidism, which may have contributed to decompensation of heart failure. Acute renal failure presented by the patient on admission was probably secondary to ventricular dysfunction. It was later corrected with the compensation of heart failure.

The first electrocardiogram showed atrial tachycardia and an echocardiogram showed an enlarged left atrium, ventricle thickness and ventricular diastolic volume. These changes are frequent in alcoholic cardiomyopathy and corroborate the diagnosis⁶.

The treatment of alcoholic cardiomyopathy consists in alcohol withdrawal and pharmacotherapy recommended for treatment of heart failure. Individuals who stop drinking alcohol earlier in the course of the disease can have preserved cardiac function. Without complete abstinence, mortality of patients with alcoholic cardiomyopathy in four years is high, reaching 50%^{1,2}.

Among the differential diagnoses for this case, we have ischemic and Chagasic dilated cardiomyopathy, both prevailing in our country. Although this patient had a negative serology for Chagas' disease, the Latin American guideline published in 2011 recommends two negative serology tests for exclusion of this diagnosis⁷. As for ischemic etiology, the patient presented risk factors for coronary artery disease as high levels of total cholesterol and triglycerides, and impaired fasting glucose. However, the echocardiogram revealed ventricular dysfunction at the expense of ventricular dysfunction and diffuse hypokinesia without segmental changes, which makes this diagnosis less likely.

Despite normal blood pressure on initial physical examination, advanced hypertensive cardiomyopathy could also be remembered, already with significant ventricular dilatation and dysfunction. Finally, idiopathic dilated cardiomyopathy should be suggested for the case. It typically affects individuals aged between 18 and 50 and can occur in children and in the elderly. It is more common in men and blacks, and at least 25% of cases have genetic transmission of the disease. It is believed that genetic factors associated with changes in immune and infectious factors would act synergistically in the development of structural changes and subsequent development of clinical manifestations. It is estimated that 10%-20% of cases of idiopathic cardiomyopathy are caused by previous viral infection⁸.

In March 2005, the patient presented a new episode suggestive of decompensated heart failure with clinical signs of low cardiac output associated with pulmonary congestion. Clinical measures were initiated to compensate for heart failure including the use of inotropic agents, with initial clinical improvement. However, the patient evolved with

infection followed by persistent gastrointestinal bleeding and cardiac arrest in asystole on May 2, 2005. Laboratory tests showed acute renal failure and acidosis, probably secondary to systemic hypoperfusion.

There are many factors for worsening of heart failure chronically compensated. According to the history presented, one cannot infer a specific precipitating factor. Among the possible hypotheses, we have the natural progression of the disease itself and the reappearance of supraventricular tachycardia. What makes this diagnosis less likely is that, despite the reversal of tachyarrhythmia, the patient developed clinical worsening.

Other differential diagnoses for the final clinical picture are: cardiac tamponade, pulmonary thromboembolism or coronary ischemic event.

The presence of chronic renal failure and hypothyroidism, whose hormone levels were not measured in the last decompensation, are risk factors for the development of pericardial effusion, which makes the diagnosis of cardiac tamponade possible in this context. The clinical presentation of tamponade is due to ventricular diastolic filling restriction. Hypotension is usually present, although in earlier stages compensatory mechanisms allow maintaining normal blood pressure. Other frequent findings on physical examination are pulsus paradoxus, tachycardia and signs of right heart failure such as increased jugular venous pulse, hepatomegaly and Kussmaul sign. The abnormalities typically found on electrocardiogram are low voltage, as in this case, and electrical alternation of the QRS complex. What makes a low probability of this diagnosis is that the two echocardiograms performed during decompensation do not mention abnormalities in the pericardium.

Thromboembolism is a frequent complication in heart failure and its diagnosis in this context often becomes more difficult because of similarities in clinical presentation between the two diseases. A study conducted at Instituto do Coração evaluating the correlation between clinical and pathological diagnosis showed the largest discrepancies occurring in the diagnosis of pulmonary thromboembolism, which confirms the difficulty of detecting this condition⁹.

The clinical picture of thromboembolism consists of dyspnea and hypoxemia disproportionate to the finding of pulmonary congestion, and worsening of the signs of right ventricular failure. Laboratory tests have little value because of changes in biomarkers are also present in heart failure as the D-dimer and BNP. Imaging methods are required for diagnostic confirmation. In this case, the patient showed signs of left ventricular failure which could justify the picture of dyspnea, as well as right ventricular dysfunction, probably secondary to high filling pressures in the left chambers. Although the pulmonary artery pressure may be underestimated by the presence of severe right ventricular dysfunction, another finding that makes the diagnosis less likely is that the presence of pulmonary hypertension was not detected on echocardiography.

Despite the absence of typical ischemic electrocardiographic abnormalities, the hypothesis of myocardial ischemia should be considered because the patient had risk factors for coronary

artery disease. Besides the atherosclerotic ischemic event, an embolic source cannot be ruled out, as it is a complication also reported in patients with advanced dilated cardiomyopathy¹⁰.

(Dr. Wilma Noia Ribeiro, Dr. Alice Tatsuko Yamada)

Diagnostic hypotheses: syndromic diagnosis: congestive heart failure; etiology: alcoholic cardiomyopathy; final event: mixed shock (cardiogenic – septic).

(Dr. Wilma Noia Ribeiro, Dr. Alice Tatsuko Yamada).

Tachycardiomyopathy cannot be excluded as an etiology because the patient had atrial tachycardia in the first electrocardiographic evaluation and in the last hospitalization, incessant atrial tachycardia.

(Dr. Eduardo Argentino Sosa).

Necropsy

External examination of the corpse showed marked obesity, tracheotomy hole, stasis dermatitis of the lower limbs and anasarca. The heart weighed 942 g and had, by external examination, increased volume and globular shape, and prominence of subepicardial fat (Figure 5). There was dilatation and eccentric hypertrophy of four chambers, most notably in the right ventricle (Figure 6). The free wall of the left ventricle measured 1.5 cm in thickness and the right ventricle, 0.5 cm. Histological myocardial examination showed cardiomyocyte hypertrophy and mild interstitial fibrosis. Basophilic degeneration was present in rare cardiomyocytes. The epicardial coronary arteries as well as the aorta had no significant atherosclerotic lesions. The lungs together weighed 2,140 g, with chronic passive congestion with marked hemosiderosis and hypertrophy of parenchymal arterioles (Figure 7), septal capillary hemangiomatosis, diffuse alveolar damage in organization and foci of bronchopneumonia on the right, with formation of microabscesses. A histochemical study of bacteria and fungi was negative in the areas of bronchopneumonia. The thyroid volume had decreased, and weighed 16 g (normal values: 15 to 30g). On histological examination, the follicles presented a varied volume and there was marked fibrosis with no inflammatory infiltrate (Figure 8). Tracheostomy caused marginal damage in the isthmus of the thyroid, with a focal area of necrosis and secondary bacterial contamination by Gram-positive cocci. The liver showed chronic passive congestion and centrilobular hemorrhagic necrosis and spleen showed extensive areas of recent red pulp necrosis.

(Dr. Luiz Alberto Benvenuti)

Pathological diagnoses – Morbid obesity; dilated cardiomyopathy; pulmonary histopathologic abnormalities suggestive of hypoventilation syndrome/sleep apnea; thyroid atrophy (mild); bronchopneumonia on the right, with formation of microabscesses (cause of death).

(Dr. Luiz Alberto Benvenuti)

Comments

Interesting case of a 50-year-old man with morbid obesity, hypothyroidism and a history of chronic alcohol abuse in the past, who developed progressive cardiac dysfunction. The last admission had refractory heart failure, fever and progression to clinical shock and death. The autopsy revealed cardiomegaly with biventricular dilatation without valvular or coronary disease, confirming the diagnosis of dilated cardiomyopathy. The pulmonary histopathological abnormalities characterized by marked pulmonary hemosiderosis, intense wall hypertrophy of pulmonary arterioles and capillary hemangioma, as well as significant eccentric hypertrophy of the right ventricle of the heart, suggest the occurrence of hypoventilation syndrome/sleep apnea, which is known to be associated with obesity¹¹.

In this case, the etiology of dilated cardiomyopathy is debatable. The term “idiopathic” is not appropriate when used when there is no known factor that may have given rise to it. In addition to the history of alcoholism, which may cause dilated cardiomyopathy (the so-called alcoholic cardiomyopathy), the probable hypoventilation syndrome/sleep apnea, which can be accompanied by dilated cardiomyopathy¹¹, there is evidence that severe obesity, with no other coronary artery disease or hypertension may be related to the development of dilated cardiomyopathy and congestive heart failure^{12,13}. On the other hand, hypothyroidism whose morphological substrate was slight atrophy of parenchymal gland fibrosis may also be associated with the development of dilated cardiomyopathy^{14,15}. In the latter case, however, one must consider that the patient was taking hormone replacement, although we do not know if that was effectively normalizing the levels of thyroid hormones.

The severe respiratory failure that the patient developed secondary to heart failure and morbid obesity with limited ventilation was complicated by bronchopneumonia, which in practice was the cause of death. It is possible that this be related to secondary bacterial infection by Gram-positive cocci, edges of tracheotomy, which caused a small traumatic necrotic injury in the thyroid isthmus.

(Dr. Luiz Alberto Benvenuti)

Anatomopathological Session

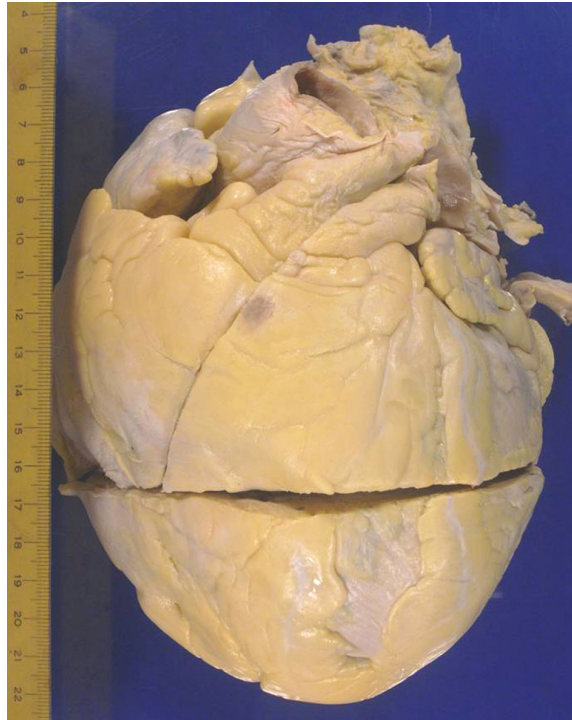


Figure 5 - External view of the heart showing increased volume and globular shape. Note also the prominence of subepicardial fat.

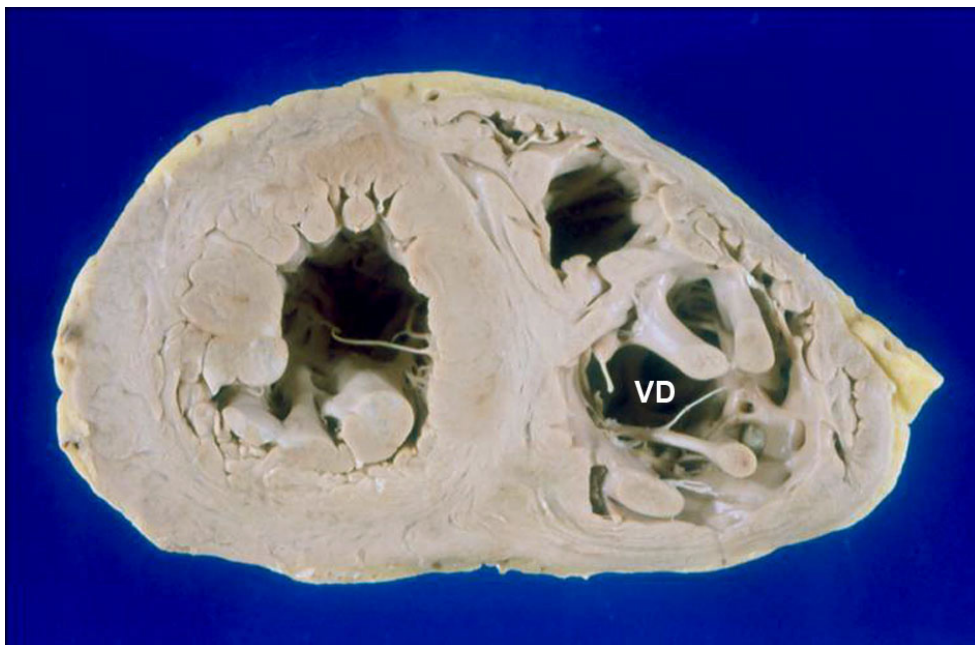


Figure 6 - Cross section showing ventricular hypertrophy and dilatation of both chambers, most prominent on the right (RV).

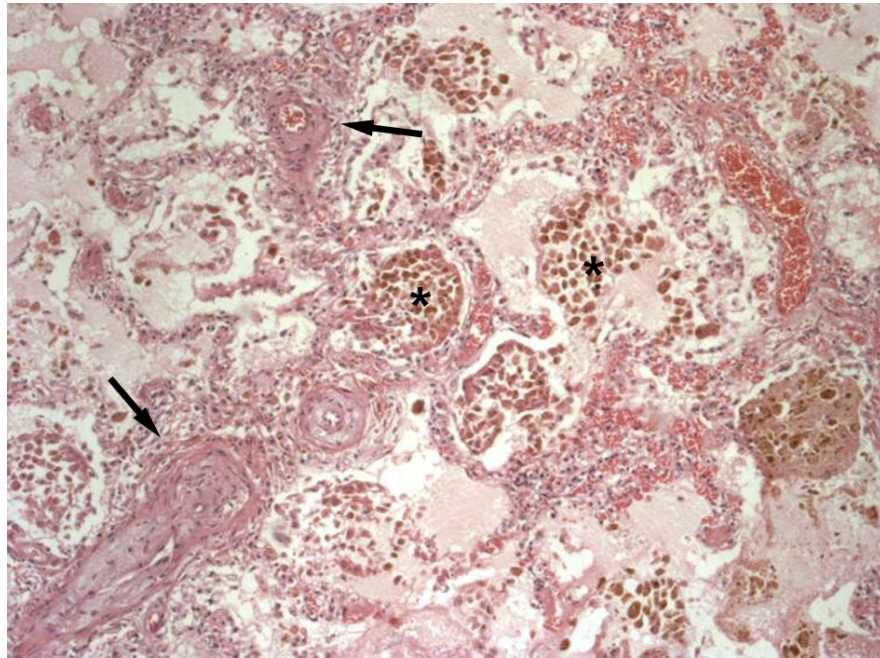


Figure 7 - Histological section of the lung showing clusters of histiocytes harboring hemosiderotic pigment (asterisks) and marked hypertrophy of the wall of arterioles with concentric intimal thickening (arrows). Hematoxylin-eosin, x50.

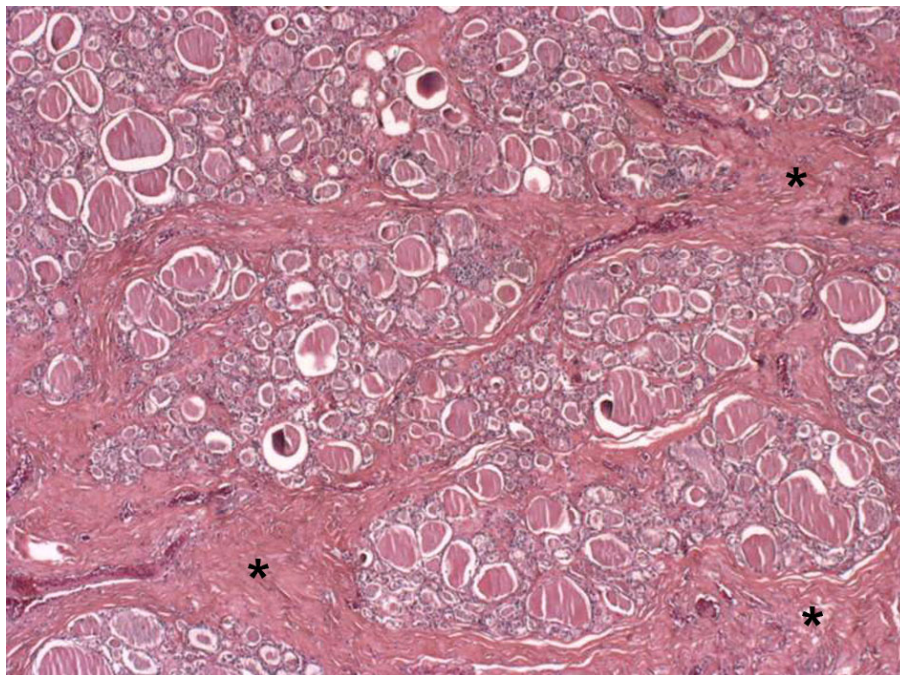


Figure 8 - Histological section of the thyroid showing great variation in the size of the follicles and strands of fibrous tissue (asterisks) and no inflammation. Hematoxylin-eosin, x25.

References

1. George A, Figueredo VM. Alcoholic cardiomyopathy: a review. *J Card Fail.* 2011;17(10):844-9.
2. Skotzko CE, Vrinceanu A, Krueger L, Freudenberger R. Alcohol use and congestive heart failure: incidence, importance, and approaches to improved history taking. *Heart Fail Rev.* 2009;14(1):51-5.
3. Lee WK, Regam TJ. Alcoholic cardiomyopathy: is it dose-dependent? *Congest Heart Fail.* 2002;8(6):303-6.
4. Djousse L, Gaziano JM. Alcohol consumption and heart failure: a systematic review. *Curr Atheroscler Rep.* 2008;10(2):117-20.
5. Piano MR. Alcoholic cardiomyopathy: incidence, clinical characteristics and pathophysiology. *Chest.* 2002;121(5):1638-50.
6. Matheus EC Jr, Gardin JM, Henry WL, Del Negro AA, Fletcher RD, Snow JA, et al. Echocardiographic abnormalities in chronic alcoholics with and without overt congestive heart failure. *Am J Cardiol.* 1981;47(3):570-8.
7. Andrade JA, Marin Neto JA, Paola AAV, Villas-Boas F, Oliveira GMM, Bacal F, et al. Sociedade Brasileira de Cardiologia. I Diretriz Latino Americana para o diagnóstico e tratamento da cardiopatia chagásica. *Arq Bras Cardiol.* 2011;97(2 supl. 3):1-48.
8. Babonian C, Treasure T. Meta-analysis of the association of enteroviruses with human heart disease. *Heart.* 1997;78(6):539-43.
9. Saad R, Yamada AT, Pereira da Rosa FH, Gutierrez PS, Mansur AJ. Comparison between clinical and autopsy diagnoses in a cardiology hospital. *Heart.* 2007;93(11):1414-9.
10. Canali G, Girardi P, Barbieri E. [Coronary embolus and acute myocardial infarction in a patient with dilated cardiomyopathy and chronic atrial fibrillation]. *G Ital Cardiol (Rome).* 2006;7(5):365-8.
11. Ahmed Q, Chung-Park M, Tomashefski JF Jr. Cardiopulmonary pathology in patients with sleep apnea/obesity hypoventilation syndrome. *Hum Pathol.* 1997;28(3):264-9.
12. Galinier M, Pathak A, Roncalli J, Massabuau P. Obesity and cardiac failure. *Arch Mal Coeur Vaiss.* 2005;98(1):39-45.
13. Kasper EK, Hruban RH, Baughman KL. Cardiomyopathy of obesity: a clinicopathologic evaluation of 43 obese patients with heart failure. *Am J Cardiol.* 1992;70(9):921-4.
14. Bezdah L, Slimène H, Kammoun M, Haddad A, Belhani A. [Hypothyroid dilated cardiomyopathy]. *Ann Cardiol Angeiol (Paris).* 2004;53(4):217-20.
15. Brito D, Pedro M, Bordalo A, Argando AL, Auiar A, Gouveia R, et al. Dilated cardiomyopathy due to endocrine dysfunction. *Rev Port Cardiol.* 2003;22(3):377-87.