

MYOELECTRIC ACTIVITY OF THE SMALL BOWEL OF DOGS SUBMITTED TO PARTIAL OCCLUSION OF THE PORTAL VEIN

Atividade mioelétrica do intestino delgado de cães submetidos à oclusão parcial da veia porta

Álvaro Antônio Bandeira **FERRAZ**, Josemberg Marins **CAMPOS**, Luis Fernando **EVANGELISTA**,
Antonio Roberto de Barros **COELHO**, José Guido de **ARAÚJO-FILHO**, Edmundo Machado **FERRAZ**

From Core Laboratory of Experimental Surgery, Hospital das Clínicas, Universidade Federal de Pernambuco, Recife, PE, Brazil.

ABSTRACT – Background - Temporary occlusion of the portal vein causes splanchnic venous stasis and intestinal dysfunction, that can produce alterations in the motility, and this fact is not vastly known. **Aim** - To evaluate the small bowel myoelectric activity and histology in the six dogs, also covering mean arterial blood pressure (AP), pulse rate (PR), central venous pressure (CVP) e portal pressure (PP), in two phases: pre-occlusion and occlusion. **Methods** - It was done general anesthesia, invasive monitorization of the AP, PR e CVP, laparotomy, measure of the PP, fixation of the three pairs of electrodes in the intestinal wall, jejunal biopsy and partial occlusion of the portal vein, being programmed the increase of the PP between 2.5 and 3 times baseline. Electrodes were connected to a computer system that captured electrical signals from the intestine. The computer has a software of acquisition to store and analyse the myoelectric activity after registering, what happened in 30 minutes of the pre-occlusion phase and in 60 minutes of occlusion. The variance and the mean RMS (root mean square) of the myoelectric activity were determined. The statistical analysis was done with Friedman, Dunn, Cochran and Students t tests. **Results** - Mean RMS of myoelectric activity showed significant decrease in the phase of portal occlusion, in comparison to pre-occlusion phase. The frequency of hemorrhage of the lamina propria was major during occlusion. It was proportional at stasis time, with significant difference between the pre-occlusion and the occlusion of 60 minutes. Inflammatory infiltration, vascular dilation and epithelial detachment did not show any differences between two phases. During the stasis, AP, PR and CVP decreased ($p=0,326$; $0,375$ e $0,008$, respectively), and PP increased ($p=0,015$). **Conclusions** - Partial occlusion of the portal vein produced reduction of the myoelectric activity and elevation of the percentage frequency of hemorrhage in lamina propria, and a fall of CVP, with relative hemodynamic stabilization.

HEADINGS – Portal vein. Intestine, small. Surgery. Hypertension, portal.

Correspondence:

Álvaro Antônio Bandeira Ferraz,
e-mail: aabf@truenet.com.br

Conflict of interest: none
Financial source: none

Submitted: 17/11/2010
Accepted for publication: 21/12/2010

DESCRIPTORES - Veia porta. Histologia. Intestino delgado. Cirurgia. Hipertensão portal.

RESUMO – Racional - A oclusão temporária da veia porta causa estase esplâncnica e pode causar dismotilidade intestinal. **Objetivo** - Avaliar as alterações da atividade mioelétrica e da histologia do intestino delgado, além da pressão arterial média (PAM), frequência cardíaca (FC), pressão venosa central (PVC) e pressão portal (PP), na fase de pré-occlusão e de oclusão portal. **Método** - Realizou-se anestesia geral em seis cães, seguido de monitorização da PAM, FC e PVC, laparotomia, aferição da PP, fixação de três pares de eletrodos na parede intestinal, biópsias jejunais e oclusão parcial da veia porta, sendo programado aumento da PP entre 2,5 e 3 vezes. Os eletrodos foram conectados a um microcomputador com software de aquisição para armazenamento e análise da atividade mioelétrica, cujo registro ocorreu nos 30 minutos da fase de pré-occlusão e nos 60 minutos de oclusão. Determinou-se a variância e a média do RMS (root mean square) da atividade mioelétrica. **Resultados** - Na fase de oclusão, houve diminuição significativa da média do RMS e aumento da frequência de hemorragia da lâmina própria, sendo proporcional ao tempo de estase. Infiltrado inflamatório, dilatação vascular e desprendimento epitelial não apresentaram diferença entre as duas fases. Durante a estase, PAM, FC e PVC diminuíram ($p=0,326$; $0,375$ e $0,008$; respectivamente), e PP aumentou ($p=0,015$). **Conclusões** - A oclusão parcial da veia porta de cães promoveu diminuição da atividade mioelétrica e aumento da frequência percentual da hemorragia da lâmina própria, além de queda da PVC.

INTRODUCTION

In recent years, there has been an increased number of large liver operations. Extensive hepatectomy and partial liver transplant determine elevation of portal flow resistance, due to the reduction

of intrahepatic vascular space¹⁰. This results in acute portal hypertension and splanchnic venous stasis, with subsequent disturbance of the function of the small intestine and may cause postoperative ileus, due to intestinal electrophysiological changes, which is not well known⁸⁻¹¹⁻¹².

Acute portal hypertension may also determine systemic hemodynamic disturbances such as decreased venous return and systemic arterial pressure - the situation can induce splanchnic hypoperfusion and resultant change in mucosal histology - and motility. In addition, Moriura et al.¹¹ showed a reduction in cardiac output and maintenance of left atrial pressure, suggesting no decrease in venous return. Thus, the mechanisms of hemodynamic changes after partial occlusion of the portal vein remain controversial.

Some peculiarities of the myoelectric activity of small intestine, secondary to portal stasis, are not well understood and, until now, no experimental study exists to observe the cardiovascular repercussions, which show associations with the myoelectric activity and morphology.

The determination of these aspects could contribute to a better understanding of functional disorders of the small intestine induced by acute portal hypertension.

Thus, the objective of this study is to evaluate the changes of the myoelectric activity of small intestine, through its RMS (root mean square) and histology, during pre-occlusion and occlusion of the portal. Was also measured the mean arterial pressure (MAP), heart rate (HR), central venous pressure (CVP) and portal pressure (PP).

METHOD

Six adult mongrel dogs underwent abdominal operation as an experimental model of acute portal hypertension. It was selected seven dogs without disease, five males and two females, weighing between 14 and 16.5 kg, with the exclusion of an animal due to the occurrence of abdominal lymph leakage and severe hypotension.

It is a controlled experimental study and divided into two phases, taking the partial occlusion of the portal vein as the parameter of division between the pre-occlusion and occlusion of the portal, which lasted 30 to 60 minutes. The time of portal occlusion was the divider between the control and experimental, which were present in each animal, at different stages throughout the experiment, which corresponded, respectively, the pre-occlusion and occlusion of the portal, so that each animal was its own control. The portal occlusion phase was subdivided into three steps every 20 minutes for taking jejunal biopsies and hemodynamic monitoring (Figure 1).

It was previously determined that occlusion of the

portal vein of dogs for 60 minutes, elevate PP to levels located between 2.5 and 3 times compared to baseline, measured before the occlusion site (Figure 2).

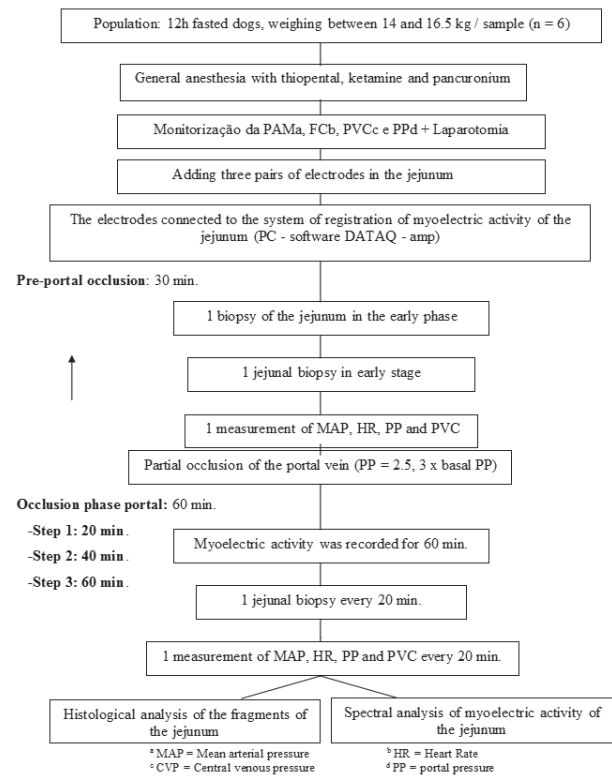


FIGURE 1 - Flowchart showing the sequence of methodological research

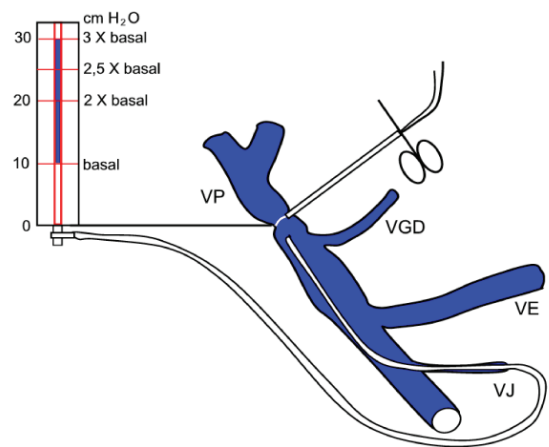


FIGURE 2 - Partial exclusion of the portal vein (PV) and measurement of portal pressure (PP) by jejunal vein catheterization (VJ) GDV=gastroduodenal vein LV=splenic vein

Initially, after fasting for 12 hours, each animal underwent endotracheal intubation under anesthesia with sodium thiopental, for peripheral venous access at a dose of 0.08 mg/kg. In the same way, it was administered ketamine hydrochloride and pancuronium at a dose of 2 mg/kg ketamine being used at the same dosage for maintenance of anesthesia (Figure 1). Hydration was maintained with 0.9% saline at a dose of 10 ml/kg/h,

infused throughout the experiment⁵.

Before the actual operation, the following procedures were performed: continuous monitoring of HR and rhythm through electrodes on the skin and dissection of the brachial artery and vein to measure, respectively, in MAP and CVP. Then, laparotomy was performed for implementation of the following: dissection of the vein and jejunal electrode fixation in jejunum biopsies of the bowel wall and partial occlusion of the portal vein during the pre and during occlusion. Aiming to assess the PP, the dissection of the jejunal vein was close to the cranial mesenteric vein and the duodenojejunal angle (Figure 3).

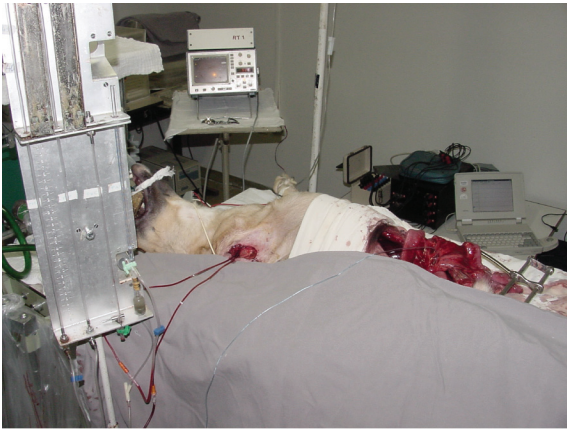

FIGURE 3 - Image of the animal underwent laparotomy with hemodynamic monitoring and evaluation of intestinal motility

To start the process of portal occlusion, the cardiac tape involving the portal vein was pulled and the white tube was secured with a hemostat, to increase PP to the desired level between 2.5 and 3 times higher than baseline (Figure 2).

For registration of myoelectric activity, it was used bipolar electrodes MP-285-B, monochrome 2-0, which are strands of cardiovascular pacemaker, and have found a 4 cm segment at the end, whose area was implanted and fixed catgut suture with 3-0[®] in the outer layers (seromuscular) wall of the jejunum⁶. Thus, the electrodes were placed in pairs, beginning 25 cm from the duodenojejunal angle, keeping 15 cm distance between each pair, resulting in the placing of three pairs.

The other end of each electrode was exteriorized through the midline incision in the abdomen to be connected to an amplifier attached to a notebook containing data acquisition system - DATAQ Akron OH, 200 series, which picks up frequencies from 0.02 to 10 Hertz, which recorded signals from myoelectric activity continuously during the two study phases. For spectral analysis of intestinal myoelectrical activity, it was considered the variance and the RMS, which is capable of determining the effective voltage of the electrical wave in the three pairs of electrodes.

In both phases of the experiment, each animal was performed four jejunal biopsies of about 1.5 cm, totaling 24 specimens taken from six animals, a biopsy was performed at the beginning of the pre-occlusion and three in the portal phase of occlusion, one at each step (Figure 1). The specimens were fixed in 10% formaldehyde followed by histological analysis. In optical microscopy, it was investigated the following changes of the mucosa: inflammatory infiltration, vascular dilatation, hemorrhage of lamina propria and detachment of the epithelial lining.

It was applied the following statistical tests: Friedman, Dunn, Student t test, Cochran, and adopted a significance level of 5% ($p < 0.05$).

RESULTS

The pre-occlusion site, the average RMS was equal to 0.5327 mV, with a statistically significant reduction ($p = 0.0022$) in the first 20 minutes of occlusion of the portal. With 40 and 60 minutes, the average RMS continued to fall short, maintaining a statistically significant difference compared to the pre-portal occlusion ($p = 0.0002$ $p = 0.0001$, respectively), as the Student t test. The comparison between the three stages of occlusion phase showed no statistically significant difference (Table 1).

Of the jejunum 24 fragments of six animals, histological inflammatory infiltrate was identified in 21 specimens (21/24 - 87.5%), vascular dilatation in 23 (23/24 - 95.8%), hemorrhage of lamina propria in eight (8/24 - 33.3%) and epithelial detachment in three (3/24 - 12.5%) (Table 1).

Inflammatory infiltrate and vascular dilation were the only ones identified in the two phases of the study, because the hemorrhage of lamina propria was restricted to the three stages of occlusion of the portal phase, and epithelial loss occurred only in steps of 40 and 60 minutes. In general, it was observed an increase in the frequency percentage of all the histological changes during occlusion of the portal vein, in proportion to the time of stasis, particularly when evaluating the bleeding and detachment of the blade (Table 1).

Despite this observation, the Cochran test showed no statistically significant difference between the four stages of the study, which includes two phases, considering the frequency percentage of inflammatory infiltrate ($p = 0.500$), vascular dilatation ($p = 0.392$) and detachment epithelium ($p = 0.500$). The hemorrhage of lamina propria was the only statistical significance between the four stages ($p = 0.015$), especially when comparing the pre-occlusion and portal phase of 60 minutes of occlusion ($p < 0.05$). All variables are summarized in Table 1.

The pre-occlusion site, the mean PP of the six dogs was equal to 8.3 cm H₂O, with an increase of 2.8 times in the first 20 minutes of occlusion, which resulted

TABLE 1 - Histological data of the myoelectric activity and hemodynamics of dogs in the pre-occlusion and occlusion of the portal vein

Phase	Inflammatory infiltrate		Vascular dilatation		Lamina propria hemorrhage		Epithelial detachment		Myoelectric activity mV				MAP mmHg	HR bpm	CVP cmH ₂ O	PP cmH ₂ O	↑PP
	Degree	n° %	Degree	n° %	Degree	n° %	Degree	n° %	RMS	\bar{X}	DP	Variance	\bar{X}	\bar{X}	\bar{X}		
Pre-occlusion	L 4	66,6*	L 5	83,3	- - -	- - -	- - -	- - -	0,5327	0,2199	0,0484	105	162	8,0	8,3	1,0 x	
O C C L U S I O N	L 3	50,0	L 4	66,6	L 1	16,6	- - -	- - -	0,2909	0,2186	0,0478	92	139	6,0	23,0	2,8 x	
	M 2	33,3	M 2	33,3	- - -	- - -	- - -	- - -	-	-	-	-	-	-	-	-	
40 min	L 1	16,6	L 2	33,3	L 2	33,3	L 1	16,6	0,2411	0,2110	0,0445	87	140	6,5	22,5	2,7 x	
	M 5	83,3	M 4	66,6	- - -	- - -	- - -	- - -	-	-	-	-	-	-	-	-	
60 min	L 1	16,6	M 6	100,0	L 4	66,6	L 2	33,3	0,2421	0,1108	0,0123	81	137	6,3	22,0	2,6 x	
	M 4	66,6	- - -	M 1	16,6	- - -	- - -	- - -	-	-	-	-	-	-	-	-	
	I 1	16,6	- - -	- - -	- - -	- - -	- - -	- - -	-	-	-	-	-	-	-	-	

L = Light M = Moderate I = Intense * Basis of the proportions of histological data from steps 4 = 6

Statistical analysis of myoelectric activity (t test):

Pre-occlusion Occlusion X 20 min p = 0.0022

Pre-occlusion Occlusion X 40 min p = 0.0002

Pre-occlusion Occlusion X 60 min p = 0.0001

Occlusion 20 min X 40 min occlusion p = 0.4778

Occlusion 20 min X 60 min occlusion p = 0.4039

in the elevation of PP to 23 cmH₂O, while the other hemodynamic parameters (MAP, HR and CVP) showed a decline. In the next stage, with 40 minutes occlusion of the portal vein, the PP and MBP have evolved with a slight decrease, whereas HR and CVP showed growth of different intensities. After 60 minutes of occlusion of the portal vein, a drop of variable intensity in all four parameters and it was more remarkable for MBP.

The isolated assessment of MAP showed decrease proportional to the time of stasis, however, Friedman’s test showed that this behavior does not show statistically significant differences between the four stages of the study (p=0.326). HR also decreased during occlusion, but no statistical significance in comparison of the four stages (p=0.375).

There were lower levels of PVC in different intensities in the three stages of portal occlusion phase, compared to the pre-occlusion, occurring statistically significant difference between the four stages, according to the Friedman test (p=0.015). The PP showed an evident increase in the portal occlusion phase, statistically significant difference between the four stages, according to the Friedman test (p=0.008). During the occlusion, it was observed a slight decrease in PP, in proportion to time, and because of this, the test of Dunn’s multiple comparison showed that only 20 minutes to portal occlusion, levels of PP tended to overcome levels in the pre-occlusion site, the difference being statistically significant (p<0.01). Among other steps, there was no statistically significant difference (p> 0.05).

DISCUSSION

Although gastrointestinal motility be known for more than a century, only since the past three decades were more interested in the subject. Thus, there were numerous experimental studies, whereas clinical studies

have been performed less frequently^{1,7,9,13} probably due to the need to respect ethical and logistical aspects, besides the greater probability of bias.

The few experimental studies that correlate the motility of the small intestine and portal hypertension emphasize the effects promoted by the prolonged splanchnic chronic intestinal stasis, or else use other methods of analysis, such as intestinal transit time with radioisotopes, to the detriment of the analysis of myoelectric activity, through whose diagnosis was used in this research by implanting electrodes in the serosal layer of the intestine of dogs^{7,13}. Thus, in the literature, there is no specific evaluation of the behavior of the myoelectric intestinal function, resulting from acute portal stasis.

The two phases of this study consisted of variables determined by the level of the PP, which is an independent variable, which was strictly controlled during the experiments. Thus, the values of PP were determined by the researcher with the aim of making the two phases differ from each other only in relation to these pressure levels, seeking uniformity in relation to other variables. At the time of portal occlusion, the PP was increased from 2.5 to 3 times compared to baseline, through proper traction of the tape that surrounded the cardiac vein.

All other parameters were formed in the dependent variables, and thus were not controlled by the researcher, the results presented in random function of the causal variable, which was determined by measuring the PP, or ultimately, for the two study phases. Presumably, these phases will determine the outcome of the following dependent variables: average RMS, inflammatory infiltrate, vascular dilatation, hemorrhage of lamina propria, epithelial loss, MAP, HR and CVP.

The levels of PP were high in the portal occlusion, searching for resemblance to the clinical situation of

acute portal hypertension, which commonly occurs after extensive hepatectomy or partial liver transplantation, in which PP increases by around two-fold relative to pre-operative baseline values^{8,11,13}. The measurements of PP during occlusion of the portal vein were also guided by the possibility of developing a model of portal hypertension with acceptable hemodynamics, which led to small fall in MAP and HR, and thus no statistically significant differences between the two observed phases.

Another reason for choosing a model of partial occlusion was the knowledge that the dog can not resist the complete portal clamping, due to shortage of portosystemic collateral veins, resulting in cardiovascular collapse due to insufficient blood to maintain systemic circulation^{2,3} effective.

In the early experiments, it was raised the following assumptions: acute portal hypertension, with a PP of between 2.5 and 3 times above baseline; may reduce the average RMS of myoelectric activity of small intestine of dogs, allowing the occurrence change in the histology of jejunal mucosa in relation to its pre-occlusion portal.

Throughout the experiment, the experimental and control group were present in the same animal, respectively, in the pre-occlusion and occlusion of the portal phase. This type of study design reduced the likelihood of the emergence of confounding variables, since each animal was its own control.

In this study, three pairs of electrodes implanted directly into the seromuscular layer of the small intestine were able to detect small changes in electrical activity of the body wall, from the use of an amplifier attached to a notebook containing a data acquisition system, that captured frequencies between 0.02 and 10 Hertz, and signals from myoelectric activity recorded continuously throughout surgery.

The main disadvantage of this method is the need for laparotomy for implantation of electrodes, but in a canine model used there was no inconvenience due to completion of abdominal surgery for another procedure, execution key to the experiment, which was the partial occlusion of the portal vein.

In the current study, considering the various evidences discussed above, it was found the reliability of the methods employed, and the possibilities that were removed from external interference, and thus highly suggestive that increased PP is primarily responsible for the changes in myoelectric activity, histological and hemodynamic results will be discussed below.

At the time of portal occlusion, the average RMS decreased significantly in comparison to baseline levels. The comparison of the three stages of phase with each other portal occlusion was not statistically significant.

Unlike the results of current research, in 1990, Jacobs et al.⁹ showed no change in intestinal motility in chronic model of portal hypertension,

according to the registration of myoelectric activity conducted from electrodes placed on the serosa layer of the isolated jejunal loop in dogs.

Corroborating the results of the current study, in 1994, Wang et al.¹³ showed an increase in intestinal transit time with a time of experiment in the group undergoing hepatectomy. The intestinal transit time was assessed through the use of radioisotopes in rats undergoing hepatectomy with 90% resection of the parenchyma, and another group with acute portal hypertension caused by portal vein stenosis calibration.

In this research, the histological findings of 24 jejunal fragments taken from six dogs showed inflammatory infiltrate in 87.5% of the animals, and vascular dilatation in 95.8%, whereas hemorrhage of lamina propria and epithelial loss occurred in smaller proportions (33.3% and 12.5% respectively).

Inflammatory infiltrate and vascular dilation were identified only with great frequency percentage in the pre-occlusion portal. Whereas this phase represents the state of normal tissue, it was expected that these changes occurred in smaller proportions; however, the high rate of inflammatory infiltrate was considered within normal limits for the standards canines undergoing laparotomy for bowel manipulation, since the small intestine was mobilized to perform invasive monitoring of PP and affixing the electrodes in the jejunal wall. This may have caused an increased number of inflammatory cells in the intestinal mucosa, besides the possibility of a vascular dilatation at low intensity.

From the first minutes of occlusion of the portal phase, the mucosa showed inflammatory infiltrate and vascular dilation in a higher frequency percentage in relation to pre-occlusion, reaching in all cases occur after 40 minutes of occlusion of the portal vein, probably, due to longer splanchnic stasis. Despite these observations, no significant difference between the four stages was evaluated.

Sebe et al.¹² studied the histopathological changes of the small intestine into three groups of rats subjected to total occlusion of the hepatic pedicle for 10, 20 and 30 minutes, and also observed that the intensity of splanchnic congestion was proportional to the time of stasis, whereas the control group, not subjected to occlusion of the pedicle vessels, presented with typical lamina propria lymphocytes and few plasma cells, and without dilation of blood vessels and lymphatics. With 10 minutes of total occlusion, the histological features were almost normal, with only lymphoplasmacytic infiltration and mild vascular dilation, which became intense with 20 minutes of total occlusion.

In this research, intense vascular dilatation was diagnosed from 40 minutes of partial occlusion, whose difference in intensity and frequency of such studies may be explained by the degree of occlusion, since this applied research stenosis and total non-clamping, as indicated by Sebe et al.².

The literature on experimental partial occlusion of

the portal vein showing interstitial edema and severe dilation of the intestinal mucosa, shows agreement with the findings of the present investigation¹².

In the current study, the hemorrhage of the lamina propria and epithelial loss occurred only during the portal occlusion. This shows that these changes are not found in normal. They are related to stasis of the portal system in proportion to the time of venous obstruction, especially when evaluating the isolation of lamina propria hemorrhage. This was the only statistical significance between the four stages of the study, specifically the comparison of pre-occlusion site with step of 60 minutes of occlusion ($p < 0,05$).

The increase in PP determines vascular dilation in the mucosal villi, resulting in the breaking of the vessels and consequent hemorrhage in the lamina propria. Concurrently, the process determines congestive loss of adhesion between the epithelium and lamina propria, which leads to detachment of epithelial layer, and in some cases, bleeding occurs into the intestinal lumen. In general, according to the results of this experiment, the frequency and severity of histologic changes were proportional to the time of portal stasis.

The sloughing of the epithelial lining was identified only with 40 and 60 minutes of occlusion of the portal vein, which represent the advanced stages of splanchnic venous stasis, reflecting the gravity of the situation. As Sebe et al.¹² hemorrhage of lamina propria and epithelial layer of large areas of the intestinal villi of mice occurred at 30 minutes of pedicle clamping, whose time was earlier than in the present study, probably due to complete portal occlusion.

During the portal occlusion, there was a slight decrease in PP, which started with 23 cmH₂O and ended at 22 cmH₂O with 60 minutes of occlusion, which reflects the accommodation which usually occurs in the splanchnic system due to the complacency of the parenchymal organs involved. The spleen is the main responsible for this phenomenon, due to the abduction of portal blood on the inside or even have a large increase in volume during the experiment. In the present study, occlusion of the portal vein was performed to evaluate the effects of acute portal hypertension on the small intestine, the histological point of view and motility, seeking to avoid the interference of hypotension.

The partial occlusion of the portal vein of dogs promoted the following statistically significant changes: decrease in myoelectric activity of small intestine, hemorrhage of lamina propria, which was proportional to the time of splanchnic venous stasis, and decreased CVP and increased PP.

CONCLUSION

The partial occlusion of the portal vein of dogs caused a decrease of myoelectric activity, increased the frequency of hemorrhage of the lamina propria, fall of PVC, with relative hemodynamic stabilization.

REFERENCES

1. Battersby C, Balderson G, Winch J, Burnett W. Acute occlusion of the portal vein in the calf. *J Surg Res* 1971;11(2):95-100.
2. Beach PM, Torres E, Litton A, Kundsir R. Acute occlusion of the portal vein in dogs. *Surg Gyn Obst* 1965;121(4):761-6.
3. Child CG. The portal circulation. *N Engl J Med* 1955;252(20):837-50.
4. Cortopassi SRG. Fluidoterapia na anestesia. In Fantoni DT, Cortopassi SRG, ed. *Anestesia em cães e gatos*. São Paulo: Ed. Roca; 2002;1:109-19.
5. Ferraz AAB, Bacelar TS, Santos Jr MA, Vasconcelos HG, Figueiredo FL, Vasconcelos HMC, Ferraz EM. Atividade mioelétrica do cólon: Descrição de metodologia. *Rev Bras Coloproctol* 1995;15(3):114-21.
6. Granger DN, Barrowman JA. Microcirculation of the alimentary tract. Pathophysiology of edema. *Gastroenterology* 1983;84(5):1035-49.
7. Gullstrand PM, Vernon WB, Bollinger RR. Temporary occlusion of the portal vein in the rat. *Trans Proc* 1986;18:1220.
8. Heaton N. Small-for-size liver syndrome after auxiliary and split liver transplantation: donor selection. *Liver Transpl* 2003;9(9):S26-8.
9. Jacobs DL, Lof J, Quigley EM, Spanta AD, Rikkers LF. The effect of mesenteric venous hypertension on gut motility and absorption. *J Surg Res* 1990;48:562-7.
10. Lee SS, Hadengue A, Girod C. Reduction of intrahepatic vascular space in the pathogenesis of portal hypertension. *Gastroenterology* 1987;93:157-61.
11. Moriura S, Nimura Y, Kato M, Sato T, Shionoya S. Effects of acute portal hypertension by portal venous stenosis on systemic hemodynamics in dogs. *Eur Surg Res* 1990;22:113-9.
12. Sébe AA, Nigro AJT, Gomes PO, Simões MJ. Efeitos do clampeamento do pedículo hepático nos intestinos. *Acta Cir Bras* 2000;15:39-41.
13. Wang XD, Guo WD, Wang Q, Andersson R, Ekblad E, Soltész V. The association between enteric bacterial overgrowth and gastrointestinal motility after subtotal liver resection or portal vein obstruction in rats. *Eur J Surg* 1994;160:153-60.