

LAPAROSCOPIC TOTALLY EXTRAPERITONEAL HERNIOPLASTY WITH NONFIXATION OF THREE-DIMENSIONAL MESH – DULUCQ'S TECHNIQUE

Hernioplastia laparoscópica totalmente extraperitoneal com tela 3-d sem fixação – técnica de Dulucq

Alberto MEYER¹, Jean-Louis DULUCQ², Ahmad MAHAJNA³

From ¹Department of Surgery, Professor Edmundo Vasconcelos Hospital, São Paulo, Brazil; ²Institut de Chirurgie Laparoscopique, Bordeaux, France; and ³Department of Surgery A, Rambam Medical Center and Rappaport Faculty of Medicine, Technion-Israel Institute of Technology, Haifa, Israel.

HEADINGS - Laparoscopic surgery. Inguinal hernia. Surgical mesh

Correspondence:

Alberto Meyer, e-mail: almmeyer@usp.br

Financial source: none

Conflicts of interest: none

Received for publication: 20/11/2012

Accepted for publication: 15/01/2013

DESCRITORES - Laparoscopia. Hérnia Inguinal. Tela cirúrgica

ABSTRACT - Introduction - The inguinal hernia repair has been a controversial area in the surgical practice ever since it has been conceived. The fact that numerous different procedures are in use reflects the complexity of inguinal hernia and its repair. **Aim** - The purposes of this study were to describe Dulucq's technique and the modifications of using 3-D mesh in laparoscopic totally extraperitoneal inguinal hernia repair. **Methods** - Surgical technique of laparoscopic totally extraperitoneal hernia repair is detailed on the text. **Conclusion** - Laparoscopic totally extraperitoneal is preferred over transabdominal preperitoneal hernia as the peritoneum is not violated. The dissection must always be done with the same stages, without monopolar diathermy and the patient in a slight Trendelenburg position. Following these recommendations, the laparoscopic totally extraperitoneal hernioplasty is feasible with fewer intra-abdominal complications.

RESUMO – Introdução - A reparação da hérnia inguinal tem sido área controversa na prática cirúrgica, desde que desde que ela foi concebida. O fato de que inúmeros procedimentos diferentes estão em uso reflete a complexidade de hérnia inguinal e seu reparo. **Objetivo** - Descrever a técnica de Dulucq e as modificações do uso da tela 3-D na correção de hérnia inguinal laparoscópica totalmente extraperitoneal. **Métodos** - A técnica da correção da hérnia laparoscópica totalmente extraperitoneal é detalhada no texto. **Conclusão** - Correção laparoscópica totalmente extraperitoneal é preferível à correção de hérnias transabdominais pré-peritoneais porque o peritônio não é violado. A dissecação deve ser sempre realizada nos mesmos passos, sem utilizar cautério monopolar e o paciente em leve posição de Trendelenburg. Com estas recomendações, a hernioplastia laparoscópica totalmente extraperitoneal é factível com poucas complicações intra-abdominais.

INTRODUCTION

The inguinal hernia repair has been a controversial area in the surgical practice ever since it has been conceived⁸. The fact that numerous different procedures are in use reflects the complexity of inguinal hernia and its repair. The totally extraperitoneal procedure combines the advantages of tension-free mesh reinforcement of the groin with those of laparoscopic surgery, reduces postoperative pains and curtailes recovery time while avoiding the need of transabdominal approach⁷. The establishment of this technique by Dulucq in Europe may be considered a logical further development of transabdominal preperitoneal hernia repair^{5,6}. This paper describes and discuss the Dulucq's technique and the modifications of using 3-D mesh in totally extraperitoneal procedure inguinal hernia repair.

METHODS

Surgical technique

Preoperative preparation

The totally extraperitoneal procedure is performed under general anesthesia and single antibiotic shot prophylaxis (cephalosporin or cefazolin). The patient urinates just before the surgery and is placed in the supine position; the arm is set along the body on the side opposite the hernia. The surgeon stands on the side opposite the hernia. The patient is placed in a slight Trendelenburg position.

The operation step 1: extraperitoneal access

Verres needle is first inserted in the midline just above the pubis in the suprapubic space of Retzius. Is used three regular trocars in the midline. An infraumbilical transverse incision is made. A 10-mm trocar is inserted in the subcutaneous plane in a horizontal direction, then slowly lifted up and introduced at an angle of 60° towards the sacrum.

The operation step 2: dissection of the preperitoneal space

The laparoscope is introduced through the infraumbilical port and the preperitoneal space is visualized. Is used the 0° laparoscope for the preperitoneal dissection. The insufflation continues with a pressure set at no higher than 12 mmHg. A hand holds the optic, the other one leaning on the abdominal wall. It is a question of balance between left and right.

Step 2.1: medial dissection

With the laparoscope the surgeon creates a medial tunnel. There are three essential marks: A) the pubic bone; B) the arcuate line; C) the inferior epigastric vessels (Figure 1). The first step is to identify the pubic bone which appears as a white glistening structure in the midline. The second anatomical key is the arcuate line on the side. The third, is the inferior epigastric vessels.

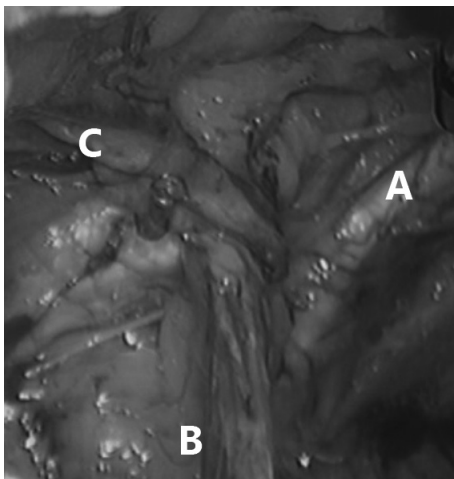


FIGURE 1 - Essential marks: A - pubic bone; B - cord structures; C - inferior epigastric vessels

Under direct visualization two 5 mm trocars are placed in the midline: one just above the pubis and the other between the first two trocars (Figure 2)². In the case of direct hernia, the hernia sac is visualized before the inferior epigastric vessels. In the indirect hernia, the inferior epigastric vessels are seen before the hernial sac is encountered.

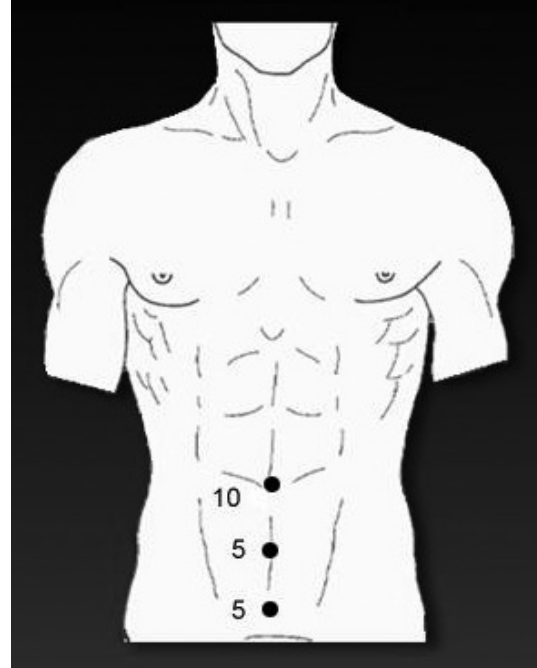


FIGURE 2 - Trocar's position

Step 2.2: lateral dissection

This is the time to dissect the lateral space. The passage to do the lateral dissection is in the angle between the arcuate line and the inferior epigastric vessels. If the arcuate line extends lower, a short incision (scissors without coagulation) must be made in it to ensure safe and adequate dissection. The lateral dissection is done all the way up to the psoas muscle inferolaterally, thereby exposing the nerves in the "lateral triangle of pain"^{3,11}. The lateral space contains loose areolar tissue, which is completely divided using blunt dissection.

The operation step 3: hernia dissection

The hernia is completely dissected of the cord structures and reduced, after the peritoneal sac with reflection is completely reduced (Figure 3). The vas deferens is seen lying separately on the medial side and gonadal vessels are seen on the lateral side forming a triangle. This triangle, known as "triangle of doom" is bounded medially by the vas deferent, laterally by gonadal vessels with its apex at the internal inguinal ring and the basis is formed by the peritoneum³.

The operation step 4: placement of the mesh

The 3-D anatomically contoured polypropylene mesh is introduced through the 10-mm infraumbilical

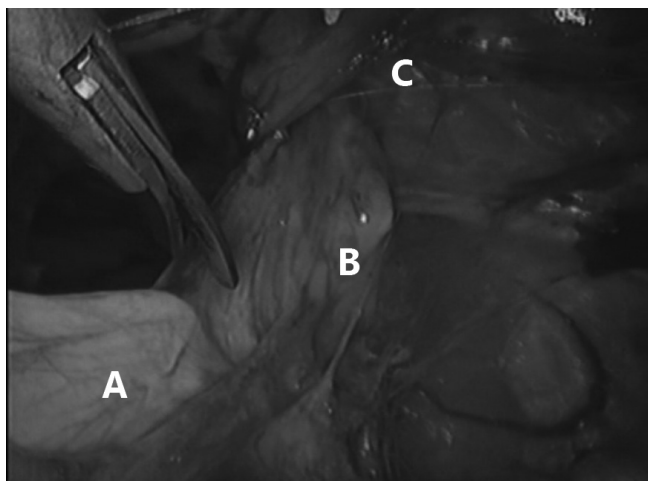


FIGURE 3 - Hernia dissection: A - peritoneal sac; B - cord structures; C - internal inguinal ring

port, placed over the space created for it to cover the sites of direct, indirect, femoral and obturator hernias. The mesh must be large enough measuring at least 10 x 15 cm for the hernial ring to be nearly in the middle of the mesh¹¹. A good mesh must be supple and easy to place. In the bilateral hernia, it's easier to place two meshes instead of placing one large piece of mesh. Thanks to the anatomical mesh the stapling is not necessary anymore¹. To avoid possible damage to nerves, staple fixation of the meshes used only in exceptional cases involving a highly enlarged internal ring. In this case the mesh is only stapled medially and to the Cooper's ligament to avoid neuralgia¹⁰.

The operation step 5: the deflation process

The deflation process happens under direct visualization, the hernial sac and lipoma are placed behind the mesh. The extraperitoneal space is then inspected for haemostasis, desufflated abdomen, and the skin incisions are then closed. During the deflation process, repositioning of the peritoneal sac on the mesh, in particular the dorsal edge of the latter is carefully performed to avoid displacement or folding of the mesh. Its not necessary any drainage.

Postoperative course

The operation can well be performed in a day surgery unit⁴. Ambulatory surgery appears to have benefits in terms of organization and economics. The hospital costs are cheaper in ambulatory surgery, and the ambulatory surgery keeps resources free for

complex cases and emergencies. A technique without balloon dissection, without stapling and in ambulatory surgery is less expensive⁹.

CONCLUSION

Totally extraperitoneal procedure is preferred over transabdominal preperitoneal hernia repair as the peritoneum is not violated and with an acceptably low complication rate. The dissection must always be done with the same stages, without monopolar diathermy and the patient in a slight Trendelenburg position. Following these recommendation, the totally extraperitoneal procedure hermioplasty is feasible with fewer intra-abdominal complications.

REFERENCES

1. Beattie GC, Kumar S, Nixon SJ. Laparoscopic total extraperitoneal hernia repair: mesh fixation is unnecessary. *J Laparoendosc Adv Surg Tech A* 2000;10:71-3.
2. Blanc P, Meyer A, Delacoste F, Atger J. Traitement des Hernies Inguinales par Coelioscopie par la voie Totalement Extrapéritonéale (TEP): la distance ombilico-pubienne influence-t-elle la technique? *The European Journal of Laparoscopy*. 2011;79:1-4.
3. Brassier D, Elhadad A. Classic and endoscopic surgical anatomy of the groin. *J Chir (Paris)* 2007;144:5-10.
4. Duff M, Mofidi R, Nixon SJ. Routine laparoscopic repair of primary unilateral inguinal hernias, a viable alternative in the day surgery unit? *Surgeon* 2007;5:209-12.
5. Dulucq JL. Traitement des hernies de l'aîne par mise en place d'un patch prothétique sous-péritonéal en rétropéritonéoscopie. *Cahiers de Chir* 1991;79 :15-6.
6. Dulucq JL, Wintringer P, Mahajna A. Laparoscopic totally extraperitoneal inguinal hernia repair: lessons learned from 3100 hernia repairs over 15 years. *Surg Endosc* 2009;23:482-6.
7. Heniford BT, Park A, Ramshaw BJ, et al. Laparoscopic repair of ventral hernias: nine years' experience with 850 consecutive hernias. *Ann Surg* 2003;238:391-9.
8. Millat B. Inguinal hernia repair. A randomized multicentric study comparing laparoscopic and open surgical repair. *J Chir* 2007;144:94-5.
9. Misra MC, Kumar S, Bansal VK. Total extraperitoneal (TEP) mesh repair of inguinal hernia in the developing world: comparison of low-cost indigenous balloon dissection versus direct telescopic dissection: a prospective randomized controlled study. *Surg Endosc* 2008;22:1947-58.
10. Sampath P, Yeo CJ, Campbell JN. Nerve injury associated with laparoscopic inguinal herniorrhaphy. *Surgery* 1995;118:829-33.
11. Simons MP, Aufenacker T, Bay-Nielsen M, Bouillot JL, Campanelli G, Conze J, de Lange D, Fortelny R, Heikkinen T, Kingsnorth A, Kukleta J, Morales-Conde S, Nordin P, Schumpelick V, Smedberg S, Smietanski M, Weber G, Miserez M. European Hernia Society guidelines on the treatment of inguinal hernia in adult patients. *Hernia* 2009;13:343-403.