

# Neonatal lupus erythematosus: a report of four cases <sup>\*</sup>

## Lupus eritematoso neonatal: reporte de cuatro casos

Maria Fernanda Perez <sup>1</sup>  
María Marta Buján <sup>2</sup>  
Andrea Bettina Cervini <sup>4</sup>

Maria Eugenia de Torres <sup>1</sup>  
Agustina Lanoël <sup>3</sup>  
Adrián Martín Pierini <sup>5</sup>

**Abstract:** Neonatal lupus erythematosus is a very rare disease, clinically characterized by skin lesions that resemble those of subacute or discoid lupus erythematosus and/or congenital heart block. Generally, when patients have skin manifestations, they have no cardiac defects and vice-versa; however, in 10% of cases these manifestations may coexist. Other findings may include hematologic, hepatic and neurological abnormalities. This condition is caused by the transplacental passage of maternal autoantibodies against Ro (95%), La and, less frequently, U1-ribonucleoprotein (U1-RNP). The present case report describes four patients with clinical, histopathological and immunological findings compatible with neonatal lupus erythematosus, their treatment and progress.

**Keywords:** Cutaneous; Heart diseases; Lupus erythematosus, pediatrics

**Resumen:** El lupus eritematoso neonatal es una enfermedad poco frecuente, caracterizada clínicamente por alteraciones cutáneas semejantes al lupus subagudo o discoide y/o bloqueo cardíaco congénito. Generalmente, cuando los pacientes presentan manifestaciones cutáneas, no tienen anomalías cardiológicas y viceversa, aunque en un 10% de los casos ambas manifestaciones pueden coexistir. Puede acompañarse también de alteraciones hematológicas, hepáticas y neurológicas. Es causado por el pasaje trasplacentario de anticuerpos maternos anti Ro (95%), anti La y menos frecuentemente anti U1RNP. Presentamos cuatro pacientes con hallazgos clínicos, histopatológicos e inmunológicos compatibles con lupus eritematoso neonatal, su tratamiento y evolución.

**Palabras clave:** Cardiopatías; Lupus eritematoso cutáneo; Pediatría

### INTRODUCTION

Neonatal lupus erythematosus (NLE) is an autoimmune disorder characterized by the presence of skin lesions and/or cardiac complications in newborn infants of mothers with autoantibodies against Ro, La and, less commonly, U1-ribonucleoprotein (U1-RNP). Skin and cardiac manifestations coexist in only 10% of patients. <sup>1-4</sup> Hepatic, hematological and, less commonly, pulmonary, neurological and gastrointestinal abnormalities may also be present.

### CASE REPORTS

#### *Patient #1*

A 3-month old baby boy with erythematous, annular lesions with well-defined borders and lighter-colored centers on his face and upper limbs, forming a reticulated pattern on the lower limbs and back. The lesions had developed around one month previously and the patient had hepatosplenomegaly (Figure 1). Both his mother and his maternal grandmother had been diagnosed with systemic lupus ery-

Received on 02.03.2010.

Approved by the Advisory Board and accepted for publication on 15.03.10.

\* Study conducted at the Professor Dr. Juan P. Garrahan Pediatric Hospital, Buenos Aires, Argentina.

Conflict of interest: None / *Conflicto de Intereses: Ninguno*

Financial funding: None / *Apoyo Financiero: Ninguno*

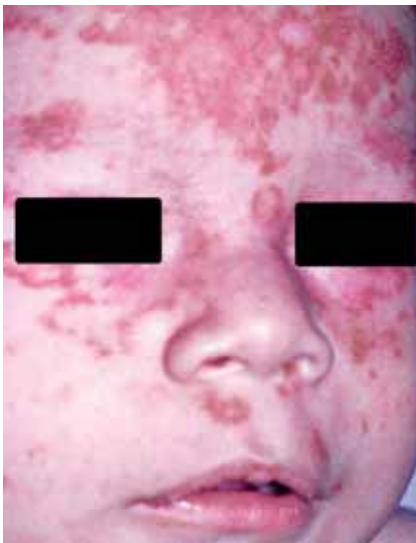<sup>1</sup> Pediatrician, Department of Pediatric Dermatology, University of Buenos Aires (UBA); Dermatology Department, Professor Dr. Juan P. Garrahan Pediatric Hospital, Buenos Aires, Argentina.

<sup>2</sup> Pediatrician and Dermatologist. Head of the Residency Program of the Dermatology Department, Professor Dr. Juan P. Garrahan Pediatric Hospital, Buenos Aires, Argentina.

<sup>3</sup> Dermatologist and Pediatrician. Assistant Physician, Dermatology Department, Professor Dr. Juan P. Garrahan Pediatric Hospital, Buenos Aires, Argentina.

<sup>4</sup> Dermatologist. Assistant Physician, Dermatology Department, Professor Dr. Juan P. Garrahan Pediatric Hospital, Buenos Aires, Argentina.

<sup>5</sup> Dermatologist. Head of the Dermatology Department, Professor Dr. Juan P. Garrahan Pediatric Hospital, Buenos Aires, Argentina.



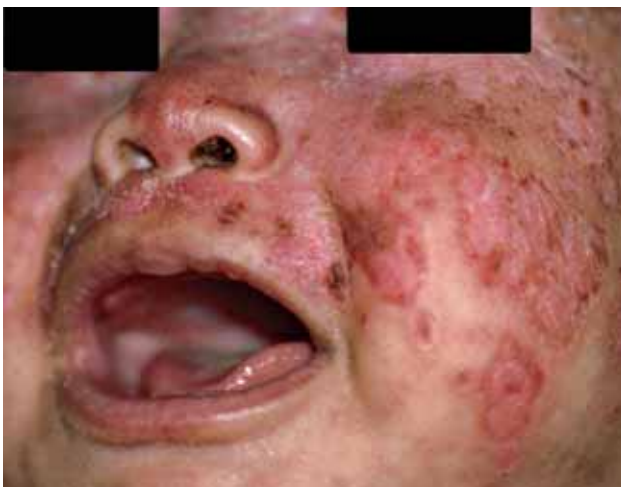**FIGURE 1:** Patient #1. Erythematous, annular lesions with well-defined margins and lighter-colored centers on the face and periorcular regions

thematosus (SLE). Supplementary tests showed the following results: hemoglobin 10 g/dl; hematocrit 30%; SGPT 78 IU/L, C3 53 mg/dl and C4 3 mg/dl; ANF+ 1/100; anti-Ro, anti-La, anti-Sm and anti-U1RNP antibodies negative. Histopathology showed: hyperkeratosis, epidermal atrophy, vacuolization of basal keratinocytes and diffuse mononuclear infiltration of the superficial dermis. Direct immunofluorescence: band segment of fine granular deposition of IgG and C3 at the dermo-epidermal junction.

Cardiologic investigation revealed no abnormalities. Treatment: hydrocortisone cream 1%. The skin lesions healed, ANF turned negative and liver function tests had returned to normal by the time the infant reached six months of life.

#### **Patient #2**

A 4-month old baby girl with squamous erythe-

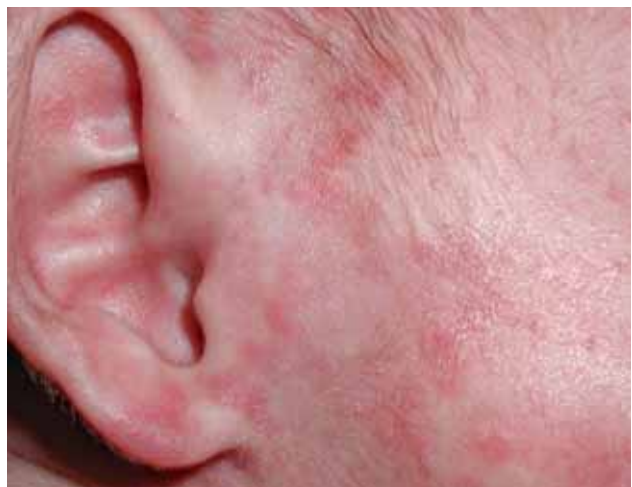

**FIGURE 2:** Patient #2. Erythematous, squamous, slightly atrophic lesions on the face, with polycyclic margins

matous lesions on her scalp, face, ears, presternal region, upper and lower limbs and on the backs of her hands (Figure 2) for the previous month. Some of the lesions were slightly atrophic, with polycyclic margins. The palms of her hands and the soles of her feet had purplish lesions resembling vasculitis and erosions of the oral mucosa and gums were found. Her mother had had SLE for the past ten years. Supplementary tests: hemoglobin 8.2 g/dl; hematocrit 25%; LDH 1092 IU/L; Coombs test was positive in both mother and child; SGOT 396 IU/L, SGPT 239 IU/L, ESR 113 mm/h; hypocomplementemia in both mother and child; ANF+ 1/1000, homogenous pattern in the child and speckled in the mother; anti-Ro and anti-La antibodies positive in both cases. Histopathology: atrophic epidermis; vacuolization of the stratum basale; dermal lymphocytic infiltration and vasculitis of the small blood vessels. Direct immunofluorescence negative. Cardiologic evaluation normal. Treatment: hydrocortisone cream 1%, resulting in remission of the lesions in 10 days. When the patient reached six months of life, residual hypopigmented and slightly atrophic lesions remained, with complete resolution of the hepatic and hematologic involvement.

#### **Patient #3**

A 6-week old baby boy presented with raised annular lesions with erythematous margins and lighter-colored centers, on his face, preauricular region and on his neck, shoulder and abdomen, the lesions on the abdomen having atrophic centers. The condition had developed two weeks earlier (Figure 3). The child's mother had been diagnosed with SLE. Supplementary tests: WBC 13300/mm<sup>3</sup>; hemoglobin 10 g/dl; hematocrit 29%; SGOT 149 IU/L; SGPT 96



**FIGURE 3:** Patient #3. Annular lesions with erythematous, raised margins, with a lighter-colored center, located in the preauricular region

IU/L; ALP 1141 IU/L; ANF+ 1/1000, densely speckled pattern in both mother and child; anti-Ro, anti-native DNA and anti-U1RNP antibodies positive in the mother. Anti-Ro and anti-La antibodies negative in the patient. (The hospital failed to measure reactions to anti-U1RNP and anti-native DNA). Histopathology: smooth epidermis; vacuolization of the basal keratinocytes; thickened basement membrane PAS+; periadnexal mononuclear infiltrate. Direct immunofluorescence negative. Cardiac evaluation normal. The skin lesions disappeared by the fifth month of life and the liver involvement by the seventh month without any need for treatment.

**Patient #4**

A 3-month old baby girl with an erythematous lesion on her face that consisted of small, annular, slightly atrophic plaques, bilaterally located on the temporal-occipital region and neck, with fine telangiectasias on the surface (Figures 4 and 5). In the genital region, an atrophic erythematous lesion with well-defined margins that developed two months previously. The mother had cicatricial alopecia, dry eyes, dry mouth and anemia but had not yet received any diagnosis at the time of consultation. Supplementary tests: hemoglobin 11.2 g/dl; hematocrit 33%; SGOT 265 IU/L, SGPT 212 IU/L; ALP 927 IU/L; C3 54 mg/dl; C4 2 mg/dl; ANF+ 1/1000, densely speckled pattern and anti-LA antibody positive (patient); ANF+ 1/2000, homogenous pattern and anti-LA and anti-Ro antibodies positive (mother). Histopathology: thick stratum corneum; thinning epidermis; intense vacuolization of basal keratinocytes in diffuse mononuclear dermal infiltrate. Thickened basal membrane (Figure 6). Direct immunofluorescence negative. Cardiac evaluation normal. Treatment: topical hydrocortisone

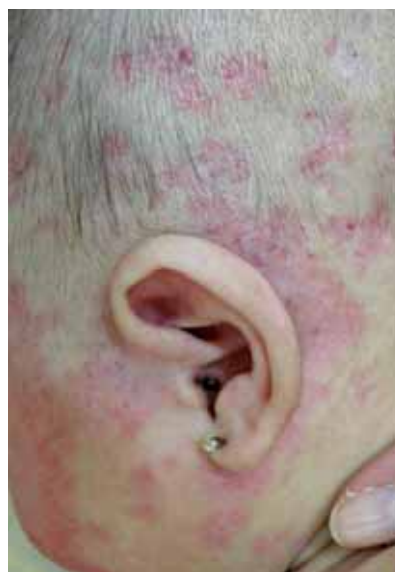

FIGURE 5: Patient #4. Annular, erythematous, slightly atrophic plaques with telangiectasia on the scalp, in the temporal-occipital region and neck

1% and pimecrolimus 1%. The erythematous lesions disappeared within two weeks; however, the atrophic lesions persisted with petechiae scattered over the scalp. Liver enzymes returned to normal levels by the time the infant reached ten months of life. The patient's mother was recently diagnosed with Sjögren's syndrome.

**DISCUSSION**

Neonatal lupus erythematosus (NLE) is characterized by the presence of skin lesions, abnormal cardiac function or both in newborn infants of mothers with auto-antibodies against Ro, La and/or, less commonly, U1RNP. It is a rare disease that affects approximately 1 in every 20,000 live-born infants, principally girls (65%),<sup>5</sup> although this trend was not seen in the

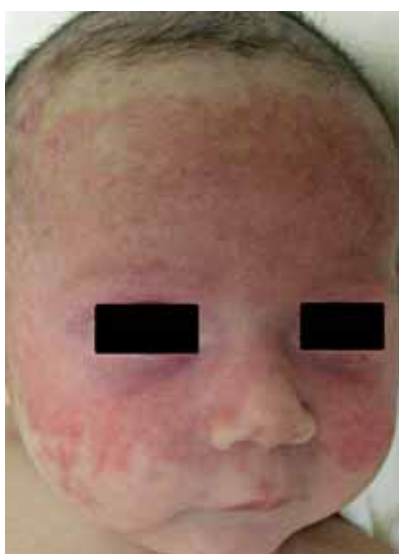

FIGURE 4: Patient #4. Erythematous lesion on the face

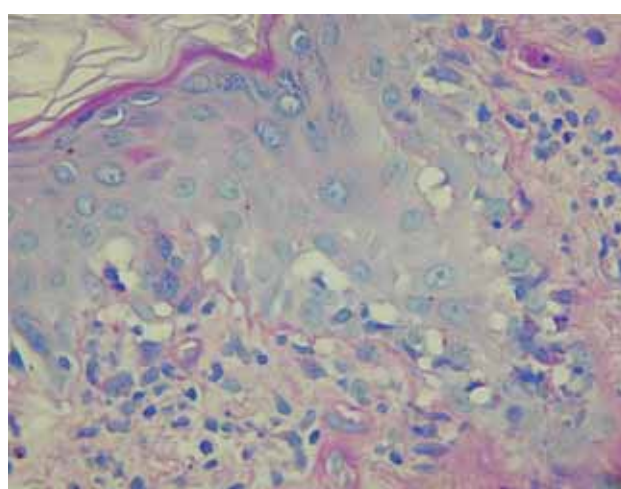


FIGURE 6: PAS technique: vacuolization of basal keratinocytes, thickened basal membrane, PAS+



patients included in this report. It presents in the children of women who have been diagnosed with systemic lupus erythematosus (SLE), Sjögren's syndrome and other types of collagen-vascular diseases. Approximately 50% of mothers are asymptomatic at the time of diagnosis, testing positive only against Ro auto-antibodies.<sup>2,3,6</sup> In our patients, three of the mothers had SLE and one was diagnosed with Sjögren's syndrome.

The pathogenesis of this disorder remains to be fully clarified; however, the transplacental passage of antibodies, principally anti-Ro antibodies (present in 95% of cases of children with NLE and their mothers) is fundamental. The transitory nature of the manifestations that coincides with the disappearance of the antibodies circulating in the infant's blood tends to confirm this hypothesis. The results of animal studies in which NLE lesions were reproduced further reinforce this hypothesis.<sup>3,7</sup> The Ro antigen is found in the skin, heart, liver, bowel, lungs, brain and blood cells, the tissues that are most often affected by NLE. Ultraviolet light and estrogens increase Ro antigen expression on the surface of the keratinocyte.

Nevertheless, the presence of autoantibodies is necessary but insufficient in itself to produce NLE. There is even discordance between twins; therefore, it is believed that unknown factors exist that render some infants susceptible in the presence of maternal autoantibodies.

The skin lesions provoked by NLE may be congenital (20%) or appear during the first three months of life. They consist of erythematous, squamous plaques with raised margins and lighter colored centers. They are annular or polycyclic in shape and disappear before the infant completes one year of life. In the majority of patients, the lesions appear in photo-exposed areas of the body (the face and scalp), although the skin of any other region may also be affected. Periocular erythema, referred to as "raccoon eyes" is a very common characteristic. Purplish, atrophic telangiectasias and erythema multiform-like lesions are less common.<sup>2,3,5,7-10</sup> Treatment of the skin lesions consists of photoprotection and low-strength topical corticosteroids. Laser treatment may be necessary for residual telangiectasias.

The cardiologic abnormality that is characteristic of NLE is third-degree atrioventricular block, which develops in the second trimester of pregnancy and is permanent.<sup>11</sup> Fetal bradycardia raises the suspicion of NLE during pregnancy and may be confirmed by

fetal echocardiography.<sup>3,7,12</sup> The mortality rate in infants with congenital heart block (CHB) is around 20% even with implantation of a pacemaker, a procedure that is required in 50-100% of cases.<sup>4,6,11-13</sup>

The risk of heart involvement in the firstborn child of an anti-Ro-positive mother is 1-2% and occurrence of the same disorder in a second child is 18%.<sup>14</sup> The efficacy of intravenous immunoglobulin is currently being evaluated for the prophylactic treatment of CHB in high-risk pregnancies (mothers who already have children with NLE) and it is recommended that fetal echocardiography should be performed from the sixteenth week of pregnancy onwards in all anti-Ro-positive mothers.<sup>11,14</sup>

Liver involvement in NLE, which occurs in 10% of cases, usually manifests as liver failure, cholestasis or an increase in transaminase levels.<sup>11</sup> All the patients in the present report had liver involvement, which resolved spontaneously.

The most commonly described hematological manifestations (10% of cases) are thrombocytopenia, anemia, neutropenia and pancytopenia.<sup>11</sup> These alterations are usually transitory and mild.

Other organs such as the lungs and digestive tract are rarely affected. The possibility of neurological involvement associated with NLE has been investigated. Studies were conducted in which patients with NLE or the children of anti-Ro-positive mothers, were evaluated by neuroimaging and cephalic perimeter measurement. A greater frequency of abnormalities was found in these patients compared to healthy controls.<sup>15,16</sup>

Differential diagnoses of skin lesions are made with seborrheic dermatitis, tinea corporis, psoriasis, atopic dermatitis, granuloma annulare, neonatal acne, erythema multiforme, Langerhans cell histiocytosis and congenital infections.<sup>3</sup>

The diagnosis of NLE is established from characteristic clinical findings and the identification of the abovementioned antibodies in the mother and child. Histopathology of the skin is compatible with subacute cutaneous lupus,<sup>11</sup> although in general this is not necessary for confirmation of diagnosis.<sup>15</sup>

The prognosis of the disease is defined by the cardiac involvement, since most of the other manifestations are transitory and self-resolving. Long-term follow-up is vital in these patients, since they are at an increased risk of developing autoimmune diseases in late childhood or adulthood. □

## REFERENCES

1. Lanoël A, Cervini B, Kobrin A, García Díaz R, Laterza A, Pierini AM, et al. Lupus eritematoso neonatal, a propósito de un caso. *Med Infant*. 2006;13:73-6.
2. Lee LA. Neonatal lupus erythematosus. *J Invest Dermatol*. 1993;100:9S-13S.
3. Aparicio Español G, García Patos Briones V, Castells Rodellas A. Lupus eritematoso neonatal. *Piel*. 2002;17:353-9.
4. Palermo RH. Enfermedades que se transmiten a través de la placenta en Pueyo de Casabé ST, Valverde RA: *Dermatología Neonatal*. 1 ed. Buenos Aires; 2005. p.607-8.
5. Lee LA. Neonatal lupus erythematosus: clinical findings and pathogenesis. *J Invest Dermatol Symp Proc*. 2004;9:52-6.
6. Silverman ED. Neonatal Lupus Erythematosus en Cassidy JT, Petty RE: *Textbook of Pediatric Rheumatology*. 4th ed. Philadelphia: W.B.Saunders; 2001. p.450-8.
7. McCauliffe DP. Neonatal lupus erythematosus: a transplacentally acquired autoimmune disorder. *Semin Dermatol*. 1995;14:47-53.
8. Lee LA. The clinical spectrum of neonatal lupus. *Arch Dermatol Res*. 2009;301:107-10.
9. Cabrera HN, Kaminsky A, Braschiera VV. Lupus eritematoso neonatal. *Dermatol Argent*. 1997;3:141-4.
10. Berbert ALCV, Mantese SAO. Lúpus eritematoso cutáneo - Aspectos clínicos e laboratoriais. *An Bras Dermatol*. 2005;80:119-31.
11. García Díaz R, González MT, Cravioito R, Goldberg J, Pierini AM. Lupus eritematoso neonatal: presentación de un caso clínico y revisión de la literatura. *Arch Argent Dermatol*. 2000;50:141-7.
12. Neiman AR, Lee LA, Weston WL, Buyon JP. Cutaneous manifestations of neonatal lupus without heart block: characteristics of mothers and children enrolled in a national registry. *J Pediatr*. 2000;137:674-80.
13. McCuiston CH, Schoch EP Jr. Possible discoid lupus erythematosus in newborn infant; report of a case with subsequent development of acute systemic lupus erythematosus in mother. *AMA Arch Derm Syphilol*. 1954;70:782-5.
14. Friedman DM, Rupel A, Buyon JP. Epidemiology, etiology, detection, and treatment of autoantibody-associated congenital heart block in neonatal lupus. *Curr Rheumatol Rep*. 2007;9:101-8.
15. Prendiville JS, Cabral DA, Poskitt KJ, Au S, Sargent MA. Central nervous system involvement in neonatal lupus erythematosus. *Pediatr Dermatol*. 2003;20:60-7.
16. Boros CA, Spence D, Blaser S, Silverman ED. Hydrocephalus and macrocephaly: new manifestations of neonatal lupus erythematosus. *Arthritis Rheum*. 2007;57:261-6.

## MAILING ADDRESS / DIRECCIÓN PARA CORRESPONDENCIA:

*Maria Fernanda Perez*

*Godoy Cruz 3150 3 C. Ciudad autónoma de Buenos Aires. Argentina. 1425*

*E-mail: mfperez@fibertel.com.ar*

How to cite this article/Cómo mencionar este artículo: Perez MF, de Torres ME, Buján MM, Lanoël A, Cervini AB, Pierini AM. Neonatal lupus erythematosus: a report of four cases. *An Bras Dermatol*. 2011;86(2):347-51.