

# Bullous pemphigoid in a 3-month-old infant: case report and literature review of this dermatosis in childhood\*

## Penfigoide bolhoso em lactente de 3 meses: relato de caso e revisão de literatura da dermatose na infância

Eugenio Galdino de Mendonça Reis-Filho<sup>1</sup>  
Luiza Helena de Lima Aguirre<sup>3</sup>

Tainah de Almeida Silva<sup>2</sup>  
Carmelia Matos Santiago Reis<sup>4</sup>

DOI: <http://dx.doi.org/10.1590/abd1806-4841.20132378>

**Abstract:** Bullous pemphigoid is an autoimmune subepidermal blistering dermatosis that is uncommon in childhood. We report a case of a female infant, 3 months old, which presented clinical and laboratory data for the confirmatory diagnosis of bullous pemphigoid. The authors used immunohistochemical staining for collagen type IV that allowed the differentiation of bullous pemphigoid from other subepidermal bullous diseases. Opportunely we review the clinical, immunological, therapeutic and prognostic features of this pathology in children.

**Keywords:** Child; Collagen type IV; Pemphigoid, bullous; Skin diseases, vesiculobullous

**Resumo:** O penfigoide bolhoso é uma dermatose bolhosa autoimune subepidérmica, incomum na infância. Relatamos um caso de lactente feminina, com 3 meses de idade, que apresentou dados clínicos e laboratoriais confirmatórios para o diagnóstico de penfigoide bolhoso. Os autores utilizaram a coloração de imuno-histoquímica para o colágeno tipo IV que permitiu a diferenciação do penfigoide bolhoso de outras buloses subepidérmicas. Oportunamente, revisamos as características clínicas, imunológicas, terapêuticas e prognósticas da patologia na criança.

**Palavras-chave:** Colágeno Tipo IV; Criança; Dermatopatias vesiculobolhosas; Penfigóide bolhoso

### INTRODUCTION

Bullous pemphigoid (BP) is an acquired disease that belongs to the group of autoimmune subepidermic bullous disorders. It features circulating autoantibodies against distinctive skin's basal membrane antigens and adjacent mucous membrane's antigens.<sup>1-6</sup> Its incidence increases with age, contrary to almost all of the autoimmune disorders.<sup>1</sup> It is uncommon for the disease to begin during childhood and even more so during infancy.<sup>1,2,7,8-12</sup>

PB has a polymorphic clinical presentation. Vesicles and blisters arise on erythematous or apparently healthy skin combined with pruriginous, erythematous infiltrated papules and plaques with irregular borders, annular and polycyclic configurations (sometimes similar to erythema multiforme), which may

precede or coexist with blisters.<sup>1,2,4,6,11,12,13</sup> Blisters are tight, with variable size, usually symmetrical and ungrouped, with serous and / or hemorrhagic contents.<sup>2</sup> They are located primarily on flexural areas of the limbs, trunk and abdomen. Face, head and neck are often affected.<sup>1,2,6,8,11,12,13</sup> Itching is characteristic. Nikolsky sign is negative.<sup>1</sup> Diagnosis is based on clinical, histopathological and immunofluorescence exams, particularly DIF (direct immunofluorescence) and salt-split skin technique, traditionally used to differentiate BP from other immune subepidermal bullous diseases.<sup>1,2,6,11,14</sup>

The clinical, histopathological and immunopathologic characteristics of this disease during childhood overlap with those in the adult form.<sup>5,7,8</sup>

Received on 17.12.2012.

Approved by the Advisory Board and accepted for publication on 04.01.2013.

\* Work performed at Asa Norte Regional Hospital (HRAN) - Brasília (DF), Brazil.

Financial Support: None

Conflict of Interest: None

<sup>1</sup> MD, Board certified dermatologist - Professor of dermatology at Brasilia Catholic University (UCB). Dermatologist at the Distrito Federal Health State Secretariat (SES-DF) - Brasília (DF), Brazil.

<sup>2</sup> MD - Resident in Dermatology at Asa Norte Regional Hospital (HRAN) - Brasília (DF), Brazil.

<sup>3</sup> MD, Board certified dermatologist. Preceptor of the Dermatology Residency Program at Asa Norte Regional Hospital (HRAN) - Brasília (DF), Brazil.

<sup>4</sup> MD, PhD in Dermatology at Rio de Janeiro Federal University (UFRJ) - Chief of the Dermatology Service at Asa Norte Regional Hospital (HRAN) - Brasília (DF), Brazil.

However, some peculiarities are present in childhood BP, such as preferential involvement of palmoplantar regions, oral and genital mucosae and face.<sup>3,4,7,8,11,13,15</sup> Bullous pemphigoid during childhood has a benign, self-limited evolution, with good response to treatment with corticosteroids, lower recurrence rates and better prognosis when compared to the adult form.<sup>8,13</sup>

**CLINICAL CASE**

White infant female, three months and fifteen days old, developed multiple tight bullae five days ago, initially on palms and soles, with progressive involvement of trunk, limbs and head, accompanied by papules and plaques associated or not to blisters. Parents were not consanguineous, denied fever or use of medications, as well as other comorbidities. Personal and family history of atopy, other cutaneous diseases or autoimmune disorders was negative. The patient was born vaginally, at term, without complications. Exclusively breastfed. The patient received the recommended vaccines, with the last dose about 45 days previously.

Dermatological examination revealed the presence of multiple vesicles and widespread tight blisters with serous content and in different sizes, affecting areas of normal as well as erythematous skin. She presented serohemorrhagic crusts, papules and annular urticarial erythematous plaques, some topped by vesicles and blisters. Lesions were located predominantly in the hands, feet, scalp, limbs, trunk and back. There were no mucosal lesions. Nikolsky sign was negative (Figures 1 to 6). Complete blood count showed mild anemia (hemoglobin: 10.8 g / dL), eosinophilia (2,300 eosinophils/mm<sup>3</sup> or 26% of total leukocytes) and thrombocytosis (585,000 platelets). Histopathology showed spongiotic dermatitis with subepidermal bullae rich in neutrophils and eosinophils. DIF detected the presence of linear IgG and C3 deposits along the subepidermal basal membrane zone. Immunohistochemical staining for type IV collagen was positive at the base of the blister, demonstrating that cleaving occurred above the lamina densa. Salt-split skin technique and IIFs (indirect immunofluorescence) could not be performed. (Figures 7 to 10)

The set of clinical and laboratory data confirmed the diagnosis of infantile bullous pemphigoid. Treatment was started with prednisolone 1mg/kg. After five days, due to partial response, the dose of prednisolone was increased to 2mg/kg/day. Reassessment after fifteen days showed good control of the lesions, with only sparse escape blisters. Vaccinations were suspended on account of the immunosuppressive doses of corticosteroids. In order to permit corticosteroid weaning, dapsons was initiated at 0.5 mg / kg. Previous control exams had shown

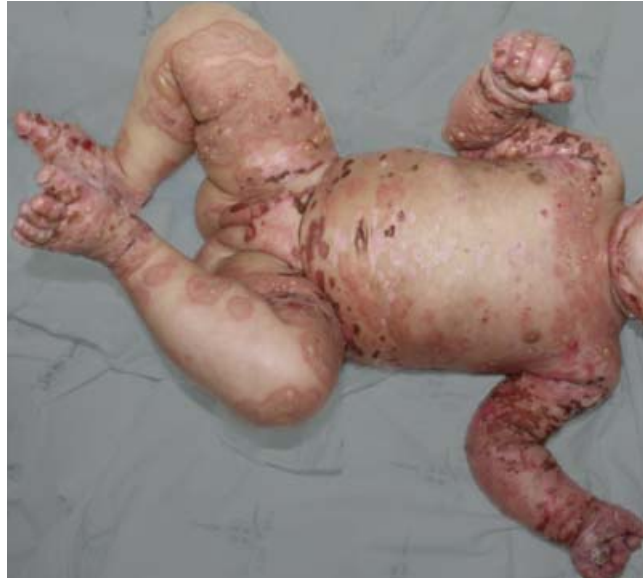

FIGURE 1: Presence of multiple tight, widespread vesicles in areas of normal and erythematous skin

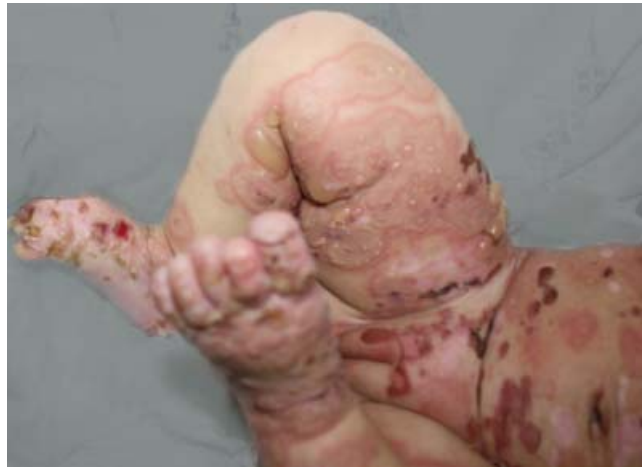

FIGURE 2: Detail of the right thigh with annular pruriginous erythematous plaques, some topped by blisters and tight vesicles

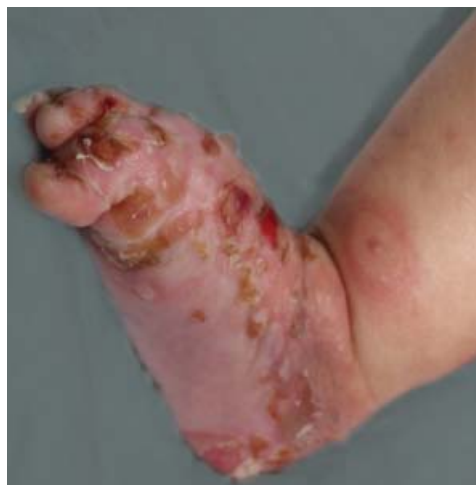

FIGURE 3: Detail of the left foot with serohemorrhagic crusts



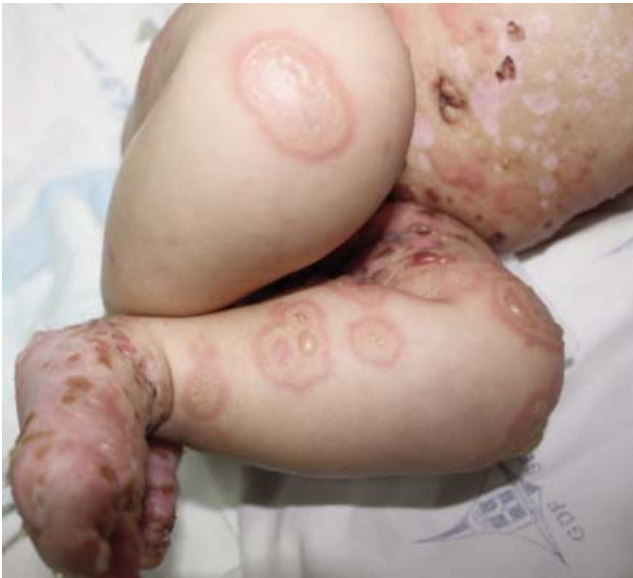

FIGURE 4: Detail of the lower limbs with erythematous urticariform plaques topped by blister and vesicles

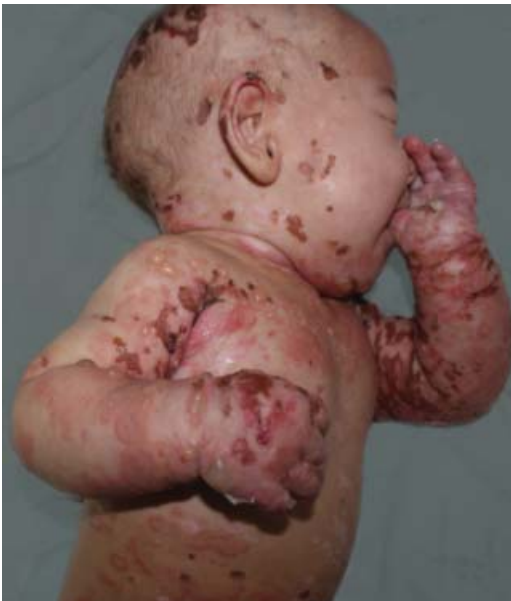

FIGURE 5: Detail of superior trunk and limbs

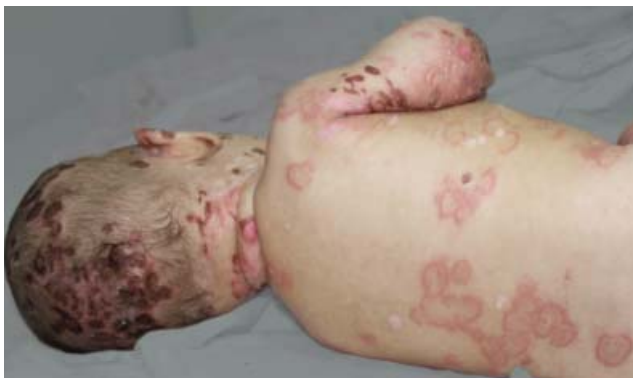

FIGURE 6: Detail of the trunk with early lesions, and head with sero-hemorrhagic crusts

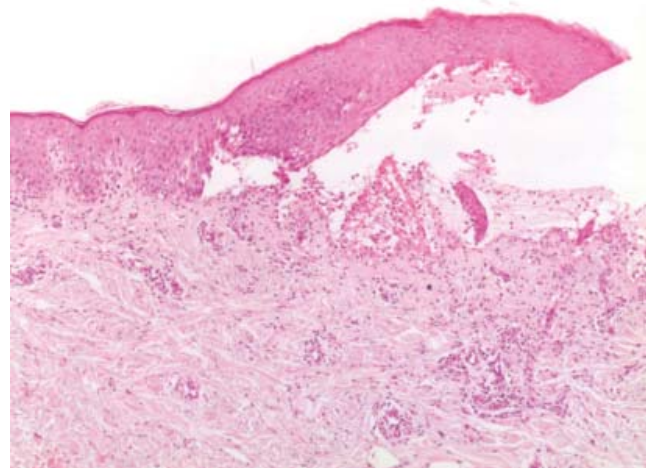


FIGURE 7: HE 10x: Spongiotic dermatitis with presence of subepidermal blister rich in neutrophils and eosinophils

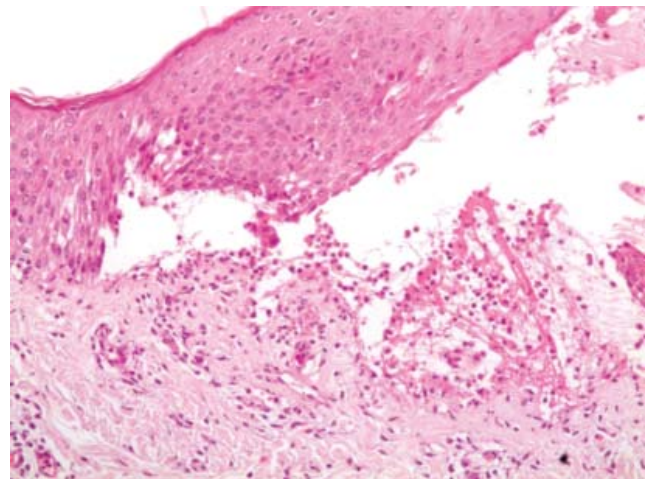


FIGURE 8: HE 40x: Detail of subepidermal blister rich in neutrophils and eosinophils

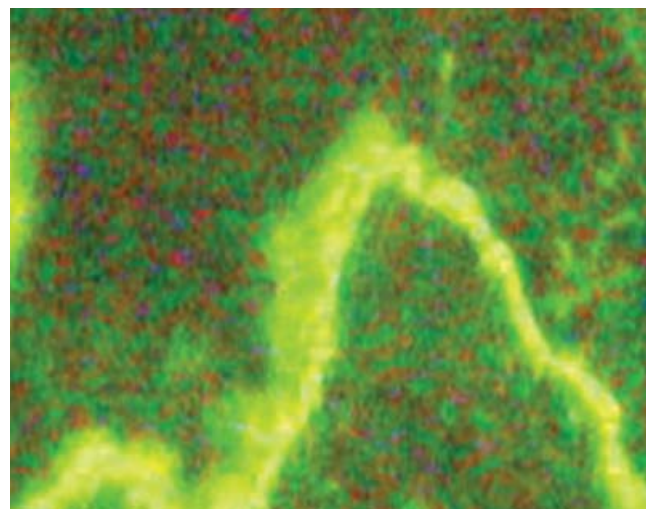
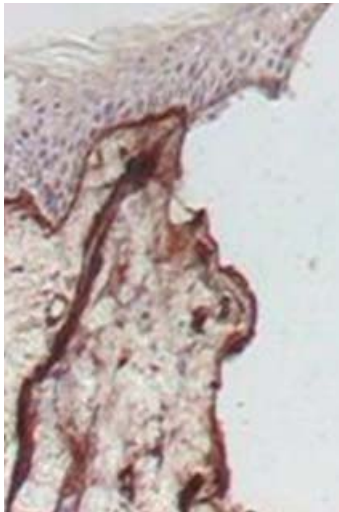

FIGURE 9: DIF: Positive reaction for IgG in subepidermal basal membrane zone



**FIGURE 10:** Cryostat section with immunohistochemical reaction for type IV collagen showing positivity on the base of the blister

normal G6PD levels and no subsequent worsening of anemia occurred with medication. Corticosteroid therapy was reduced by 0.5 mg / kg every two weeks until its full suspension, while dapsone was maintained at 0.5 mg / kg / day. Patient remained without skin lesions for three months, and resumed the use of vaccines without live antigens according to the national vaccination calendar. At nine months old, she received acellular conjugated vaccines (DTPA), anti hepatitis B, polio and meningococcal diseases, with subsequent display of new bullous lesions. Dapsone was increased to a dose of 1mg/kg and prednisolone 1mg/kg was initiated for a week. With regression of the clinical symptoms dapsone was maintained for six months in which period no new lesions appeared, even with the use of vaccines, so, the medication was discontinued. The patient is followed-up in the outpatient dermatology service, and she has been lesion-free for six months without any signs of recurrence to date.

## DISCUSSION AND CONCLUSION

The precise incidence of bullous pemphigoid in children and other bullous dermatoses in childhood are unknown.<sup>4,7,13</sup> The first case of juvenile BP confirmed by immunofluorescence was published in 1970.<sup>7</sup> Since then, there has been a notable increase in published cases; currently there are just under 100 cases reported in childhood, a dozen in infants.<sup>7,8</sup>

In BP, there is concrete evidence that circulating antibodies have a key role in disease pathogenesis, reacting against epidermic basal membrane antigens, proteins BP180 antigen (antigen-2 BP) and BP230 antigen (antigen-1 BP) causing tissue injury.<sup>1,2,6,8,16</sup> These proteins are components of adhesion junctional complexes, or hemidesmosomes, expressed in stratified epithelia.<sup>1</sup>

Bullous pemphigoid can simulate various dermatoses and be clinically indistinguishable from other bullous diseases of childhood, such as dermatitis herpetiformis, acquired epidermolysis bullosa, bullous

systemic lupus erythematosus or linear IgA bullous dermatosis. Besides medical history, physical examination and histopathological analysis, we use tests such as immunofluorescence, indirect immunofluorescence (with salt-split skin technique), immunoblotting and ELISA for diagnosis.<sup>1,11,13,17,18,19,20</sup>

In this case, the question is whether the prior administration of vaccines did act as a trigger for the formation of autoantigens against the basal membrane.<sup>7,21</sup> It is suggested that, in these cases, induced BP occurs through modulation of immunity.<sup>7</sup> The vaccine could unmask a subclinical BP inducing a nonspecific immune reactivation in genetically predisposed individuals.<sup>10</sup> However, the true role of vaccine antigens in the emergence of the BP is still questioned.<sup>10,15</sup>

The interruption of vaccination in children who have post-vaccination BP is not recommended.<sup>7</sup> In the patient described here, vaccinations were discontinued during the period of immunosuppressive dose of prednisolone and resumed when the dose was 0.5 mg / kg / day.

Palmoplantar lesions are typical of childhood BP, especially in children under one year, and these were the initial lesions in the case reported. The widespread involvement predominates in infants. There were no mucosal lesions in our case, those being most commonly found in children older than 1 year.<sup>11,15,18,21</sup> Such differences in BP clinical features among infants and older children do not have defined pathogenesis, but may be explained by differences in the expression of BP antigens according to age.<sup>5,15</sup> There is no difference in the prognosis or treatment.

The clinical, histopathological, DIF and IIF aspects of bullous pemphigoid can also be observed in epidermolysis bullosa acquisita (EBA), another subepidermal bullous disease.<sup>14</sup> To differentiate them, we can use immunofluorescence with salt-split skin technique. In EBA and bullous systemic lupus erythematosus, IgG deposits are only found on the dermal side of the cleft (base of the blister), while in bullous pemphigoid deposits occur in the epidermal side (top of the blister) or, more rarely, on both sides, since the main BP antigens are in the upper portion of the lamina lucida.<sup>1,6,10,11,13,14,20</sup>

In the case described here, we performed a low-cost method that determined the location of target autoantigens. The authors used a simple staining immunohistochemistry exam for type IV collagen in skin biopsies embedded in paraffin, allowing the differentiation of bullous pemphigoid from other subepidermal bullous diseases. The advantage of this method is that it is not necessary to perform new immunofluorescence reactions, with another sets of costs and techniques.<sup>4,22,23</sup> Type IV collagen is a component of the lamina densa that in bullous pemphigoid will be detected in the base of the blister, since autoantibodies against antigens BP180 antigen (antigen-2



PB) and BP230 antigen (antigen-1 PB) are located on hemidesmosomes plates, above the lamina densa. EBA, characterized by autoantibodies against type VII collagen present in the sublamina densa region, will have type IV collagen highlighted after staining, on the top part of the blister. Therefore, immunohistochemical staining for collagen type IV also aids in the diagnosis of subepidermal bullous diseases.<sup>4,22,23</sup>

BP therapy aims only to alleviate symptoms and shorten the duration of illness.<sup>7,8</sup> Classically, the treatment of choice is performed with systemic corticosteroids at a dose of 1 to 2 mg/kg/day of prednisone, only enough to control the disease, and not to completely suppress the lesions.<sup>3,4,6,7,9,11,15</sup> Oral corticosteroids are generally well tolerated by children, and healing occurs after a few weeks or months of treatment.<sup>7</sup> The systemic corticoid may be associated with dapsona, 1mg/kg/day, aiming at later reduction of the corticoid dose while continuing with sulfone, as described in the reported case.<sup>6,20</sup>

Contrary to what is observed in adults, the prognosis of BP in children is good because its clinical course is benign and self-limited, and lesions regress in one year or less, with rare cases lasting two years or more.<sup>4,5,10,11,13,15,18</sup> As there is a possibility of spontaneous remission in childhood; treatment should not be aggressive or too

toxic.<sup>9</sup> The occurrence of relapses is infrequent.<sup>10</sup>

This disorder, although rare, should always be among the differential diagnosis of bullous dermatoses in infants and children, especially in cases of palmar-plantar involvement, in which the lesions are tight, wide and with an erythematous base.<sup>7,8,11,21</sup> The more precise knowledge of PB's pathophysiology can incite the development of new immunomodulatory target specific treatments, with fewer side effects than the traditional treatments.<sup>1</sup> The clinical aspects, diagnosis, treatment and management of cases can be challenging, so caution is advisable in these circumstances.<sup>1,10</sup> This case confirmed most of the characteristics reviewed in the literature and had an excellent response to conventional therapy, achieving remission within the usual time frame. □

#### ERRATA

There is a mistake in the dapsona dosage on page 965, in the last phrase of first column, v.88, n.6 of article "Bullous pemphigoid in a 3-month-old infant: case report and literature review of this dermatosis in childhood". The phrase should read as follows: "The systemic corticoid may be associated with dapsona, 1mg/kg/day, aiming at later reduction of the corticoid dose while continuing with sulfone, as described in the reported case."

#### REFERENCES

- Schmidt E, della Torre R, Borradori L. Clinical features and practical diagnosis of bullous pemphigoid. *Immunol Allergy Clin North Am.* 2012;32:217-32.v.
- Di Zeno G, Della Torre R, Zambruno G, Borradori L. Bullous pemphigoid: From the clinic to the bench. *Clin Dermatol.* 2012;30:3-16.
- Oranje AP, Vuzevski VD, van Joost T, ten Kate F, Naafs B. Bullous pemphigoid in children. Report of three cases with special emphasis on therapy. *Int J Dermatol.* 1991;30:339-42.
- Nemeth AJ, Klein AD, Gould EW, Schachner LA. Childhood bullous pemphigoid. Clinical and immunologic features, treatment, and prognosis. *Arch Dermatol.* 1991;127:378-86.
- Hafiji J, Bhogal B, Rytina E, Burrows NP. Bullous pemphigoid in infancy developing after the first vaccination. *Clin Exp Dermatol.* 2010;35:940-1.
- Cunha PR, Barraviera SR. Autoimmune bullous dermatoses. *An Bras Dermatol.* 2009;84:111-24.
- Barreau M, Stefan A, Brouard J, Leconte C, Morice C, Comoz F, Verneuil L. Infantile bullous pemphigoid. *Ann Dermatol Venereol.* 2012;139:555-8.
- Sousa B, Mota A, Morgado H, Lopes JM, Dias JA. Bullous pemphigoid in an infant. *Acta Med Port.* 2005;18:159-62.
- Gajic-Veljić M, Nikolic M, Medenica L. Juvenile bullous pemphigoid: the presentation and follow-up of six cases. *J Eur Acad Dermatol Venereol.* 2010;24:69-72.
- Majmudar V, Herath D, O'Toole EA, Harrison A. Bullous pemphigoid of childhood: a rare disease with diagnostic and management challenges. *Clin Exp Dermatol.* 2010;35:213-4.
- Sáenz AM, González F, Cirocco A, Tacaronte IM, Fajardo JE, Calebotta A. Childhood bullous pemphigoid: a case report and 10-year follow up. *Int J Dermatol.* 2007;46:508-10.
- Kneisel A, Hertl M. Autoimmune bullous skin diseases. Part 1: Clinical manifestations. *J Dtsch Dermatol Ges.* 201;9:844-56
- Lara-Corralles I, Pope E. Autoimmune Blistering Diseases in Children. *Semin Cutan Med Surg.* 2010;29:85-91.
- De A, Rao R, Balachandran C. Salt split technique: a useful tool in the diagnosis of subepidermal bullous disorders. *Indian J Dermatol.* 2010;55:334-6.
- Waisbourd-Zinman O, Ben-Ami D, Cohen AD, Feinmesser M, Mimouni D, Adir-Shani A, et al. Bullous pemphigoid in infancy: clinical and epidemiologic characteristics. *J Am Acad Dermatol.* 2008;58:41-8.
- Fania L, Caldarola G, Müller R, Brandt O, Pellicano R, Feliciani C, et al. IgE recognition of bullous pemphigoid (BP)180 and BP230 in BP patients and elderly individuals with pruritic dermatoses. *Clin Immunol.* 2012;143:236-45.
- Tampoia M, Giavarina D, Di Giorgio C, Bizzaro N. Diagnostic accuracy of enzyme-linked immunosorbent assays (ELISA) to detect anti-skin autoantibodies in autoimmune blistering skin diseases: A systematic review and meta-analysis. *Autoimmun Rev.* 2012;12:121-6.
- Quattrino AL, Silveira JCGS, Kawakubo SW, Xavier V, Rochael MC. Bullous pemphigoid in childhood. *An Bras Dermatol.* 2007;82:87-9.
- Martinez-De Pablo MI, González-Enseñat MA, Vicente A, Gilaberte M, Mascaró JM Jr. Childhood Bullous Pemphigoid: Clinical and Immunological Findings in a Series of 4 Cases. *Arch Dermatol.* 2007;143:215-20.
- Zanella RR, Xavier TA, Tebcherani AJ, Aoki V, Sanchez APG. Bullous pemphigoid in younger adults: three case reports. *An Bras Dermatol.* 2011;86:355-8.
- Amos B, Deng JS, Flynn K, Suarez S. Bullous pemphigoid in infancy: case report and literature review. *Pediatr Dermatol.* 1998;15:108-11.
- Olivry T, Dunston SM. Usefulness of collagen IV immunostaining for diagnosis of canine epidermolysis bullosa acquisita. *Vet Pathol.* 2010;47:565-8
- Abreu-Velez AM, Howard MS. Collagen IV in Normal Skin and in Pathological Processes. *N Am J Med Sci.* 2012;4:1-8.

#### MAILING ADDRESS:

Eugenio Galdino de Mendonça Reis-Filho  
Setor Medico Hospitalar Norte, Quadra 101 - Asa Norte  
70710-100 - Brasília - DF  
Brazil  
E-mail: eugeniodermato@gmail.com

How to cite this article: Reis-Filho E, Silva TA, Aguirre LHL, Reis CMS. Bullous pemphigoid in a 3-month-old infant: case report and literature review of dermatoses in childhood. *An Bras Dermatol.* 2013;88(6):961-5.