

Vulvoperineal Crohn's disease responsive to metronidazol*

Doença de Crohn vulvoperineal responsiva ao metronidazole

Aristóteles Rosmaninho¹
Rosário Alves¹

Madalena Sanches²
Manuela Selores⁴

Marta Salgado³

DOI: <http://dx.doi.org/10.1590/abd1806-4841.20132243>

Abstract: Crohn's disease is a multisystem chronic granulomatous inflammatory disease that primarily affects the gastrointestinal tract. In the majority of the cases, the cutaneous manifestations follow the intestinal disease, but occasionally dermatological lesions are the inaugural event and may constitute the only sign of the disease. Vulvoperineal involvement is rare, may precede bowel symptoms by months to years and may go unrecognized. Due to the paucity of reports of Crohn's disease at this location and in the absence of randomized trials, there are no standard treatments for the cutaneous disease. We describe the case of a 47 year-old woman with vulvoperineal Crohn's disease without digestive involvement, that was successfully managed with metronidazole.

Keywords: Crohn disease; Metronidazole; Therapeutics

Resumo: A doença de Crohn é uma doença granulomatosa multissistêmica inflamatória crônica que afecta primariamente o tracto gastrointestinal. Na maioria dos casos, as manifestações cutâneas sucedem a doença intestinal, mas, ocasionalmente, as lesões dermatológicas são o primeiro evento e podem constituir o único sinal da doença. O envolvimento vulvoperineal é raro, pode preceder os sintomas intestinais em meses ou anos, e pode passar despercebido. Devido à escassez de relatos de doença de Crohn com esta localização e na ausência de ensaios clínicos randomizados, não há nenhum tratamento padrão para a doença cutânea. Descrevemos um caso de uma mulher de 47 anos com doença de Crohn vulvoperineal sem envolvimento digestivo, que foi tratada com sucesso com metronidazol.

Palavras-chave: Doença de Crohn; Metronidazol; Terapêutica

INTRODUCTION

Crohn's disease is a multisystem chronic granulomatous inflammatory disease that primarily affects the gastrointestinal tract. In the majority of cases, cutaneous manifestations follow the intestinal disease, but occasionally dermatological lesions are the inaugural event and may constitute the only sign of the disease. Vulvoperineal involvement is rare, may precede bowel symptoms by months to years and may go unrecognized. Due to the paucity of reports of Crohn's disease at this location and in the absence of randomized trials, there are no standard treatments

for the cutaneous disease. Numerous therapies (including surgery, use of antibiotics and immunosuppression) have been used with variable results. There are only anecdotal reports that support the use of metronidazole. We describe a case of a 47 year-old woman with vulvoperineal Crohn's disease without digestive involvement that was successfully managed with metronidazole and without side effects. Oral metronidazole seems to be effective in the treatment of vulvoperineal Crohn's disease and cutaneous flares also respond rapidly to repeated treatment.

Received on 21.11.2012.

Approved by the Advisory Board and accepted for publication on 11.01.2013.

* Work performed at the Dermatology Service; Hospital de Santo António - Hospital Center at Porto, E.P.E - Porto, Portugal.

Financial Support: none

Conflict of Interests: none

¹ MD - Hospital Assistant of Dermatovenereology at the Hospital de Santo António - Hospital Center at Porto, E.P.E - Porto, Portugal.

² MD - Graduate Assistant of Dermatovenereology at the Hospital de Santo António - Hospital Center at Porto, E.P.E - Porto, Portugal.

³ MD - Hospital Assistant of Gastroenterology at the Hospital de Santo António - Hospital Center at Porto, E.P.E - Porto, Portugal.

⁴ MD - Director of the Dermatovenereology Service at the Hospital de Santo António - Hospital Center at Porto, E.P.E - Porto, Portugal.

CASE REPORT

A 47-year-old woman presented for evaluation of multiple persistent painful vulvoperineal lesions that had appeared in the last 5 years. She went on several antibiotic courses without any improvement. She denied bowel complaints or weight loss. Her past medical history was only remarkable for hypertension. On physical examination, an exuberant inflammation of the vulva with aftoid ulcers of the labia minor and majora, and linear ulcerations in the inguocrural folds were observed. A deep linear fissure above the clitoris and a "knife-cut" ulcer with sharp margins on the buttocks fold were also present (Figure 1). A skin biopsy revealed an ulcerated epidermis with a fistulous tract and aspects of chronic inflammation with lymphocytes, histiocytes and multinucleated giant cells in a non-caseating granulomatous pattern on the dermis (Figure 2). Fungal and mycobacterial elements were not detected by histology or in tissue culture. Laboratory investigations were normal except for C-reactive protein of 41 mg/dl

(<5). Syphilis, HIV serologies and Mantoux test were negative. PCR testing for herpes simplex virus was negative. Chest X-ray showed no abnormalities. Based on the clinical and histological findings a vulvoperineal cutaneous Crohn's disease (CD) diagnosis was made. The patient was referred to gastroenterology for evaluation of bowel involvement. Endoscopic studies of the digestive tract and biopsies from the ileum, colon and rectum showed no abnormalities, so that a diagnosis of vulvoperineal cutaneous CD without digestive involvement was assumed. The patient went on daily metronidazole (1000 mg) and ciprofloxacin (1000 mg) with a striking improvement. Antibiotherapy was discontinued at 3 months and azathioprine (50 mg daily) was introduced. However, the condition worsened and metronidazole (1000 mg daily) was added to azathioprine and marked improvement was observed after 12 days. At 2 months of combined therapy (metronidazole 1000 mg plus azathioprine 150 mg daily) sustained clinical improvement was observed (Figure 3).

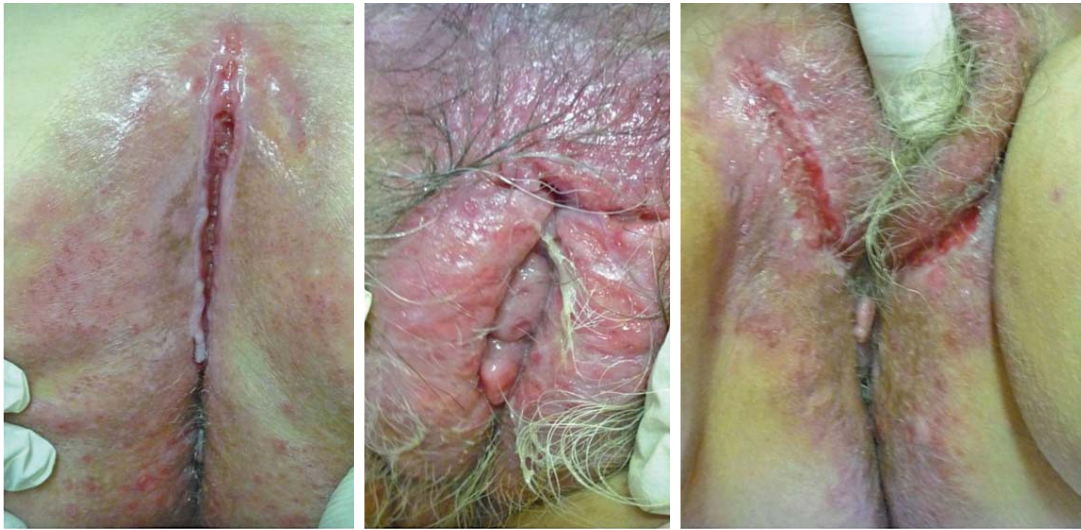

FIGURE 1: Clinical findings at presentation

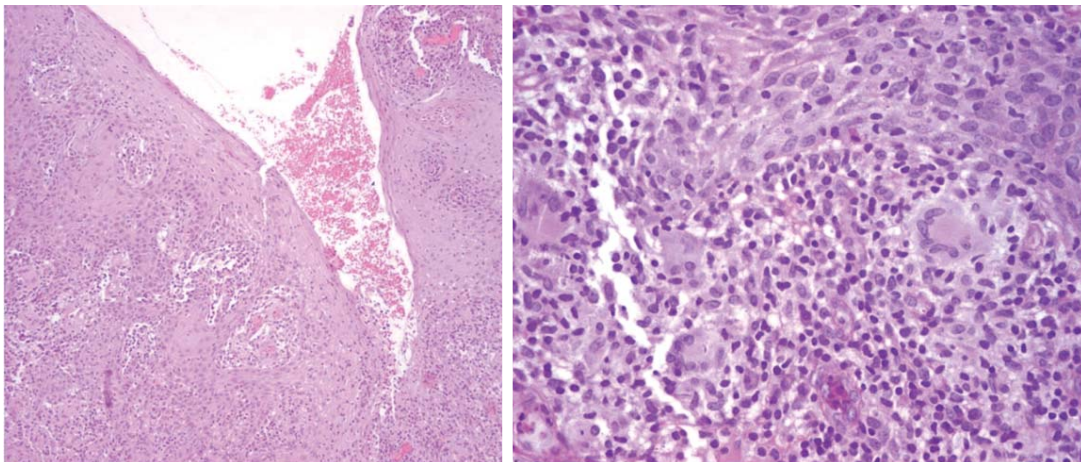


FIGURE 2: H&E (10x): ulcerated epidermis with a fistulous tract (left). PAS (40x): aspects of chronic inflammation in a granulomatous pattern in the dermis (right)

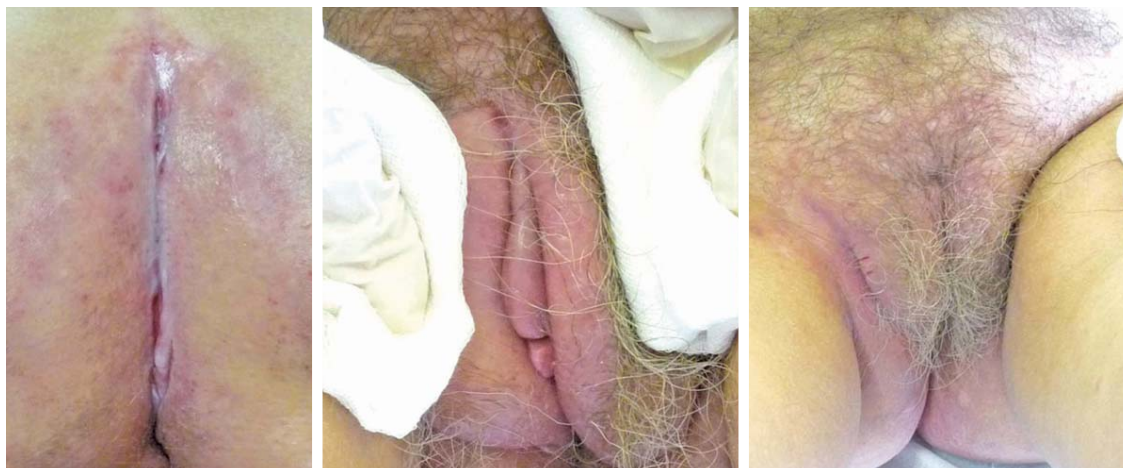

FIGURE 3: Clinical improvement with metronidazole and azathioprine at 2 months of therapy

DISCUSSION

In CD the mucocutaneous lesions usually follow the intestinal disease and exceptionally occur prior to bowel involvement.¹ In the latter case, a high index of suspicion may be required to reach the accurate diagnosis. Most of the lesions are a result of direct extension of the intestinal disease (perineal abscesses and fistula) and more rarely they occur in a noncontiguous extraintestinal spread (metastatic CD). Genitalia involvement in CD is rare.^{2,3} Andreani *et al*, reported that 25% of vulvar CD did not have any previous intestinal symptoms and patients had not been diagnosed as having CD.² Vulvar swelling, erythema and pain that evolve to vulvar hypertrophy, ulceration and abscesses are the typical clinical picture. "Knife-cut" ulcers (as in our case) are almost pathognomonic of CD, although they have been described in cutaneous tuberculosis and herpetic infections in immunocompromised patients.³ The histological examination characteristically shows non-caseating granulomas. The differential diagnoses include other granulomatous diseases that can cause vulvar ulceration such as sarcoidosis, tuberculosis, fungal infections, lymphogranuloma venereum, granuloma inguinale and actinomycosis. Sometimes pyoderma gangrenosum can clinically mimic cutaneous Crohn's disease. Ruling out infections usually requires bacteriological and mycological workup. Due to a paucity of reports with this topography the treatment remains nonstandardized.⁴ Several medical treatments for cutaneous disease have been proposed with variable

results and include: topical, intralesional and systemic corticosteroids, sulfasalazine, azathioprine, cyclosporine, methotrexate, thalidomide, metronidazole, infliximab, adalimumab and surgical excision. Only few small studies and anecdotal reports have evaluated the use of metronidazole.^{2,3,4-7} As supported by our case, it seems to be effective with resolution of almost all the lesions. In combination with oral corticotherapy a success rate of 87.5% has been reported.² Its efficacy is probably due to its anti-inflammatory, antibacterial and immunosuppressive action.⁴ In the study of Brandt LJ *et al*, the lesions of all 26 patients with perineal CD cleared, and an optimal dose of 20 mg/kg/day for 12 to 36 months was required.⁸ The tapering of this dose often leads to recurrences, however cutaneous lesions promptly respond to repeated treatment with the drug.^{5,8} Reversible paresthesia is the major complication reported with long-term metronidazole therapy.⁴ Minor complications include a metallic taste and darkening of the urine together with gastrointestinal upset. In our patient the treatment was well-tolerated without any side effects. We report an extremely atypical presentation of CD that was successfully managed with metronidazole with no significant adverse effects. Physicians should be aware of such presentation as it may precede gastrointestinal involvement and be a cause of high morbidity if not promptly recognized. □

REFERENCES

1. Eames T, Landthaler M, Karrer S. Crohn's disease: an important differential diagnosis of granulomatous skin diseases. *Eur J Dermatol.* 2009;19:360-4.
2. Andreani SM, Ratnasingham K, Dang HH, Gravante G, Giordano P. Crohn's disease of the vulva. *Int J Surg.* 2010;8:2-5.
3. Madnani NA, Desai D, Gandhi N, Khan KJ. Isolated Crohn's disease of the vulva. *Indian J Dermatol Venereol Leprol.* 2011;77:342-4.
4. Khaled A, Ezzine-Sebai N, Faza'a B, Zeglaoui F, Zermani R, Kamoun MR. Vulvoperineal Crohn's disease: response to metronidazole. *Skinmed.* 2010;8:240-1.
5. Abide JM. Metastatic Crohn disease: clearance with metronidazole. *J Am Acad Dermatol.* 2011;64:448-9.
6. Thukral C, Travassos WJ, Peppercorn MA. The role of antibiotics in inflammatory bowel disease. *Curr Treat Options Gastroenterol.* 2005;8:223-8.
7. Fernandes MD, Fernandes HD, Deliza R, Pires CE, Bortoncello AC. Metastatic Crohn's disease without intestinal clinical manifestation. *An Bras Dermatol.* 2009;84:651-4.
8. Brandt LJ, Bernstein LH, Boley SJ, Frank MS. Metronidazole therapy for perineal Crohn's disease: a follow-up study. *Gastroenterology.* 1982;83:383-7.

MAILING ADDRESS:

*Aristóteles Rosmaninho
Rua D. Manuel II, s/nº
Edifício da Consultas Externas
4099-001 - Porto - Portugal
E-mail: arisrosmaninho@gmail.com*

How to cite this article: Rosmaninho A, Sanches M, Salgado M, Alves R, Selores M. Vulvoperineal Crohn's disease responsive to metronidazole. *An Bras Dermatol.* 2013;88(6 Suppl 1):S71-4.