

LETTERS ▼

Undifferentiated pleomorphic sarcoma*

Ana Carolina Gonçalves de Paiva^{1,2}
 Marilda Aparecida Milanez Morgado de Abreu^{1,2}
 Marcela Pesce de Souza¹

DOI: <http://dx.doi.org/10.1590/abd1806-4841.20186613>

Dear Editor,

By definition, sarcomas are malignant tumors of tissues, derived from mesoderm and involve the oncogenic transformation of mesenchymal stem cells. The two main types of sarcoma are bone and soft tissue sarcomas. Soft tissue sarcomas generally manifest as deep lesions, but they may affect the skin and subcutaneous tissue.¹ They are grouped according to similarities in their clinical presentation and histopathological appearance. However, they have different cellular origins.²

Undifferentiated pleomorphic sarcoma is a tumor whose histogenesis is not yet clearly defined.¹ We describe a case of undifferentiated pleomorphic sarcoma with cutaneous presentation and review some aspects of the disease, describing the main differential diagnoses and the clinical and histopathological findings of this rare tumor in its exuberant form, based on the current literature. We report the case of a 74-year-old male patient who sought treatment due to a rapid-onset skin lesion in the thoracic region after two months of disease evolution. He denied having any associated systemic symptoms. Dermatological examination revealed a vegetative and ulcerated tumor, friable, measuring 6cm in diameter, located in the right upper thoracic area (Figure 1). The patient underwent surgery with complete resection of the lesion and wide safety margins (Figure 1).²

Histopathological examination associated with immunohistochemical (IHC) profile (Vimentin and CD68 positive) were compatible with undifferentiated pleomorphic sarcoma (malignant fibrous histiocytoma), but negative for other markers, such as high molecular weight cytokeratin, CD45, S100 protein, MELAN-A, HMB45, CD56, CD24, desmin, CD31, and Bcl2, which excluded other cancers, such as amelanotic melanoma, Merkel cell carcinoma, and lymphoma (Figure 2). The patient was referred to the oncology

department for staging. Imaging tests showed no signs of metastatic disease. He is in outpatient follow-up without signs of lesion recurrence. The reclassification of soft tissue sarcomas based on the 2002 World Health Organization requires the identification of the lineage of origin for the categorization of the tumor.¹

In many cases, a careful and detailed immunohistochemical and ultrastructural evaluation leads to the possible or conclusive classification of the tumor into the histogenetic subtypes of sarcoma.² With the most current classification in mind, two tumors are most likely to affect the skin: undifferentiated pleomorphic sarcoma (formerly storiform-pleomorphic malignant fibrous histiocytoma) and myxofibrosarcoma (formerly myxoid malignant fibrous histiocytoma).³ Both tumors are more common in the elderly and may present themselves as a subcutaneous mass, more commonly affecting the limbs.⁴ In the skin, they usually present themselves as skin-colored nodules, ranging in texture from elastic to firm. Their growth is sometimes fast.¹ Clinically and histopathologically, they may resemble malignant melanoma, squamous cell carcinoma,

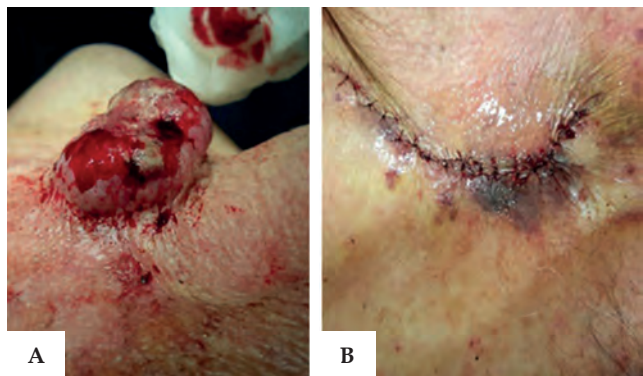


FIGURE 1: A - 6 cm-diameter tumor. B - Immediate postoperative period

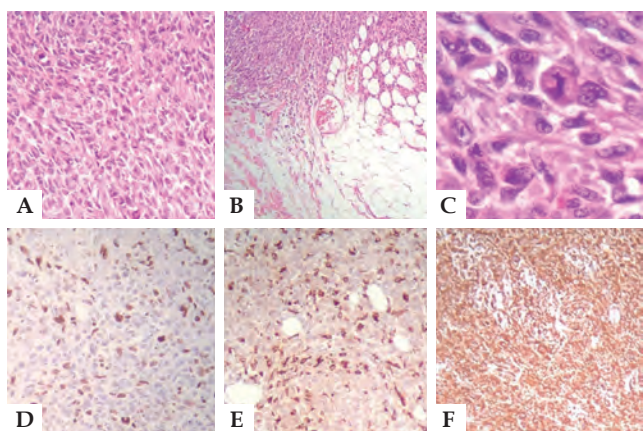


FIGURE 2: A: Intense proliferation of pleomorphic cells in the dermis (Hematoxylin & eosin, X200); B: Infiltration of adipose tissue with neovascularization (Hematoxylin & eosin, X100); C: Fusiform and polygonal pleomorphic multinucleated cells with hyperchromasia of the nucleoli and mitotic figures (Hematoxylin & eosin, X400); D: Immunohistochemistry 90% highly positive for Ki-67 antibody, a cell proliferation marker, CD-68; E: A macrophage marker (IHC, X200); and F: Vimentin, a mesenchymal cell marker, IHC X100).

Received on 16.10.2016.

Approved by the Advisory Board and accepted for publication on 18.07.2017.

* Work performed at Dermatology Service, Hospital Regional de Presidente Prudente - Universidade do Oeste Paulista (Unoeste) - Presidente Prudente (SP), Brazil.

Financial support: None.

Conflict of interests: None.

¹ Dermatology Service, Hospital Regional de Presidente Prudente - Presidente Prudente (SP), Brazil.

² Discipline of Dermatology, Universidade do Oeste Paulista (Unoeste) - Presidente Prudente (SP), Brazil.

MAILING ADDRESS:

Ana Carolina Gonçalves de Paiva
 E-mail: carolina_med21@hotmail.com

©2018 by Anais Brasileiros de Dermatologia



dermatofibrosarcoma protuberans, atypical fibroxanthoma, and leiomyosarcoma.² The extremities are the most common sites of involvement, especially the lower limbs. However, any area of the body can be affected, and approximately 10-15% are located in the tissue of the head and neck.⁵ For diagnosis, histopathology study associated to the immunohistochemistry are necessary.⁵ The basis of treatment is total surgical resection of the tumor with wide safety margins. An adjuvant radiotherapy is important to improve local control, especially in high-grade lesions and in patients with compromised surgical margin after broad excision. Even 50% of cases show distant metastasis (usually lung and lymph nodes) with common recurrence.¹ □

REFERENCES

1. Tupinambá WL, Schettini RA, Souza Júnior J, Schettini APM, Rodrigues CAC, Oliveira FS. Mixofibrossarcoma: relato de caso. *An Bras Dermatol.* 2011;86:S110-3.
2. Siqueira RC, Jardim ML, Bandeira V, Ferreira RMC, Montenegro LT, Guimarães P, et al. Malignant fibrous histiocytoma of the extremity: a case report. *An Bras Dermatol.* 2004;79:569-73.
3. Srikanth D, Devi V, Polishetty N, Singh D. Subcutaneous Benign Fibrous Histiocytoma: Rare Presentation on Cheek-Case Report and Review of Literature. *J Maxillofac Oral Surg.* 2016;15:282-6.
4. Kim JI, Choi YJ, Seo HM, Kim HS, Lim JY, Kim DH, et al. Case of Pleomorphic Dermal Sarcoma of the Eyelid Treated with Micrographic Surgery and Secondary Intention Healing. *Ann Dermatol.* 2016;28:632-636
5. Fleury Jr LFF, Sanches Jr JA. Sarcomas cutâneos primários. *An Bras Dermatol.* 2006;81:207-21.

How to cite this article: Paiva ACG, Morgado de Abreu MAM, Souza MP. Undifferentiated pleomorphic sarcoma. *An Bras Dermatol.* 2018;93(1):154-5.



Methotrexate-induced mucositis with extra-mucosal involvement after accidental overdose*

Greice Rampon¹

Valéria Magalhães Jorge²

Caroline Henkin¹

Hiram Larangeira de Almeida Jr.³

DOI: <http://dx.doi.org/10.1590/abd1806-4841.20186687>

Dear Editor,

Methotrexate (MTX) in low weekly doses is a first-line therapy for inflammatory diseases, such as moderate to severe psoriasis and rheumatoid arthritis^{1,2} due to its effectiveness, low cost and ease

of use. Severe acute toxicity is rare and presents with mucositis, skin ulceration and pancytopenia.² Factors such as age, drug interaction, individual susceptibility and comorbidities can contribute to the development of toxicity.³ However, the most common cause is a daily accidental ingestion, rather than weekly dose of methotrexate. The regular monitoring and the selection of patients for the use of this medication, appropriate counseling about drug interactions, adverse effects, as well as instructions on self-medication are essential to prevent complications. Misunderstanding about its use may lead to severe toxicity and even death.

A 43-year-old woman recently diagnosed with rheumatoid arthritis has accidentally taken 15 mg of methotrexate daily, rather than weekly, for 9 consecutive days. She developed severe oral mucositis along with papules with central necrosis in the presternal region (Figure 1). Interestingly, areas of pressure were markedly involved (Figure 1). Laboratory tests showed pancytopenia (10.5 Hb, 1.940 leukocytes, 95.000 platelets) and hepatic dysfunction (AST 131 UI, ALT 200 IU). Light microscopy of the oral mucosa and the affected skin showed epidermal basal necrosis with discreet and superficial inflammatory infiltrate (Figure 2). The patient showed significant clinical and laboratory improvement after suspension of medication and replacement of folic acid (Figure 1).

Methotrexate is generally administered once weekly to patients, with doses ranging from 7.5 to 25 mg/week. At the doses typically used, this medication has an anti-inflammatory effect as it increases the levels of intracellular adenosine. When used at high doses in oncology, it has anti-metabolic effects on cells with a high mitotic activity.² Although safe and widely used in low doses, it is not free from side effects, which often lead patients to discontinuing the medication.⁴ The side effects of MTX are mainly gastrointestinal intolerance and hepatotoxicity. Although rare, some severe manifestations have been reported such as cypopenia, mucocutaneous toxicity, pneumonitis, neurotoxicity and nephropathy.⁵ The presence of oral mucositis, cutaneous ulcerations and pancytopenia (which may be followed by sepsis) suggest severe acute toxicity, since the drug inhibits rapid cell turnover.²

Pancytopenia presents within the first 10 days of treatment. It is dose dependent but occasionally it may be idiosyncratic. Mucositis usually occurs within the first 7 days of administration, prior to the onset of pancytopenia, as the accumulation of MTX is higher in mucosal epithelial cells than in the bone marrow stem cells.^{2,4,5} Cutaneous involvement usually appears with mucositis. Its mechanism of action has been associated with direct drug toxicity in epithelial cells², as seen in our patient. Histologically, this toxicity is evidenced by severe keratinocyte necrosis.¹

The most common causes of acute MTX toxicity are dose errors and the concomitant use of medications, such as nonsteroidal anti-inflammatory drugs. Other factors, as renal function impairment, high alcohol intake, infections and advanced age may be involved, but overdose (daily dose instead of weekly dose) was the most common cause of acute MTX toxicity in reported cases.² Prior to starting treatment with MTX, patients should be regularly monitored with renal, liver function tests, complete blood count. The patient's age, the prevalence of comorbidities, the use of medications should be considered. It also requires knowledge of how often and

Received on 10.11.2016.

Approved by the Advisory Board and accepted for publication on 23.01.2017.

* Work performed at the Pontifícia Universidade Católica do Rio Grande do Sul (PUC- RS) and Universidade Federal de Pelotas (UFPEL) - Pelotas (RS), Brazil.

Financial support: None.

Conflict of interest: None.

¹ Dermatology Service, Pontifícia Universidade Católica do Rio Grande do Sul (PUC- RS) - Porto Alegre (RS), Brazil.

² Discipline of Pathology, Universidade Federal de Pelotas (UFPEL) - Pelotas (RS), Brazil.

³ Discipline of Dermatology - Universidade Federal de Pelotas (UFPEL) - Pelotas (RS), Brazil.

MAILING ADDRESS:

Hiram Larangeira de Almeida Jr.

E-mail: hiramalmeidajr@hotmail.com

©2018 by Anais Brasileiros de Dermatologia

