

Financial support

None declared.

Author's contribution

Han Ma: Approval of the final version of the manuscript; elaboration and writing of the manuscript.

Conflicts of interest

None declared.

References

1. Bastos JT, Rocha CRMD, Silva PMCE, Freitas BMP, Cassia FF, Avelleira JCR. Angiolymphoid hyperplasia with eosinophilia versus Kimura's disease: a case report and a clinical and histopathological comparison. *An Bras Dermatol.* 2017;92:392–4.
2. Buder K, Ruppert S, Trautmann A, Bröcker EB, Goebeler M, Kerstan A. Angiolymphoid hyperplasia with eosinophilia and Kimura's disease – a clinical and histopathological comparison. *J Dtsch Dermatol Ges.* 2014;12:224–8.
3. Shah K, Tran AN, Magro CM, Zang JB. Treatment of Kimura disease with mycophenolate mofetil monotherapy. *JAAD Case Rep.* 2017;3:416–9.
4. Chen Y, Wang J, Xu F, Zeng C, Liu Z. Clinicopathological features and prognosis of Kimura's disease with renal involvement in Chinese patients. *Clin Nephrol.* 2016;85:332–9.
5. Katagiri K, Itami S, Hatano Y, Yamaguchi T, Takayasu S. *In vivo* expression of IL-4, IL-5 IL-13 and IFN-gamma mRNAs in peripheral blood mononuclear cells and effect of cyclosporine A in a patient with Kimura's disease. *Br J Dermatol.* 1997;137:972–7.

Han Ma 

Department of Dermatology, the Fifth Affiliated Hospital, Sun Yat-sen University, Zhuhai, Guangdong, China
E-mail: drmahana@sina.com

Received 25 February 2018; accepted 1 March 2019

<https://doi.org/10.1016/j.abd.2019.03.006>

0365-0596/ © 2019 Sociedade Brasileira de Dermatologia.

Published by Elsevier España, S.L.U. This is an open access article under the CC BY license (<http://creativecommons.org/licenses/by/4.0/>).

Necrotic xanthogranuloma with disseminated annular lesions☆☆☆



Dear Editor,

Necrotic xanthogranuloma (NX) is a non-Langerhans histiocytosis, initially described in 1980,¹ which is characterized by yellowish plaques and nodules with a tendency to ulceration, which may infiltrate mainly the periorbital region, the flexor surface of the extremities, and the trunk. There is no predilection for gender and it mainly affects middle-aged patients.

A 73-year-old man, attended the dermatology outpatient clinic, with yellowish lesions on the trunk that had been present for two years. On physical examination, he showed infiltrated annular plaques with clear centers and erythematous borders on the thorax and abdomen, and asymptomatic lower limbs (Figs. 1 and 2). One of the lesions of the abdomen was ulcerated. He reported a previous diagnosis, about 20 years ago, of annular granuloma. A biopsy of the abdominal lesion was performed (Fig. 3) with the diagnostic hypotheses of necrotic xanthogranuloma, lipidica necrobiosis, annular granuloma, and xanthoma. Histopathology showed the dermis completely compromised by a chronic granulomatous process with numerous Touton cells, some bizarre, and areas of necrobiosis with nuclear

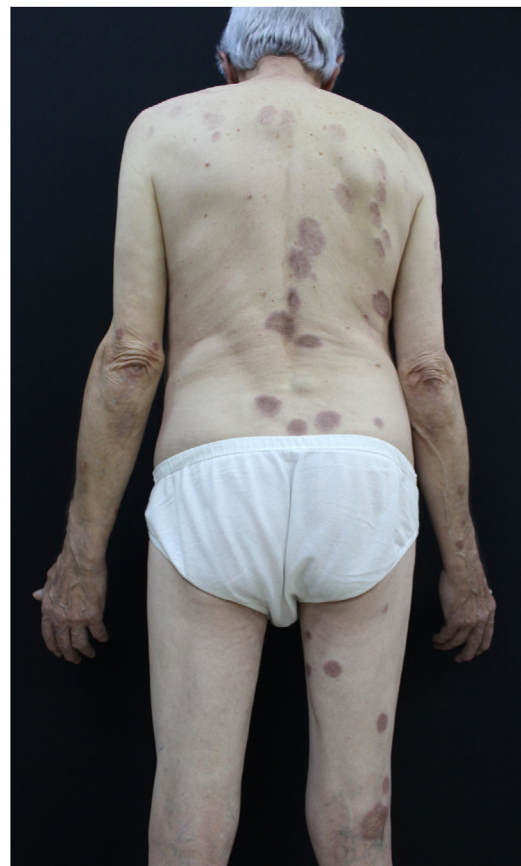

Figure 1 Lesions on the back. Yellowish infiltrated annular plaques with clear centers and erythematous borders.

☆ How to cite this article: Fasciani IA, Valente NYS, Luce MCA, Kakizaki P. Necrotic xanthogranuloma with disseminated annular lesions. *An Bras Dermatol.* 2020;95:117–9.

☆☆☆ Study conducted at the Hospital do Servidor Público Estadual de São Paulo (HSPE), São Paulo, SP, Brazil.

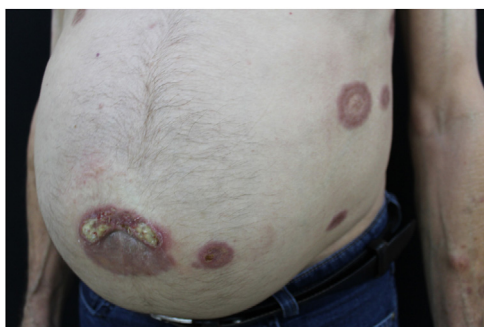

Figure 2 Detail of the lesion on the abdomen. Yellowish plaques on the abdomen.

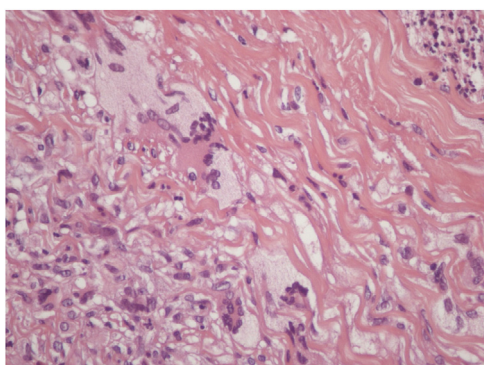


Figure 3 Skin biopsy. Necrotic xanthogranuloma. Presence of collagen necrobiosis and giant cells.

debris and collagen sclerosis. The findings favored necrobiotic xanthogranuloma. In view of this diagnosis, monoclonal gammopathy was investigated, and urinary immunofixation revealed a monoclonal band corresponding to the kappa light chain (Bence Jones) and serum immunofixation, detected by the IgG kappa monoclonal band. The patient was referred to the hematology service, where he underwent bone marrow biopsy, without criteria for hematological diseases at the time of the work up. The patient is currently using dapsone and presenting partial improvement of the lesions. He has been followed in conjunction with hematology.

NX has cutaneous findings, predominantly yellowish plaques in the periorbital area, trunk, and extremities, most often associated with paraproteinemia, and can coexist with systemic involvement of multiple organs, such as the heart, respiratory system, spleen, kidneys, liver, skeletal muscle, and central nervous system.² Up to 80% of patients diagnosed with NX present or will present monoclonal paraproteinemia, predominantly of the monoclonal gammopathy type IgG kappa or lambda.¹

The association between NX and hematological disorders is well documented, with an increased risk of hematological diseases, malignancies, and lymphoproliferative disorders.³ Hematologic disorders may occur up to eight years before or 11 years after the appearance of cutaneous lesions.⁴ For this reason, patients diagnosed with NX require lifelong care.

Other changes that may accompany NX are neutropenia, hypocomplementemia, cryoglobulinemia, or hyperlipidemia. Associated diseases include multiple myeloma, chronic lymphocytic leukemia, Hodgkin's disease, non-Hodgkin's lymphoma, asthma, and Quincke's edema.

The differential diagnoses for NX include lipoid necrobiosis, juvenile xanthogranuloma, annular granuloma, foreign body granuloma, subcutaneous rheumatoid nodules, xanthomas (disseminated, normolipemic flat, primary, and secondary), amyloidosis, and Erdheim-Chester disease.

In histopathology, NX shows typical areas of necrobiosis surrounded by granulomas composed of giant Touton cells, foamy histiocytes, and giant foreign-type giant cells, as well as lymphocytes, compromising the entire dermis.

In the pathogenesis of NX, it is suggested that serum immunoglobulins bind to lipids, depositing in the skin, which would provoke a foreign body reaction. Another hypothesis is that paraprotein would bind the Fc portion of IgG by activating a secondary proliferation of macrophages. It has also been proposed that the paraprotein in NX has the functional characteristics of a lipoprotein that can bind to histiocyte lipoprotein receptors and induce granuloma formation.¹ The etiology of this disorder remains obscure despite theories that attempt to clarify its pathogenesis. Consequently, treatment is difficult, without a recommended first-line therapy and a tendency to recurrent skin lesions.

Treatment options include immunomodulatory drugs, immunosuppressive agents, corticosteroids, alkylating agents, plasmapheresis, and radiotherapy.⁵ However, it has been found that even with treatment the lesions tend to be progressive, with recurrence of new lesions. Due to its rarity, there is no recommended first-line treatment. Thus, the therapeutic option should be chosen based on the hematological conditions associated with the disorder, as well as on the location, extent, and degree of impairment of the patient's life.

Financial support

None declared.

Authors' contribution

Isaura Azevedo Fasciani: composition of the manuscript.

Neusa Yuriko Sakai Valente: statistical analysis, approval of the final version of the manuscript; participation in the design of the study; critical review of the literature.

Maria Claudia Alves Luce: conception and planning of the study.

Priscila Kakizaki: approval of the final version of the manuscript; participation in the design of the study; critical review of the manuscript.

Conflicts of interest

None declared.

References

1. Ugurlu S, Bartley GB, Gibson LE. Necrobiotic xanthogranuloma: long-term outcome of ocular and systemic involvement. *Am J Ophthalmol.* 2000;129:651–7.
2. Seastrom S, Bookout A, Hogan DJ. Necrobiotic xanthogranuloma without a monoclonal gammopathy. *Cutis.* 2014;94:293–6.
3. Spicknall KE, Mehregan DA. Necrobiotic xanthogranuloma. *Int J Dermatol.* 2009;48:1–10.
4. Wood AJ, Wagner MV, Abbott JJ, Gibson LE. Necrobiotic xanthogranuloma: a review of 17 cases with emphasis on clinical and pathologic correlation. *Arch Dermatol.* 2009;145:279–84.
5. Miguel D, Lukacs J, Illing T, Elsner P. Treatment of necrobiotic xanthogranuloma – a systematic review. *J Eur Acad Dermatol Venereol.* 2017;31:221–35.

Isaura Azevedo Fasciani ^{a,*}, Neusa Yuriko Sakai Valente ^a, Maria Claudia Alves Luce ^b, Priscila Kakizaki ^b

^a *Department of Dermatology, Hospital do Servidor Público Estadual (HSPE), São Paulo, SP, Brazil*

^b *Department of Dermatopathology, Hospital do Servidor Público Estadual (HSPE), São Paulo, SP, Brazil*

Corresponding author.

E-mail: isafasciani@hotmail.com (I.A. Fasciani).

Received 21 November 2018; accepted 13 March 2019

<https://doi.org/10.1016/j.abd.2019.03.007>

0365-0596/ © 2019 Sociedade Brasileira de Dermatologia.

Published by Elsevier España, S.L.U. This is an open access article under the CC BY license (<http://creativecommons.org/licenses/by/4.0/>).

A case of linear atrophoderma of Moulin^{☆,☆☆}



Dear Editor,

A 15-year-old Chinese girl presented with a 10-year history of asymptomatic, unilateral light brown patches affecting the right arm and right side of the trunk. The lesions were asymptomatic. There were no prior skin lesions or inflammation. There was no significant medical or family history. Physical examination found linear hyperpigmented atrophic patches on the right arm and right trunk following Blaschko's lines, involving both the anterior and posterior aspects. The skin was slightly atrophic on palpation. No signs of induration or inflammation were noted (Fig. 1A and B). Laboratory investigations – including full blood count, erythrocyte sedimentation rate, liver function test, renal profile, and antinuclear antibodies – were all negative or within the normal range. Biopsy of a lesion showed a normal epidermis with increased pigmentation of the basal layer, with more compact dermal collagen and mild upper dermal perivascular lymphocytic infiltration (Fig. 2). Dermoscopy found multiple light brown networks with unclear margins. The patient was diagnosed with linear atrophoderma of Moulin (LAM) and started treatment with topical halometasone 0.5% cream and hydroquinone 2% cream for two months, with no improvement.

LAM is a rare and distinct clinical entity characterized by acquired unilateral, hyperpigmented, and atrophic bandlike skin lesions following the lines of Blaschko, without prior inflammation or sclerotic appearance. It is named after Moulin, who, in 1992, reported on five patients with pigmented and more-or-less atrophic bands along Blaschko's

lines.¹ LAM usually progresses as a linear atrophic lesion in the first few months; then the lesion ceases to progress and persists. The etiology of LAM remains unclear. All reported cases were so far sporadic. It may be connected with gene mosaicism or autoimmunity. A study of the atrophic component of LAM by ultrasonography revealed that subcutaneous volume reduction was the cause of the atrophic appearance, not dermal atrophy.² Even though the clinical manifestation of LAM is rather unique, the histopathology of LAM is quite inconspicuous. Hematoxylin and eosin staining usually shows hyperpigmentation only in basal epidermal layers, without abnormal collagen or elastic fibers in the dermis or any obvious inflammation.¹ There may be some perivascular lymphocytic infiltration, acanthosis, epidermal atrophy, altered collagen in the dermis, and decreased or fragmented elastic tissue.²

Lopez et al.³ proposed the following diagnostic criteria for -LAM, including: (1) Onset during childhood or adolescence; (2) Development of hyperpigmented, slightly atrophic, unilateral lesions following Blaschko lines on the trunk or limbs; (3) Absence of prior inflammation or subsequent scleroderma; (4) A stable, non-progressive clinical course without a pattern of remission; (5) Histologic findings showing hyperpigmentation of the basal epidermis and a normal dermis with unaltered connective tissue and elastic fibers. Up to now, more than 30 cases of LAM have been reported in the literature. However, the condition may be overestimated. If the diagnostic criteria are strictly adhered to, the diagnosis of LAM cannot be reached in some cases, as these authors reported histologic findings that are compatible with other clinical entities.³

LAM must be differentiated from atrophoderma of Pasini and Pierini (APP), which also presents with similar configuration, atrophy, and hyperpigmentation, but does not follow Blaschko's lines. In addition, LAM is different from linear morphea, which usually presents preceding inflammation, induration, or scleroderma.

Histopathologically, morphea shows collagen bundles that are closely packed and oriented horizontally, and dermal appendages and subcutaneous fat are progressively lost.

[☆] How to cite this article: Zhang L-W, Ma M-S, Chen T, Fu L-X. A case of linear atrophoderma of Moulin. *An Bras Dermatol.* 2020;95:119–21.

^{☆☆} Study conducted at the Chengdu Second People's Hospital, Sichuan, China.