

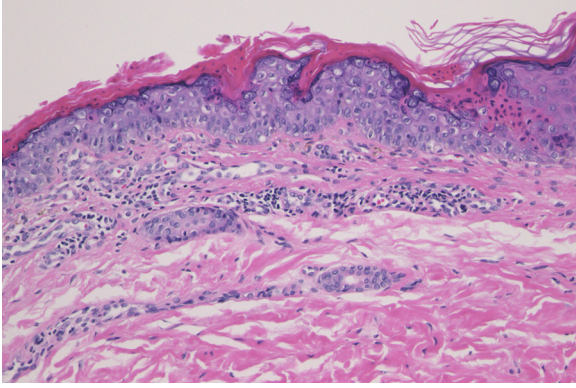Figure 3 Histological examination showed dyskeratotic cells in the thinned epidermis with cornoid lamella, and absence of granular cell layer. Superficial perivascular lymphocytic infiltrate in the dermis was also observed (Hematoxylin & eosin, ×200).

Financial support

None declared.

Authors' contributions

Masato Ishikawa: Designed the study; performed the research and contributed to analysis and interpretation of data; wrote the initial draft of the manuscript; read and approved the final version of the manuscript.

Toshiyuki Yamamoto: Designed the study; assisted in the preparation of the manuscript; read and approved the final version of the manuscript.

Conflicts of interest

None declared.

References

1. Shoimer I, Robertson LH, Storwick G, Haber RM. Eruptive disseminated porokeratosis: a new classification system. *J Am Acad Dermatol.* 2014;71:398–400.
2. Bednarek R, Ezra N, Toubin Y, Linos K, Mousdicas N. Eruptive disseminated porokeratosis associated with corticosteroid-induced immunosuppression. *Clin Exp Dermatol.* 2015;40:753–6.
3. Raychaudhuri SP, Smoller BR. Porokeratosis in immunosuppressed and nonimmunosuppressed patients. *Int J Dermatol.* 1992;31:781–2.
4. Pérez-Crespo M, Betlloch I, Lucas-Costa A, Bañuls-Roca J, Jaime MN, Mataix J. Unusual evolution of giant porokeratosis developing in two renal transplant patients. *Int J Dermatol.* 2008;47:759–60.
5. Hernandez MH, Lai CH, Mallory SB. Disseminated porokeratosis associated with chronic renal failure: a new type of disseminated porokeratosis? *Arch Dermatol.* 2000;136:1568–9.

Masato Ishikawa *, Toshiyuki Yamamoto 

Department of Dermatology, Fukushima Medical University, Fukushima, Japan

* Corresponding author.

E-mail: ishimasa@fmu.ac.jp (M. Ishikawa).

Received 6 July 2020; accepted 8 August 2020

Available online 20 March 2022

<https://doi.org/10.1016/j.abd.2020.08.038>

0365-0596/ © 2022 Sociedade Brasileira de Dermatologia.

Published by Elsevier España, S.L.U. This is an open access article under the CC BY license (<http://creativecommons.org/licenses/by/4.0/>).

Granulomatous arteritis limited to the skin: case report and etiologic differential diagnosis[☆]



Dear Editor,

Vasculitis constitutes a heterogeneous group of conditions characterized by inflammation in the blood vessel wall, with narrowing or occlusion of the vascular lumen. A 43-year-old man, without comorbidities, had presented multiple erythematous nodules on the anterior surface of the lower limbs for the past ten years, with outbreaks and remissions (Fig. 1). He had no local or systemic symptoms. A skin biopsy was performed and histopathology disclosed a nodular infiltrate with epithelioid histiocytes and multinucleated giant cells, on the wall and around a medium-caliber vessel, with occlusion

of the lumen by a fibrinoid thrombus (Figs. 2 and 3). Verhoeff-van Gieson staining demonstrated the presence of

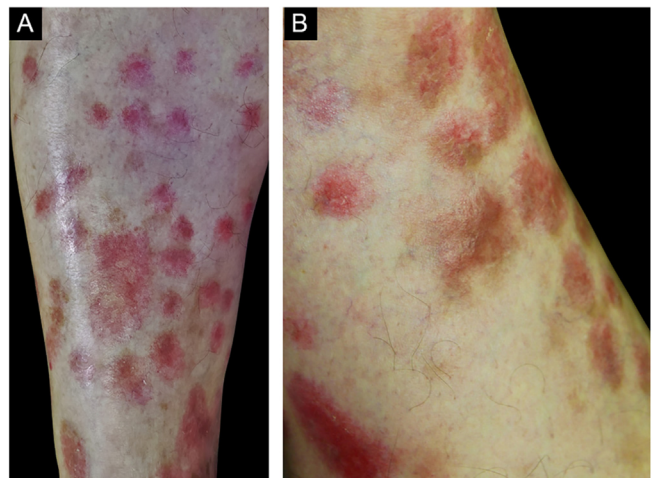


Figure 1 (A and B), Erythematous nodules on the extensor surface of the lower limbs.

[☆] Study conducted at the Hospital do Servidor Público Estadual de São Paulo, Instituto de Assistência Médica ao Servidor Público Estadual de São Paulo, São Paulo, SP, Brazil.

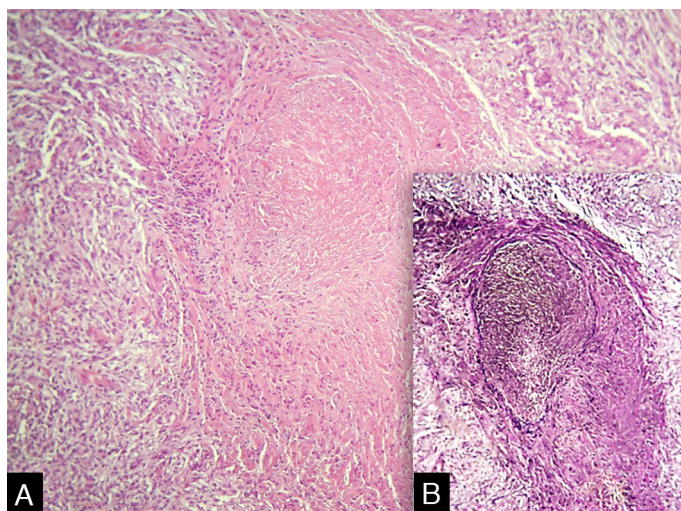


Figure 2 (A) Infiltrate in the wall of a medium-caliber vessel with the lumen occluded by a fibrinoid thrombus (Hematoxylin & eosin, $\times 200$). (B) Presence of the internal elastic lamina (Verhoeff-van Gieson).

an internal elastic lamina in the wall of the affected vessel (Fig. 2B). Fungi and AFB screening using Grocott and Faraco stains, respectively, were negative. Chest and sinuses tomography showed no alterations, as well as whole blood count, renal function, and measurement of complement fractions. As for ANCA, it was positive for a-ANCA 1/20 (negative for c-ANCA and p-ANCA).

Based on the histopathological findings, the diagnosis was granulomatous vasculitis. The term granulomatous vasculitis can be confusing, as it is used in two different contexts: (1) granulomatous inflammation in the vessel wall and (2) extravascular granulomatous inflammation associated with necrotizing vasculitis. The latter, better termed “vasculitis with granulomatosis”, has as prototypes granulomatosis with polyangiitis (GPA) and eosinophilic granulomatosis with polyangiitis (EGPA), which rarely have true granulomatous arteritis.¹

Granulomatous vasculitis is a common finding in the skin lesions of large-vessel vasculitis.¹ In temporal arteritis, there is usually a history of headache and muscle weakness, with the skin being unusually affected. Takayasu’s arteritis, which mainly affects the aorta and its branches, may also unusually affect the skin, with the histopathological finding of giant cell arteritis.^{1,2} The patient described in the present case report had no symptoms consistent with these conditions.

Rarely, granulomatous arteritis is a cutaneous manifestation of systemic diseases such as sarcoidosis, inflammatory bowel disease, hepatitis C and post-herpes zoster. Moreover, there are cases associated with medications such as montelukast.^{1,3} These possibilities were excluded through detailed anamnesis and complementary tests.

GPA and EGPA are ANCA-associated vasculitis, where histopathological analysis of the skin lesions usually discloses extravascular granulomas and small and medium - size vessels necrotizing vasculitis.⁴ More rarely, these vasculitis may present with granulomatous inflammation of the vessel wall and they are associated with systemic involvement, which was not seen in this patient.¹

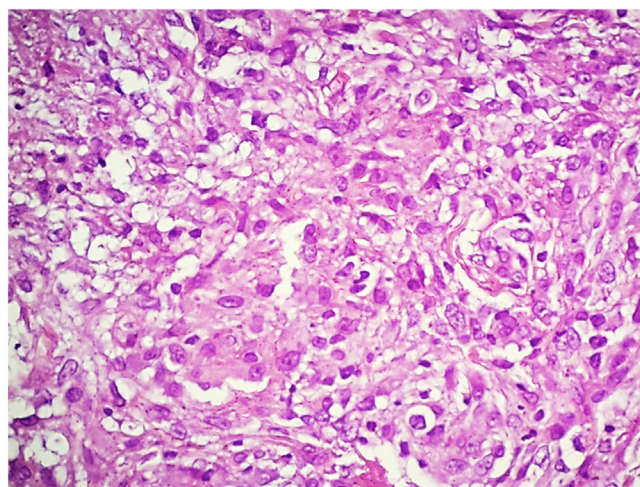


Figure 3 Detail of the infiltrate, consisting predominantly of epithelioid histiocytes (Hematoxylin & eosin, $\times 400$).

Atypical ANCA is characterized on indirect immunofluorescence by concomitant perinuclear and cytoplasmic staining, and it is mainly associated with drug-induced vasculitis.⁴ Although positive, it was not considered relevant to the clinical context, as, in addition to showing low titers, there was no history of medication or illicit drug use.

Cutaneous polyarteritis nodosa (PAN) manifests histopathologically as necrotizing arteritis.² The literature has only one mention of the possibility of this condition manifesting granulomatous inflammation with multinucleated giant cells in the vascular lumen in 2 of 20 cases of PAN, which clinically had the presence of a nodule in 90%, livedo reticularis in 80%, and ulceration in 35% of the cases.⁵ This case report describes a case of granulomatous vasculitis limited to the skin. Despite extensive research, no causal factor was found, and clinical-laboratory follow-up as an outpatient was chosen.

Financial support

None declared.

Authors' contributions

Diego Henrique Morais Silva: Design and planning of the study; drafting and editing of the manuscript; collection, analysis, and interpretation of data; critical review of the literature.

Neusa Yuriko Sakai Valente: Approval of the final version of the manuscript; effective participation in research orientation; intellectual participation in the propaedeutic and/or therapeutic conduct of the studied cases; critical review of the manuscript.

Agatha Ramos Oppenheimer: Approval of the final version of the manuscript; critical review of the manuscript.

Anna Karoline Gouveia de Oliveira: Approval of the final version of the manuscript; critical review of the manuscript.





Conflicts of interest

None declared.

References

- Carlson JA, Chen KR. Cutaneous vasculitis update: neutrophilic muscular vessel and eosinophilic, granulomatous, and lymphocytic vasculitis syndromes. *Am J Dermatopathol*. 2007;29:32–43.

- Marquez J, Flores D, Candia L, Espinoza LR. Granulomatous vasculitis. *Curr Rheumatol Rep*. 2003;5:128–35.
- Sharma A, Dogra S, Sharma K. Granulomatous vasculitis. *Dermatol Clin*. 2015;33:475–87.
- Suwanchote S, Rachayon M, Rodsaward P, Wongpiyabororn J, Deekajorndech T, Wright HL, et al. Anti-neutrophil cytoplasmic antibodies and their clinical significance. *Clin Rheumatol*. 2018;37:875–84.
- Chen KR. Cutaneous polyarteritis nodosa: a clinical and histopathological study of 20 cases. *J Dermatol*. 1989;16:429–42.

Diego Henrique Morais Silva *,
Neusa Yuriko Sakai Valente 
Agatha Ramos Oppenheimer 
Anna Karoline Gouveia de Oliveira 

Department of Dermatology, Hospital do Servidor Público Estadual de São Paulo, São Paulo, SP, Brazil

* Corresponding author.

E-mail: dhenriquems@gmail.com (D.H. Silva).

Received 22 September 2020; accepted 14 October 2020
Available online 21 March 2022

<https://doi.org/10.1016/j.abd.2020.10.021>

0365-0596/ © 2022 Sociedade Brasileira de Dermatologia.

Published by Elsevier España, S.L.U. This is an open access article under the CC BY license (<http://creativecommons.org/licenses/by/4.0/>).

Therapeutic approach of Lyell syndrome with infliximab and dexamethasone pulse: report of a clinical case[☆]



Dear Editor,

Toxic Epidermal Necrolysis (TEN) is a rare, life-threatening mucocutaneous disease.

A 23-year-old female presented with TEN after treatment with diclofenac, metamizole and etoricoxib. She was febrile, with oral, ocular, and perineal mucositis and a maculopapular rash involving an estimated body surface area of 20%. She was admitted to the dermatology department, skin biopsies were collected, and Intravenous Immunoglobulin (IVIg) was started. However, her clinical condition worsened, so she was transferred to the burn unit.

Upon admission, the patient had an extensive maculopapular rash. There were also positive Nikolsky signs in her face, back, palms and feet soles, and involvement of the oral, ocular, vaginal and perineal mucous membranes (Figs. 1 and 2). Additionally, given the upper airway edema, she was orotracheal intubated.

Under immunoglobulin therapy, there was a clinical worsening, with an increase in the body surface involvement, from 85% to 100%. In addition, she developed multiorgan failure with hematological, cardiovascular, hepatic, gastrointestinal and renal dysfunction.

On the eighth day of hospitalization, the patient received a single infliximab dose (5 mg/kg, EV) and was started on a pulse of dexamethasone (100 mg, EV × 1/day) for three days. After administration of infliximab and dexamethasone pulse, the patient evolved favorably with the progressive resolution of multiorgan dysfunction, and on the nineteenth day, the patient presented epithelialization of the entire body surface.

According to literature, TEN is a severe idiosyncratic reaction, mostly drug-induced. It is characterized by a detachment of the skin and mucous membranes at the level of the dermis-epidermis junction as a result of the necrosis of keratinocytes.

The diagnosis of TEN is clinical. It is characterized by a prodromal phase with flu-like symptoms that precede the appearance of mucocutaneous lesions. The confirmation of the diagnosis involves a skin biopsy.¹

In patients with probable drug-induced TEN, early diagnosis and immediate removal of the drug are essential to improve the prognosis.

Apart from supportive care, there is no established treatment. However, several immunosuppressants and immunomodulators have been used, and although there are

[☆] Study conducted at the Hospital de Santa Maria, Centro Hospitalar Universitário Lisboa Norte, Lisboa, Portugal.