

6. Miolo N, Rodrigues RF, Silva ERD, Piatí PK, Campagnolo OA, Marques LF. Skin cancer incidence in rural workers at a reference hospital in western Paraná. *An Bras Dermatol.* 2019;94:157–63.
7. Basurto-Lozada P, Molina-Aguilar C, Castaneda-García C, Vázquez-Cruz ME, García-Salinas OI, Álvarez-Cano A, et al. Acral lentiginous melanoma: basic facts, biological characteristics and research perspectives of an understudied disease. *Pigment Cell Melanoma Res.* 2021;34:59–71.
8. Brandão PHDM, Bertolli E, Doria-Filho E, Santos Filho IDAO, de Macedo MP, Pinto CAL, et al. In transit sentinel node drainage as a prognostic factor for patients with cutaneous melanoma. *J Surg Oncol.* 2018;117:864–7.
9. Hyams DM, Cook RW, Buzaid AC. Identification of risk in cutaneous melanoma patients: prognostic and predictive markers. *J Surg Oncol.* 2019;119:175–86.
10. Cherobin ACFP, Wainstein AJA, Colosimo EA, Goulart EMA, Bitencourt FV. Prognostic factors for metastasis in cutaneous melanoma. *An Bras Dermatol.* 2018;93:19–26.

Amanda Gabay Moreira ^{ID} ^b,
 Antonio Vitor da Silva Freitas ^{ID} ^b,
 Carla Andrea Avelar Pires ^{ID} ^{a,*}

^a Department of Dermatology, Universidade do Estado do Pará, Belém, PA, Brazil

^b Department of Medicine, Universidade do Estado do Pará, Belém, PA, Brazil

* Corresponding author.

E-mail: carlaavelarpires@gmail.com (C.A. Pires).

Received 12 September 2022; accepted 20 December 2022

<https://doi.org/10.1016/j.abd.2022.12.013>

0365-0596/ © 2024 Sociedade Brasileira de Dermatologia.

Published by Elsevier España, S.L.U. This is an open access article under the CC BY license

(<http://creativecommons.org/licenses/by/4.0/>).

Stiff skin syndrome: long-term follow-up[☆]



Dear Editor,

Stiff skin syndrome (SSS) is a rare, fibrosing, non-inflammatory, and progressive disease that manifests itself at birth or in early childhood. The dermatological picture is characterized by sclerotic plaques, with a hard consistency, with or without hypertrichosis. The lesions occur predominantly in the limbs and scapular and pelvic girdles, causing joint deformities and gait and postural changes.^{1–3} Characteristically, there are no systemic symptoms, such as Raynaud's phenomenon, periungual changes, and visceral involvement, which helps to differentiate it from systemic sclerosis, localized cutaneous sclerosis, collagenomas, neonatal sclerema, scleromyxedema and mucopolysaccharidoses.^{4,5}

The diagnosis is based on clinical and histopathological findings. The former include hereditary (fibrillin-1 gene) or sporadic condition (mutation in the transforming growth factor-beta binding protein 4), prominent skin thickening in areas with abundant fascia (buttocks and thighs), joint mobility limitation, hypertrichosis and absence of systemic changes. The microscopic findings are: thickening of collagen with deposition of mucin; fascial sclerosis; absence of significant inflammation; horizontal orientation of thickened collagen fibers and adipocyte entrapment.^{2,6–11}

The treatment is challenging and there are no established guidelines for patient care. Therefore, most of the reported therapies are empirical, such as methotrexate, topical and systemic corticosteroids, UVB-NB phototherapy and immunoglobulin, without satisfactory results.⁹ Non-drug therapies, such as motor physical therapy, have been shown to be important in preventing muscle contractures and postural sequelae.^{4,5}

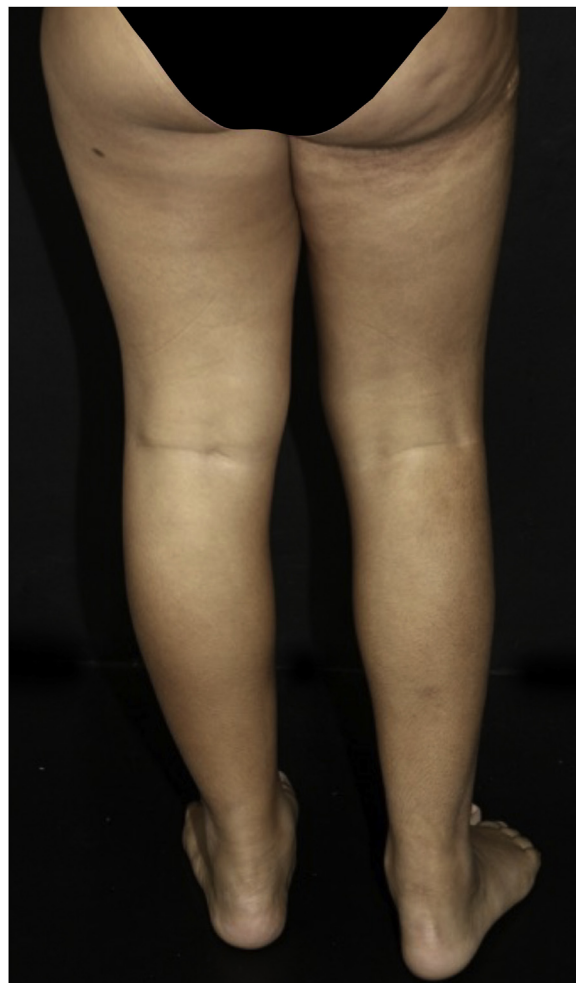

Figure 1 Stiff skin syndrome. An 11-years-old female patient, with sclerotic plaques showing a cobblestone pattern on the right gluteal and thigh region, also with a difference in length between the limbs.

[☆] Study conducted at the Pediatric Dermatology, Hospital das Clínicas, Faculty of Medicine, Universidade de São Paulo, SP, Brazil.

Table 1 Clinical and histopathological findings of patients with SSS.

	Case 1	Case 2	Case 3	Case 4	Case 5
Gender	M	F	F	M	F
Location	Middle to lower back and hips on the L	Lateral of R breast, to R thigh, flank and back on the L	Proximal anterior aspect of L thigh, abdomen, ipsilateral gluteal region	R shoulder, lateral upper back, proximal portion of RUL	Proximal anterior aspect of R thigh, ipsilateral abdomen
Age at diagnosis	9 years	9 years	6 years	5 years	5 years
Current age	19 years	19 years	12 years	13 years	11 years
Thickening of collagen fibers and deposition of mucin	Yes	Yes	No	Yes	Yes
Fascial sclerosis	Yes	No fascia represented	No fascia represented	No fascia represented	No fascia represented
Absence of inflammation	Yes	Yes	Yes	Yes	Yes
Horizontal orientation of thickened collagen fibers	Yes	Yes	No	Yes	Yes
Adipocyte entrapment	Yes	Yes	No	Yes	Yes
Time of follow-up	7 years	11 years	4 years	6 years	6 years
Drug treatment/phototherapy	Methotrexate 15 mg per week (38 months), prednisone 30 mg per day (5 months)	Methotrexate 15 mg per week (15 months), NB-UVB (12 months)	-	-	-
Physical therapy and regular exercise	Yes	Yes	No (non-adherent patient)	Yes	Yes
Limbs of different length	Yes	Yes	Yes	Yes	Yes
Postural change	Yes	Yes	Yes	Yes	Yes
Pain in the affected limb during physical activity	No	No	Yes	No	Yes
Disease stability	Yes	No	No	Yes	No

R, Right; L, Left; RUL, Right Upper Limb; F, Female; M, Male.

Five patients with SSS were followed at the Pediatric Dermatology outpatient clinic of Hospital das Clínicas, Faculty of Medicine, Universidade de São Paulo, aged 11 to 19 years, for an average period of seven years (Table 1). All had segmental hardened subcutaneous plaques (Fig. 1), with a cobblestone pattern (Fig. 2). All cases showed a difference in length between the limbs, and two had postural changes and pain during physical activity. Family history of SSS or consanguinity of the parents was not observed.

Patients underwent skin biopsy for histopathological examination (Fig. 3). Two patients underwent magnetic resonance imaging (MRI) aiming to better assess the extent of the lesion. MRI revealed slight skin thickening and vascular ectasia in the subcutaneous plane adjacent to the site of involvement.

The set of findings confirmed the diagnosis of SSS. Two patients were prescribed methotrexate and phototherapy with UVB-NB, which were later withdrawn due to lack of response. Treatment with physical therapy and regular physical exercise was recommended to all. At the last evaluation,

stability or slow progression of the condition was observed (Table 1).

SSS is a challenging disease in clinical practice, given its rarity, scarcity of reported cases, and the slowly progressive nature of the disease, leading to late diagnosis.¹⁻³

Deng et al.³ reported predominance in female patients, and the same was observed in this case series. Uni- or bilateral involvement and difference in length between the limbs were observed in all patients, findings in agreement with data in the literature.¹⁻⁶

Clinicopathological correlation is necessary for the diagnosis, so biopsy is essential. When SSS is suspected, it is recommended to perform a representative biopsy sample, including skin and muscle fascia; to achieve that, punch biopsies are usually inappropriate. Incisional biopsy under anesthesia at the surgical theater are more likely to obtain an adequate specimen.

Drug therapeutic options are scarce and must be based on antifibrotic properties and the ability to reduce transforming factor β (TGF- β) signaling. Although glucocorticoids

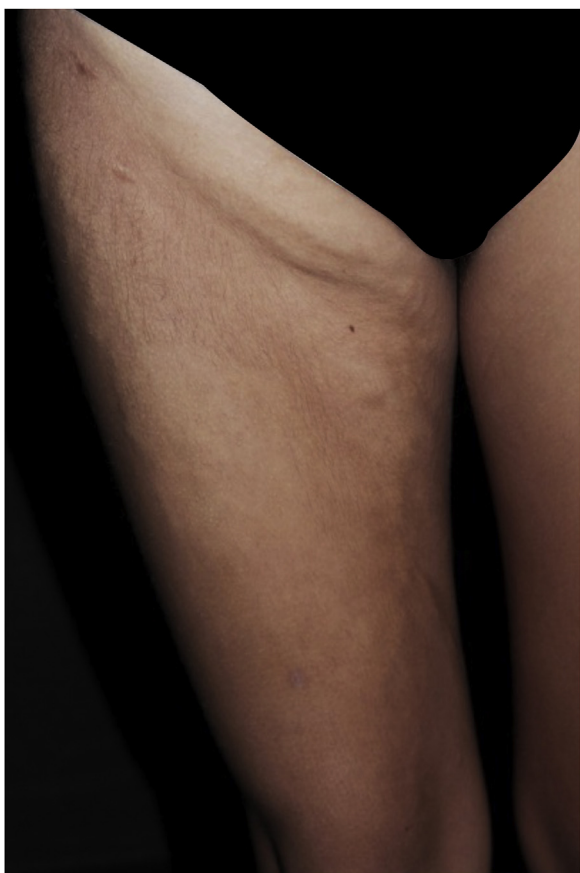

Figure 2 Stiff skin syndrome. An 19 years-old female patient, with sclerotic plaques showing a cobblestone pattern on the thigh and right inguinal region.

inhibit collagen biosynthesis, they are not an appropriate therapeutic option on a continuous basis, due to their side effects. Furthermore, as it is a pauci-inflammatory condition, immunosuppressive and anti-inflammatory medications have not been shown to be effective.¹

In 2020, a case of reduced disease progression was described with the use of secukinumab, due to its action in reducing TGF- β signaling, a cytokine involved in the pathogenesis of SSS. However, the treatment basis continues to be physical rehabilitation, preferably in the initial stage of the disease.^{2,8,10} Instructing patients to perform motor physical therapy and physical activity is essential.

It is important to recognize SSS as a differential diagnosis of sclerotic diseases, thus preventing ineffective systemic treatment and its possible adverse effects. The detection of histopathological changes requires careful analysis by an experienced dermatopathologist. Studies with a larger sample size and long-term clinical follow-up are required to establish effective therapeutic guidelines.

Financial support

None declared.

Authors' contributions

Jessica Lana Conceição and Silva Baka: Design and planning of the study; collection, analysis and interpretation of data; drafting and editing of the manuscript; critical review of the literature; critical review of the manuscript; approval of the final version of the manuscript.

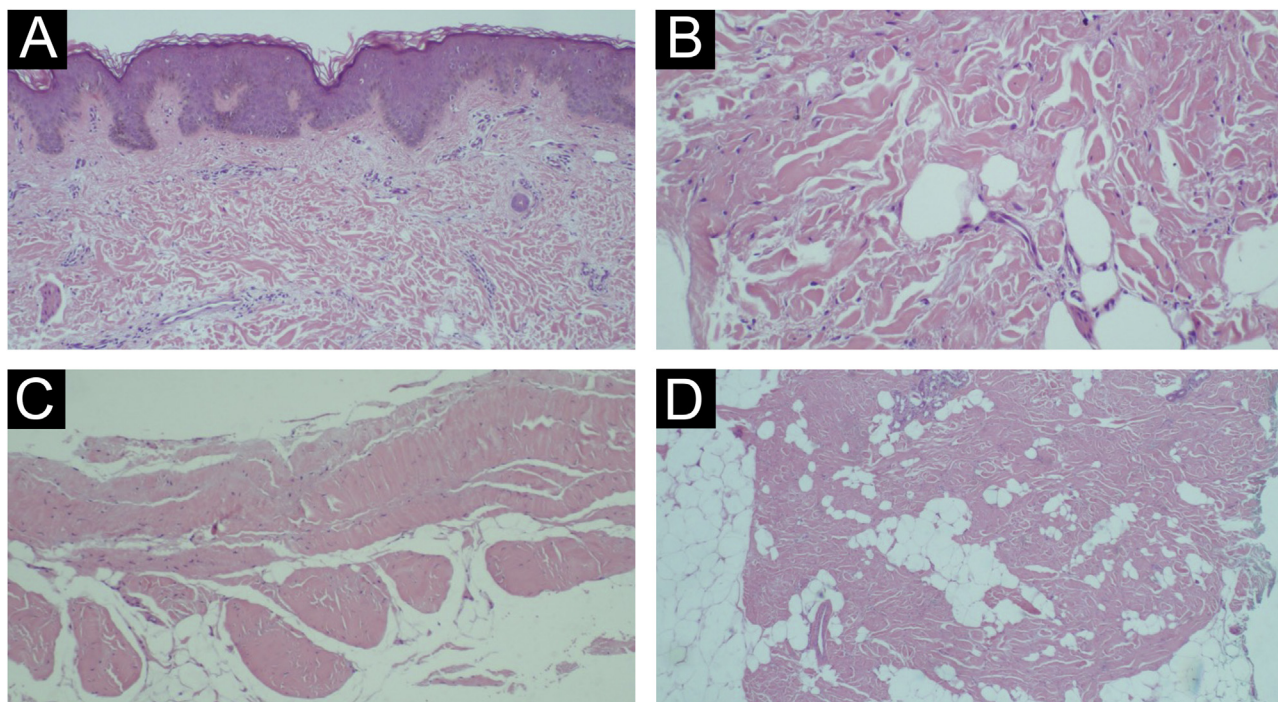


Figure 3 Histopathology. (A) Absence of significant inflammation; (B) Thickening and horizontalization of collagen fibers and mild dermal mucinosis; (C) Sclerosis and densification of the fascia; (D) Adipocyte entrapment and thickening of the septa (Hematoxylin & eosin staining).

Tauana Ogata Coelho da Rocha: Analysis and interpretation of data; drafting and editing of the manuscript; critical review of the literature; critical review of the manuscript; approval of the final version of the manuscript.

Marcella Soares Pincelli: Analysis and interpretation of data; drafting and editing of the manuscript; critical review of the literature; critical review of the manuscript; approval of the final version of the manuscript.

Luciana Paula Samorano: Analysis and interpretation of data; drafting and editing of the manuscript; critical review of the literature; critical review of the manuscript; approval of the final version of the manuscript.

Maria Cecília da Matta Rivitti-Machado: Analysis and interpretation of data; drafting and editing of the manuscript; critical review of the literature; critical review of the manuscript; approval of the final version of the manuscript.







Zilda Najjar Prado de Oliveira: Analysis and interpretation of data; drafting and editing of the manuscript; critical review of the literature; critical review of the manuscript; approval of the final version of the manuscript.

Conflicts of interest

None declared.

References

- Halverstam CP, Mercer SE, Harwayne-Gidansky I, Geller L, Phelps RG. Stiff skin syndrome in a newborn infant. *Int J Dermatol*. 2013;52:993–5, <http://dx.doi.org/10.1111/j.1365-4632.2012.05478.x>.
- Myers KL, Mir A, Schaffer JV, Meehan SA, Orlov SJ, Brinster NK. Segmental stiff skin syndrome (SSS): a distinct clinical entity. *J Am Acad Dermatol*. 2016;75:163–8.
- Deng X, Chen F, Song Z, Yan H, You Y, Zhong B, et al. Four new cases of stiff skin syndrome with unusual presentations. *J Eur Acad Dermatol Venereol*. 2016;30:163–5, <http://dx.doi.org/10.1111/jdv.12657>.
- Esterly NB, McKusick VA. Stiff skin syndrome. *Pediatrics*. 1971;47:360–9.
- Amorim AGF, Aidé MK, Durães SMB, Rochael MC. Stiff skin syndrome: case report. *An Bras Dermatol*. 2011;86:178–81.
- Liu T, McCalmont TH, Frieden IJ, Williams ML, Connolly MK, Gilliam AE. The stiff skin syndrome: case series, differential diagnosis of the stiff skin phenotype, and review of the literature. *Arch Dermatol*. 2008;144:1351–9.
- McCalmont TH, Gilliam AE. A subcutaneous lattice-like array of thick collagen is a clue to the diagnosis of stiff skin syndrome. *J Cutan Pathol*. 2012;39:2–4.
- Bachour J, Ghandour F, Ammouy A. Stony hard skin during early infancy. *Am J Dermatopathol*. 2018;40:614–6.
- Ogunmakin K, Vangipuram R, Sturgeon A, Shimizu I. A 7-year-old with indurated skin and unilateral progressive joint immobility: a case of stiff skin syndrome. *Dermatol Online J*. 2015;21, 13030/qt116291c1.
- Rangu S, Rubin AI, Li D, Castelo-Soccio L. Segmental stiff skin syndrome: a novel case with an interleukin-17C mutation successfully treated with secukinumab. *Clin Exp Dermatol*. 2020;45:658–60.
- Loeys BL, Gerber EE, Riegert-Johnson D, Iqbal S, Whiteman P, McConnell V, et al. Mutations in fibrillin-1 cause congenital scleroderma: stiff skin syndrome. *Sci Transl Med*. 2010;2:23ra20.

Jessica Lana Conceição e Silva Baka ^{a,*},
 Tauana Ogata Coelho da Rocha ^a,
 Marcella Soares Pincelli ^b, Luciana Paula Samorano ^a,
 Maria Cecília da Matta Rivitti-Machado ^a,
 Zilda Najjar Prado de Oliveira ^a

^a *Pediatric Dermatology, Hospital das Clínicas, Faculty of Medicine, Universidade de São Paulo, São Paulo, SP, Brazil*

^b *Dermatopathology, Hospital das Clínicas, Faculty of Medicine, Universidade de São Paulo, São Paulo, SP, Brazil*

* Corresponding author.

E-mail: jessicabaka21@gmail.com (J.L. Baka).

Received 16 April 2023; accepted 9 July 2023

<https://doi.org/10.1016/j.abd.2023.07.013>

0365-0596/ © 2024 Sociedade Brasileira de Dermatologia.

Published by Elsevier España, S.L.U. This is an open access article under the CC BY license (<http://creativecommons.org/licenses/by/4.0/>).