

# Clinical and molecular aspects of a pediatric metachronous adrenocortical tumor

Aspectos clínicos e moleculares de tumor adrenocortical metacrônico pediátrico

Lorena de Oliveira Lima<sup>1</sup>, Antonio Marcondes Lerario<sup>1</sup>,  
Guilherme Asmar Alencar<sup>1</sup>, Luciana Pinto Brito<sup>1</sup>,  
Madson Queiroz Almeida<sup>1</sup>, Sorahia Domenice<sup>1</sup>, Ana Claudia Latronico<sup>1</sup>,  
Berenice Bilharinho Mendonca<sup>1</sup>, Maria Candida Barrison Villares Fragoso<sup>1</sup>

## SUMMARY

The occurrence of metachronous adrenocortical carcinoma has rarely been described. We report a case of a child with virilizing adrenocortical metachronous tumors that, despite several metastases, presented long-term survival (15 years). We analyzed in this tumor *IGF2*, *IGF1R* and *FGFR4* gene expression, and evaluated the presence of p.R337H germline p53 mutation and somatic *CTNNB1* mutation. *IGF2* gene was over-expressed in both left (Weiss score 5) and right (Weiss 7) adrenocortical tumors. *IGF1R* expression levels were higher in the right adrenocortical tumor. *FGFR4* over-expression was also detected in the right adrenocortical tumor. In addition, this patient harbors the germline p.R337H p53 mutation and loss of heterozygosity (LOH) was detected in the tumors. No somatic *CTNNB1* mutations were found in both tumors. In conclusion, we demonstrated in this unusual case the over-expression of growth signaling pathways, which are molecular mechanisms previously related to adrenocortical tumorigenesis. Furthermore, the absence of somatic *CTNNB1* mutations, which is a molecular marker of poor prognosis in adults, might be related to the long-term survival of this patient. *Arq Bras Endocrinol Metab.* 2011;55(1):72-7

## SUMÁRIO

A ocorrência de carcinomas adrenocorticais metacrônicos é raramente relatada. Descrevemos o caso de uma criança portadora de tumor adrenocortical virilizante metacrônico que, apesar das inúmeras metástases, apresentou uma longa sobrevida (15 anos). Analisamos nesse tumor a expressão gênica de *IGF2*, *IGF1R* e *FGFR4* e avaliamos a presença da mutação germinativa R337H no p53 e mutação somática no gene *CTNNB1*. O gene *IGF2* foi hiperexpresso nos tumores adrenocorticais esquerdo (Weiss 5) e direito (Weiss 7). Os níveis de expressão de *IGF1R* foram maiores no tumor direito. Hiperexpressão do gene *FGFR4* também foi observada no tumor adrenocortical direito. Esse paciente é portador da mutação germinativa R337H no p53, e perda de heterozigose (LOH) foi observada em ambos os tumores. Não foram encontradas mutações no gene *CTNNB1* nos tumores. Em conclusão, demonstramos neste caso a hiperexpressão de vias moleculares de crescimento, que são mecanismos previamente relacionados à tumorigênese adrenocortical. Além disso, não encontramos mutações somáticas no gene *CTNNB1*, que é um marcador molecular de mau prognóstico em adultos e poderia estar relacionado à longa sobrevida desse paciente. *Arq Bras Endocrinol Metab.* 2011;55(1):72-7

<sup>1</sup> Endocrinology Development Unit, Division of Endocrinology, Department of Internal Medicine, Hospital das Clínicas, Faculdade de Medicina da Universidade de São Paulo (HC-FMUSP), São Paulo, SP, Brazil

### Correspondence to:

Lorena de Oliveira Lima  
HC-FMUSP, Disciplina de  
Endocrinologia e Metabologia,  
Laboratório de Hormônios e  
Genética Molecular LIM42  
Av. Dr. Eneas de Carvalho Aguiar, 155  
2º andar, Bloco 6  
05403-900, São Paulo, SP, Brazil  
lorenalima@usp.br

Received on Sept/2/2010  
Accepted on Dec/28/2010

## INTRODUCTION

Adrenocortical carcinoma is a rare tumor in childhood. However, the incidence of adrenocortical tumors in children under the age of 15 years (mostly

diagnosed before the age of 4) in Southeast Brazil is approximately 10 times greater than the worldwide incidence that ranges from only 0.3-0.38 million per year (1). A unique germline mutation of *TP53* (R337H)

underlies the genetic predisposition in this population (1-3). Pediatric adrenocortical tumors appear to behave differently than histologically similar tumors in the adult population (4). Unlike the dismal survival statistics in adult adrenocortical carcinoma series, pediatric adrenocortical tumors with apparent poor prognosis on the basis of histopathological features may often have a better outcome (5). Unfortunately, there are no histological or molecular markers so far that can reliably distinguish benign from malignant adrenocortical tumors and define the prognosis. Clearly, the extent of surgical resection is the most important factor in patient outcome (6).

The mechanisms of adrenocortical tumorigenesis are still not fully understood, but several data suggest that malignant transformation is a multistep process (7). Molecular studies of sporadic adrenocortical tumors in the pediatric age group are limited due to the rarity of this condition, however, since children seem to have a better prognosis, it is important to determine whether the same molecular alterations described in adults are also present in children, and whether this is related to the outcome. We report the case of adrenocortical metachronous tumors presenting in a child with long-term survival, emphasizing different molecular pathways that could be involved in the adrenocortical tumorigenesis and related to the benign evolution of this patient.

## CASE REPORT

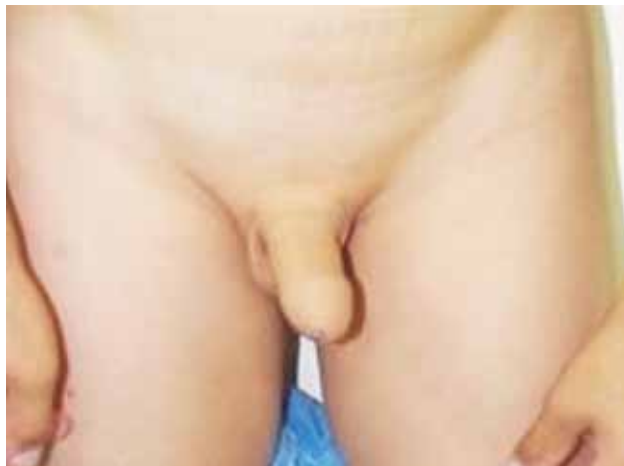This study was approved by the Ethics Committee of Hospital das Clínicas (São Paulo, Brazil). The parents of this child provided informed consent, including for the use of the photographs, images and the report that follows. The patient was born full term after an uncomplicated pregnancy and delivery. At 2 years and 2 months of age, the child presented with signs of virilization (pubic hair, penis enlargement, growth acceleration and aggressiveness) (Figure 1). At that time, his weight and height were 18.0 kg and 100.0 cm respectively (height SD + 3.74). At physical examination he was found to have virilization described as prepubertal testis and more recent facial acne, deepening of the voice, and increased muscle mass, but no abdominal mass was palpable. The family history was unremarkable. Laboratory evaluation demonstrated undetectable gonadotropins and abnormally elevated adrenal steroid levels: DHEA-S, 1790 ng/mL [normal range < 194 ng/mL]; androstenedione, 2.0 ng/mL [normal range < 0.3-2.9 ng/mL], and testosterone, 395 ng/dL [normal range < 19 ng/dL], characterizing isosexual precocious

puberty independent of gonadotropins. Abdominal computerized tomography (CT) showed a 2.0 cm mass in the left adrenal gland (Figure 2). The patient underwent surgical procedure and an adrenal mass with 3.0 g of weight and 2.5 cm of diameter was resected.

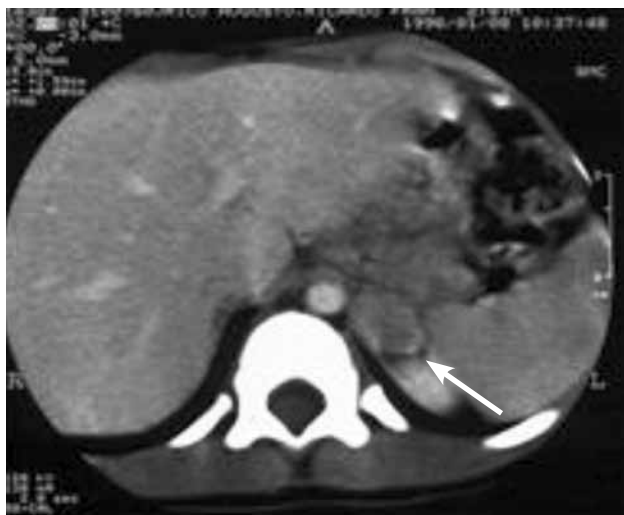The adrenocortical tumor had a histological Weiss score of 5 (8) and the MacFarlane modified by Sullivan staging was I (9) (Table 1). Postoperatively, the signs of virilization disappeared and all tumor markers returned to their normal ranges. At that time, the patient received no further treatment.

Two years after surgery the patient presented signs of virilization all over again and, in addition, frequent erections. Hormonal studies revealed elevated androgen levels (DHEA-S, 6,905 ng/mL [normal range, < 194 ng/mL]; androstenedione, 8.1 ng/mL [normal range, 0.3-2.9 ng/mL], and testosterone, 403 ng/dL [normal range < 19 ng/dL]). A novel right adrenal mass was discovered by an abdominal CT (Figure 3). No secondary lesions were detected by radiological studies at this time. The patient underwent surgical resection and intraoperative findings revealed a large (8.5 cm) tumor in the right adrenal gland. The mass was apparently adherent to the kidney and a freezing biopsy showed invasion of the capsule of the liver. The tumor was removed together with the right kidney and with a small portion of the right lobe of the liver. The weight of the tumor was 30.0 g and histological analysis revealed a Weiss score 7. Although no signs of invasion of the liver itself or the kidney were observed the tumor was classified as a carcinoma (MacFarlane modified by Sullivan staging III) (Table 1). Due to the poor prognosis associated with this diagnosis by the observation of invasion of the liver capsule by freezing biopsy, the patient was immediately started on mitotane. The dose was gradually increased to 1 g/d. The patient was also treated with replacement doses of cortisone acetate and fludrocortisone. Five months after tumor resection, the patient developed gynecomastia and severe neurologic side effects, and mitotane was discontinued. He continued to receive steroid replacement, and his adrenal markers remained undetectable.

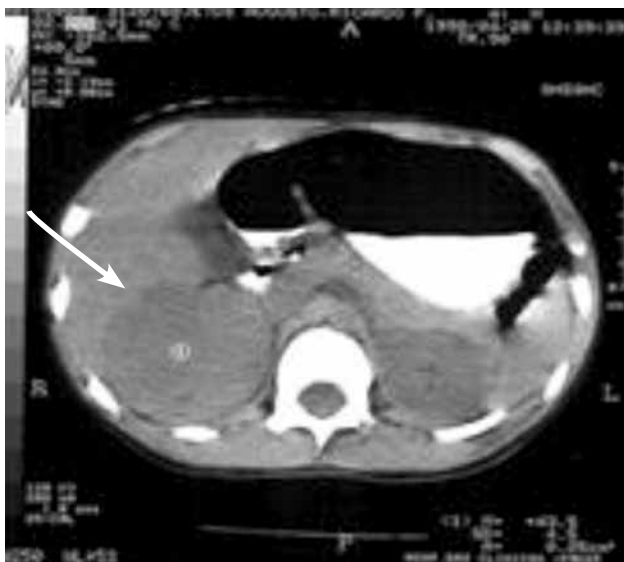
At 7 years and 8 months of age, his DHEA-S levels increased to 272 ng/mL. This relapse was secondary to a pulmonary metastasis, which was treated by surgery. Histology confirmed metastatic nodule of adrenocortical carcinoma. Seven months after this surgery, a novel elevation of DHEA-S levels was observed. A Positron emission tomography-fludeoxyglucose (PET-FDG) scan and a chest CT showed a left hilar pulmonary metastasis, which was successfully removed by surgical procedure.



**Figure 1.** Independent gonadotropins precocious puberty. Enlargement of the penis with prepubertal testis.



**Figure 2.** Abdominal computerized tomography showing a 2.0 cm mass in the left adrenal gland.



**Figure 3.** Abdominal computerized tomography showing a 8.0 cm mass in the right adrenal gland.

**Table 1.** Microscopic pathological assessment according to Weiss system

First adrenal tumor	Second adrenal tumor
Left adrenal tumor with 2.5 cm of diameter and 3.0 g of weight	Right adrenal tumor with 8.5 cm of diameter and 30.0 g of weight (tumor + right kidney = 175.0 g)
<b>Cytological alterations</b>	
1) Nuclear grade 4 according to Fuhrman's criteria	1) Nuclear grade 4 according to Fuhrman's criteria
2) Mitotic rate 13 per 50 high-power fields	2) Mitotic rate 51 per 50 high-power fields
3) Atypical mitosis	3) Atypical mitosis
<b>Structural alterations</b>	
4) Clear cells comprising 25% or less of the tumor (predominance of eosinophilic cells)	4) Clear cells comprising 25% or less of the tumor (predominance of eosinophilic cells)
5) Diffuse architecture > 1/3 of tumor	5) Diffuse architecture > 1/3 of the tumor
	6) Necrosis involving a confluent area of cells
<b>Invasion type</b>	
	7) Invasion of capsule of tumor*
Weiss score 5	Weiss score 7

\* : There was tumor capsule invasion but hepatic tissue biopsy was normal. In childhood adrenocortical tumors the criteria of Weiss classically used in the adult population have no correlation with biological behavior. In this context the first tumor was diagnosed as a tumor of the adrenal cortex with questionable prognosis. In contrast, the second tumor was clearly an adrenocortical carcinoma.

Nowadays, the patient is 17 years old with no evidence of new metastasis based on radiological imaging follow-up.

**METHODS AND RESULTS**

**Molecular analysis**

We have studied different molecular pathways related to the pathophysiology in a male pediatric case of metastatic adrenocortical carcinoma with long-term follow-up and insidious evolution. In trying to clarify the atypical tumor behavior in this case we investigated the expression of different genes in the tumor's tissue: insulin growth factor 2 (*IGF2*, Taqman assay Hs01005963\_m1, Applied Biosystems, Foster City, CA, USA) and its receptor (*IGFIR*, assay Hs00181385\_m1) and fibroblast growth factor receptor 4 (*FGFR4*, assay Hs00242558\_m1). Quantitative real-time PCR was performed as previously described (10,11). *IGF2* gene was over-expressed in both left (Weiss score 5) and right (Weiss 7) adrenocortical tumors. *IGFIR* expression levels were higher in the right adrenocortical tumor (fold change, 7.4 vs. 3.32).

We also analyzed the presence of mutations in a particular region of genes coding for p53, a tumor su-

Copyright © ABESEM todos os direitos reservados.

ppressor, and for beta-catenin (*CTNNB1*), a key component of Wnt pathway.

Tumor DNA was extracted according to standard procedures. Mutational analysis involving exon 3 of the *CTNNB1* gene, which encodes beta-catenin, was performed using flanking intronic sequences of this exon. The primers used were 5' TGGGTCATATCACA-GATTCTTTTTTTT 3' and 3'TCAAACCTGCATTCT-GACTTTCA 5'. PCR was performed employing TAQ DNA polymerase (Promega). The amplified product was submitted to direct sequencing on an automated sequencer (ABI 7000 sequencer detection system – Applied Biosystems). Mutations were verified in both sense and anti-sense directions. The entire exon 10 of the *TP53* gene was amplified and sequenced. In addition loss of heterozygosity (LOH) was studied in both tumors as previously described (1,2). The patient was found to be a carrier of the *TP53* R337H germinal mutation in a heterozygosity pattern, which seems to be associated with a predisposition to adrenocortical tumors without prognostic implications (2). In addition, LOH was detected in the left and right tumors. Analysis of *CTNNB1* exon 3 showed no alterations in both left and right tumors in comparison to wild type gene.

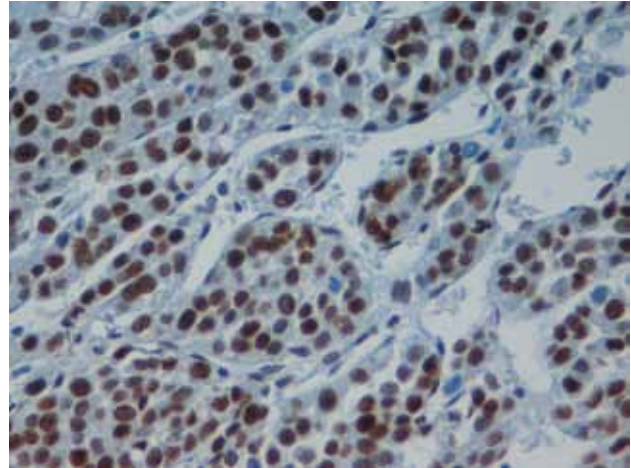
### Immunohistochemical analysis

To investigate the role of Wnt/beta-catenin signaling in tumorigenesis, beta-catenin expression was studied by immunohistochemistry using a monoclonal mouse anti-human beta-catenin antibody at the dilution of 1:200 (code: M3539 – Dakocytomation). In addition, we performed immunohistochemistry of p53, by P53 antibody at the dilution of 1:1000 (Clone DO7 – Dakocytomation).

The usual distribution of beta-catenin at the plasma membrane was demonstrated with no nucleus/cytoplasmic staining, which is the normal pattern, since beta-catenin plays a role in the cell-cell adhesion with cadherin (12). P53 immunohistochemistry analyzes showed abnormal nuclear staining as expected, as the patient is a carrier of R337H mutation in *TP53* (1,13) (Figure 4).

### DISCUSSION

The diagnosis of adrenocortical tumors in children is suspected mainly based on clinical signs and symptoms of androgen hormones in excess, causing precocious pubarche. The occurrence of isolated Cushing's Syn-



**Figure 4.** Immunohistochemical staining of p53. Nuclear immunopositivity for p53 in the right adrenocortical tumor. 400 x.

drome due to the production of glucocorticoid by an adrenocortical tumor is infrequent (3). Routine evaluation for suspected adrenocortical tumors consists in the measurement of: DHEA-S, testosterone, estradiol, LH, FSH, ACTH, androstenedione, 17-hydroxyprogesterone, aldosterone, renin activity, 11-deoxycortisol, and cortisol after low dose of overnight dexamethasone (5). To date, adrenocortical tumors in children are unequivocally established as carcinomas due to local recurrence or metastasis development. However, distinction between adenoma and carcinoma can be very difficult to accomplish when adrenocortical neoplasms are diagnosed in the early stages, since there is yet no reliable marker to predict tumor recurrence or dissemination. Pediatric adrenocortical tumors classified as carcinomas based solely on histopathological Weiss criteria often have favorable prognosis (14). Wieneke and cols. (4) described some factors that when identified in the aggregate appear to accurately predict a more aggressive biologic behavior, which includes: tumor weight > 400 g, tumor size > 10.5 cm, extension into perirenal soft tissues and/or adjacent organs, invasion into the vena cava, venous invasion, capsular invasion, presence of tumor necrosis, > 15 mitoses per 20 HPF, and presence of atypical mitosis figures (4). Of note is the presence of some of these histopathological criteria in both tumors presented by the child (Table 1), however, the tumors' weights and sizes are beneath these ranges. Among various clinical parameters that have been shown to impact adrenocortical carcinoma prognosis, tumor staging has been demonstrated as one of the most important (13). The staging system for adrenocortical carcinomas depends upon tumor size, nodal involve-

ment, invasion of adjacent organs, and presence of distant metastasis (9). However, it is important to know that is not uncommon for patients with small tumors to experience relapses.

The pathophysiological study of the adrenocortical carcinoma is important to improve diagnosis, prognostic evaluation, and treatment. Analysis of exon 10 of the *TP53* gene revealed that our patient is a carrier of *TP53* R337H germinal mutation as is the majority of pediatric Brazilian patients with adrenocortical tumors. This mutation is not related to a dismal behavior of this disease (2). *IGF2* overexpression has been consistently demonstrated in adult sporadic adrenocortical carcinomas. *IGF2* exerts its mitogenic effects through interaction with *IGF1R* (15). Almeida and cols. (10) reported overexpression of *IGF2* in both pediatric adrenocortical adenomas and carcinomas; on the other hand, *IGF1R* mRNA levels were significantly higher in childhood adrenocortical carcinomas. Both adrenocortical tumors reported here had a high expression of *IGF2* and *IGF1R*, but *IGF1R* expression was higher in the right tumor. Studies have demonstrated that antagonizing the IGF signaling pathway with pharmacological agents results in the inhibition of *in vitro* and *in vivo* tumor cell growth. This raises the prospect of using target disruption of the *IGF1R* signaling pathway as a therapeutic agent since this targeted inhibition was apparently more potent than the use of mitotane in xenograft growth (10,15).

Tissier and cols. (16) reported beta-catenin anomalous staining at the nucleus and/or cytoplasm in a high frequency of adult adrenocortical tumors, mainly in carcinomas. However, the pattern differed between these tumors. The abnormal beta-catenin immunostaining was focal in most adrenocortical adenomas and diffuse in adrenocortical carcinomas. Until now, there is little information in medical literature about the participation of the Wnt pathway in pediatric adrenocortical tumorigenesis. Pusantisampan T and cols. (17) reported a case of a child with metastatic adrenocortical carcinoma presenting a somatic mutation of beta-catenin. Recently, somatic activating mutations of the *CTNNB1* gene were associated as a poor prognostic factor in adult adrenocortical carcinomas (18). In the present case, neither abnormal beta-catenin staining, nor mutation in the exon 3 beta catenin gene was observed. The absence of this somatic molecular alteration might be related to the indolent behavior of the patient's tumors.

A previous microarray analysis of pediatric adrenocortical tumors demonstrated high of expression of *FGFR4* (19). In fact, an overexpression of *FGFR4* was observed in the tumors of the patient reported.

Surgical resection is the treatment of choice for patients with resectable primary and even metastatic lesions (6). In addition, adjuvant mitotane therapy may be given to patients in MacFarlane stage III and IV to increase the length of time between recurrences. Mitotane has a cytotoxic effect on adrenocortical cells and it is effective in controlling steroid excess in patients with secreting adrenocortical carcinoma; but patients often present symptoms due to the toxicity of this drug, which is largely related to mitotane blood levels. Mitotane has been extensively used in adults, but there is little knowledge of its efficacy and long-term effects in children. The role of chemotherapy in the management of adrenocortical carcinoma in children is not clear.

After surgical procedures the patient presented good evolution and to date he is receiving glucocorticoid and mineralocorticoid replacement. Puberty has developed at the expected age and the patient achieved the target high. It is important to emphasize that the cure achieved for this particular patient may be related to total resection of the tumors and also of the metastasis. Of note, there is a risk for recurrence even after 10-12 years and complete resection of both adrenocortical tumors and metastasis. Continued surveillance is still required. Also, we do not recommend this patient, being a carrier of the *TP53* mutation, to smoke or have contact with substances that might damage his DNA.

Disclosure: no potential conflict of interest relevant to this article was reported.

## REFERENCES

1. Ribeiro RC, Sandrini F, Figueiredo B, Zambetti GP, Michalkiewicz E, Lafferty AR, et al. An inherited p53 mutation that contributes in a tissue-specific manner to pediatric adrenal cortical carcinoma. *Proc Natl Acad Sci.* 2001;98(16):9330-5.
2. Latronico AC, Pinto EM, Domenice S, Fragoso MCBV, Martin RM, Zerbini MC, et al. An inherited mutation outside the highly conserved DNA-binding domain of the p53 tumor suppressor protein in children and adults with sporadic adrenocortical tumors. *J Clin Endocrinol Metab.* 2001;86(10):4970-3.
3. Almeida MQ, Latronico AC. The molecular pathogenesis of childhood adrenocortical tumors. *Horm Metab Res.* 2007;39:461-6.
4. Wieneke JA, Thompson LDR, Heffess CS. Adrenal cortical neoplasms in the pediatric population: a clinicopathologic and immunophenotypic analysis of 83 patients. *Am J Surg Pathol.* 2003;27(7):867-81.
5. Latronico AC, Chrousos GP. Extensive personal experience: adrenocortical tumors. *J Clin Endocrinol Metab.* 1997;82(5):1317-24.

6. Barlaskar FM, Hammer GD. The molecular genetics of adrenocortical carcinoma. *Rev Endocr Metab Disord.* 2007;8:343-8.
7. Bernard MH, Sidhu S, Berger N, Peix JL, Marsh DJ, Robinson BG, et al. A case report in favor of a multistep adrenocortical tumorigenesis. *J Clin Endocrinol Metabol.* 2003;88(3):998-1001.
8. Augbert S, Wacrenier A, Leroy X, Devos P, Carnaille B, Proye C, et al. Weiss system revisited: a clinicopathologic and immunohistochemical study of 49 adrenocortical tumors. *Ann J Surg Pathol.* 2002;26:1612-9.
9. Sullivan M, Boileau M, Hodges CV. Adrenal cortical carcinoma. *J Urol.* 1978;120:660-5.
10. Almeida MQ, Fragoso MCBV, Lofti CFP, Santos MG, Nishi MY, Costa MHS, et al. Expression of insulin-like growth factor-II and its receptor pediatric and adult adrenocortical tumors. *J Clin Endocrinol Metabol.* 2008;93(9):3524-31.
11. Brito LP, Lerario AM, Bronstein MD, Soares IC, Medonça BB, Fragoso MCBV. Influence of the fibroblast growth factor receptor 4 expression and the G388R polymorphism on cushing disease outcome. *J Clin Endocrinol Metabol.* 2010;95(10):E271-9.
12. Kikuchi A. Tumor formation by genetic mutations in the components of the wnt signaling pathway. *Cancer Sci.* 2003;94(3):225-9.
13. Libé R, Groussin L, Tissier F, Elie C, René-Corail F, Fratticci A, et al. Somatic TP53 mutations are relatively rare among adrenocortical cancers with the frequent 17p13 loss of heterozygosity. *Clin Cancer Res.* 2007;13(3):844-50.
14. Mendonca BB, Lucon AM, Menezes CAV, Saldanha LB, Latronico AC, Zerbini C, et al. Clinical, hormonal and pathological findings in a comparative study of adrenocortical neoplasms in childhood and adulthood. *J Urol.* 1995;154:2004-9.
15. Barlaskar FM, Spalding AC, Heaton JH, Kuick R, Kim AC, Thomas DG, et al. Preclinical targeting of the type I insulin-like growth factor receptor in adrenocortical carcinoma. *J Clin Endocrinol Metabol.* 2009;94(1):204-12.
16. Tissier F, Cavard C, Groussin L, Perlemoine K, Fumey G, Hagnère AM, et al. Mutations of beta-catenin in adrenocortical tumors: activation of the Wnt signaling pathway is a frequent event in both benign and malignant adrenocortical tumors. *Cancer Res.* 2005;65(17):7622-7.
17. Pusantisampan T, Sangkhathat S, Kanngurn S, Kayasut K, Jaruratanasirikul S, Chotsampancharoan T, et al. Cushing's syndrome in an infant secondary to malignant adrenocortical tumors with somatic mutation of beta-catenin. *Pediatric Dev Pathol.* 2009;13(3):238-42.
18. Ragazzon B, Libé R, Gaujoux S, Assié G, Fratticci A, Launay P, et al. Transcriptome analysis reveals that p53 and  $\beta$ -catenin alterations occur in a group of aggressive adrenocortical cancers. *Cancer Res.* 2010;70(21):8276-81.
19. West AN, Neale GA, Pounds S, Figueredo BC, Galindo CR, Pianovski MAD, et al. Gene expression profiling of childhood adrenocortical tumors. *Cancer Res.* 2007;67(2):600-8.