






Clinical bovine paratuberculosis - first report in the state of Pará

[Paratuberculose clínica bovina: primeiro relato no estado do Pará]

J.D. Barbosa¹ , A. Serruya² , A.M.C. Lins³ , C.M.C. Oliveira¹ , N.S.S. Silveira^{1*} 

¹Instituto de Medicina Veterinária, Universidade Federal do Pará, Castanhal, PA, Brasil

²Undergraduate, Universidade Federal do Pará, Castanhal, PA, Brasil

³Graduate, Universidade Federal do Pará, Castanhal, PA, Brasil

ABSTRACT

The objective of this work was to describe the clinical, pathological, and serological aspects of paratuberculosis in a bullock on dairy and beef farm in the municipality of Inhangapí, state of Pará. The animal was raised extensively and presented progressive weight loss, pale mucous membranes, and chronic diarrhea. A blood sample was collected for serology by the indirect ELISA technique. Due to the unfavorable prognosis, the animal was euthanized and necropsied. At necropsy, there was thickened and wrinkled intestinal mucosa, enlarged mesenteric lymph nodes and liquid intestinal contents with a brown color. Organ fragments were fixed in 10% buffered formaldehyde, embedded in paraffin wax, cut, and stained by hematoxylin and eosin and by Ziehl-Neelsen techniques. Histopathology showed intense granulomatous infiltration with Langhans giant cells in the lamina propria and submucosa of the small intestine, Peyer patches and mesenteric lymph nodes. Ziehl-Neelsen staining revealed many intralésional acid-fast bacilli. Antibody searching against *Mycobacterium avium* (subsp.) *paratuberculosis* was positive. The diagnosis of paratuberculosis was based on epidemiological, clinical, pathological, and serological data. This is the first report of clinical paratuberculosis, confirmed by pathology and serology, in a bullock in the state of Pará.

Keywords: *Mycobacterium avium* (subsp.) *paratuberculosis*, MAP, Johne's disease, progressive weight loss

RESUMO

Descrevem-se os aspectos clínicos, patológicos e sorológicos de paratuberculose diagnosticada em um bovino, no município de Inhangapi, estado do Pará, em uma propriedade de leite e corte. O bovino era criado extensivamente e apresentava emagrecimento progressivo, mucosas pálidas e diarréia crônica. Foi coletada amostra de sangue para realização da sorologia pela técnica de ELISA indireto. Em razão do prognóstico desfavorável, foi realizada a eutanásia e a necropsia do animal. À necropsia, observou-se mucosa do intestino espessada e enrugada, linfonodos mesentéricos aumentados de tamanho e conteúdo intestinal líquido e com coloração marrom. Fragmentos dos órgãos foram fixados em formalina 10%, incluídos em parafina, cortados e corados pelas técnicas de hematoxilina e eosina e Ziehl-Neelsen. Na histopatologia, havia intensa infiltração granulomatosa com células gigantes de Langhans na lâmina própria e submucosa do intestino delgado, placas de Peyer e linfonodos mesentéricos. A coloração de Ziehl-Neelsen revelou numerosos bacilos álcool-ácido resistentes intralésionais. A pesquisa de anticorpos anti-*Mycobacterium avium* (subsp.) *paratuberculosis* foi positiva. O diagnóstico da paratuberculose foi baseado nos dados epidemiológicos, clínicos, patológicos e sorológicos. Este é o primeiro relato de paratuberculose clínica, confirmada pela patologia e sorologia, em um bovino no estado do Pará.

Palavras-chave: *Mycobacterium avium* (subsp.) *paratuberculosis*, MAP, doença de Johne, emagrecimento progressivo

* Corresponding author: nataliasilva@ufpa.br

Submitted: January 9, 2023. Accepted: March 20, 2023.

INTRODUCTION

Paratuberculosis or Johne's Disease is a granulomatous enteritis caused by *Mycobacterium avium* subsp. *paratuberculosis* (Map), which can affect domestic and wild ruminants (Peek *et al.*, 2018). It is characterized by chronic and intermittent diarrhea, progressive weight loss, decreased production and increased susceptibility to other infections, lethargy, hypoproteinemia, cachexia, anemia, and eventual death (Tiwari *et al.*, 2006). Consequently, the economic losses associated with these clinical signs, especially in dairy cattle, include decreased milk production, premature culling and decrease in the animal's value at slaughter (Shephard *et al.*, 2016).

Johne's Disease is present worldwide and is considered a transmissible disease of socioeconomic and public health importance, whose control is necessary to the international trade of animals and animal products (Paratuberculosis, 2022). The importance of paratuberculosis is not restricted only to the economic losses caused by the animal industry, but also to the possible participation of Map in granulomatous ileocolitis that affects humans, known as Crohn's Disease (Paratuberculosis, 2022; Yamasaki *et al.*, 2013).

In Brazil, paratuberculosis is considered an emerging disease and has been reported in some ruminant species (Driemeier *et al.*, 1999; Yamasaki *et al.*, 2013). However, this disease is still neglected by the inspection agencies. This demonstrates the extreme importance of implementing measures to control the disease in the country, which would make it possible to improve the quality and value of products of animals in the international market (Yamasaki *et al.*, 2013).

In the state of Pará, there is only one serological study in dairy herds, where 35.4% of positive animals were detected (Silva, 2005). No reports were found in the literature about clinical disease in cattle herds at this state. Therefore, the objective of the present work is to report the first clinical case of bovine paratuberculosis in the state of Pará, Brazilian Amazon, describing the

clinical, pathological, and serological findings of the disease in one animal.

CASUISTRY

A four-year-old male, crossbred from Swiss Brown and Nelore, with a history of diarrhea and progressive weight loss for approximately two months, even with good forage availability, was examined. The studied farm had a high turnover of animals because it works with the purchase and sale of cattle and bullock had been there for one year, in a herd with over 80 animals, half made up of crossbred Gir x Holstein animals for milk production and half of crossbred Swiss Brown x Nelore for meat and milk production, raised together on *Urochloa (Brachiaria) brizantha* pasture and mineral supplementation in the trough. On the visit of the property, other animals with regular to poor nutritional status were observed, however, clinical signs of the disease were observed in only one animal of the herd.

Clinical examination showed apathy, difficulty in standing up, poor body condition (Fig. 1A), pale mucous membranes, reduced skin elasticity and eyeball retraction indicating dehydration, rough lackluster hair coat, diarrheal feces, and sometimes profuse and watery diarrhea (Fig. 1B). The feces were homogeneous, non-hemorrhagic and without mucus.

Epidemiological, clinical, and pathological data were obtained through visits to a farm located in the municipality of Inhangapi, northeast region in the state of Pará, Amazon, Brazil. Blood samples were collected by jugular venipuncture using vacuum tubes without anticoagulant. The serum was obtained by centrifugation (2500 × g, 5min) and stored in 2 ml polypropylene tubes at -20°C until laboratory procedures.

The sample was tested for anti-MAP antibodies by the indirect ELISA technique, using a commercial kit from the Pourquier Institute (IDEXX®) processed at the Department of Preventive Veterinary Medicine of the Universidade Federal de Minas Gerais. Plate reading was performed in an ELISA reader with an optical density of 450nm.



Figure 1. (A) Cattle in sternal decubitus with difficulty in standing up and poor body condition. (B) Cattle with profuse and watery diarrhea.

Due to the unfavorable prognosis, the animal was submitted to euthanasia and necropsy. Euthanasia was performed as prescribed by the rules of the National Council for the Control of Animal Experiments (CONCEA, Law N° 11.794, Oct 2008). Anesthesia was accomplished with sodium thiopental 1g (5mg/kg; 20ml dissolved in 5% sterile saline solution) administered intravenously (IV), followed by the application of 30mL of 2% lidocaine intrathecally (600mg). Fragments of several organs were collected, fixed in 10% buffered formaldehyde for histopathological studies in the Pathology Laboratory of the Universidade Federal do Pará. Tissue samples were routinely

processed, embedded in paraffin wax, cut into a microtome at 5µm thickness and stained with hematoxylin and eosin (HE) and with Ziehl-Neelsen staining.

The macroscopic finding at necropsy consisted of paler carcass, cerebroid and annular appearance of intestinal loops in some regions, enlarged mesenteric lymph nodes and prominent mesenteric lymphatic vessels (Fig. 2A). The mucosa of the small and large intestine was thickened, irregular, reticulated appearance and with very evident transverse folds, similar to cerebral circumvolutions (Fig. 2B). The intestinal contents were liquid and brownish.

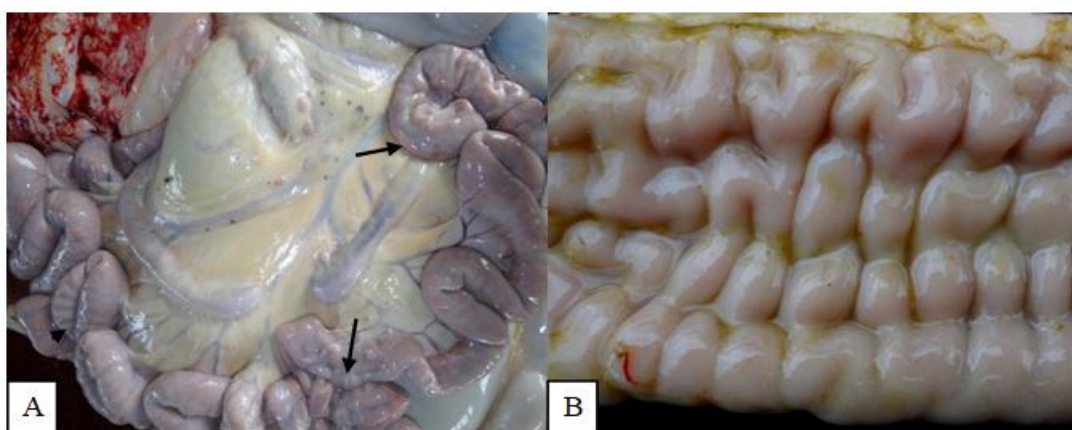


Figure 2. (A) Cerebroid (arrows) and annular (arrowhead) aspect of intestinal loops; enlarged mesenteric lymph nodes and prominent lymphatic vessels. (B) Small intestinal mucosa thickened reticulated appearance and with very evident transverse folds.

In histopathology, the main finding observed was in the small intestine and was characterized by a granulomatous inflammatory infiltrate, with many macrophages, epithelioid cells and Langhans giant cells, and a smaller number of lymphocytes, in the lamina propria, submucosa and Peyer's patches. In the mesenteric lymph nodes there was similar inflammation, however,

with moderate intensity. Ziehl-Neelsen staining of the small intestine highlighted numerous acid-fast bacilli (Fig. 3). Additionally, there was a light multifocal infiltration of macrophages with foamy cytoplasm in the liver. The search for anti-MAP antibodies by the indirect ELISA technique was positive.

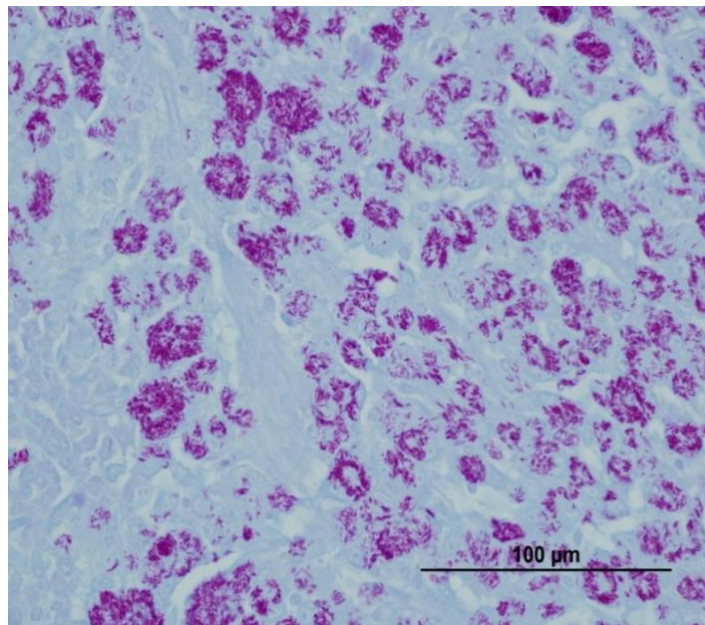


Figure 3. Large number of acid-fast bacteria within macrophages in the mucosa of the small intestine (Ziehl-Neelsen stain).

DISCUSSION

The diagnosis of paratuberculosis in bullock in this report was based on the clinical and pathological case of the disease, and was confirmed by serology, histopathological findings and the evidence of alcohol-acid resistant bacillus using the Ziehl-Neelsen technique. These diagnostic methods are classic in the face of suspicion of this disease and have already been used by several authors in Brazil and in several countries, since it is a cosmopolitan disease (Driemeier *et al.*, 1999).

The coexistence of the animal in a herd of dairy cows makes it more susceptible to paratuberculosis. The prevalence of this disease is higher in dairy cattle than in beef cattle, and it is considered by some authors to be a disease of dairy cattle, since the semi-intensive or intensive

production systems in which there is greater contamination by feces contributes to the spread of infection among animals (Nielsen & Toft, 2008).

This bullock was the only one in the herd to show clinical signs of paratuberculosis, which is probably due to the chronicity of the disease. The slow development of the disease, which occurs inconspicuously, and the prolonged transition between stages of infection make it difficult to detect all infected animals in the herd (Manning and Collins, 2010).

According to Nielsen and Toft (2008), approximately 10% of cattle in a herd develop clinical disease, while the others remain without clinical signs throughout life, but shed the agent through feces. Estimates suggest that in a herd, up to 70% of animals can be infected (Timms *et*

al., 2011). Studies estimate that for each animal with advanced disease, there would be two animals in the clinical stage, four to eight in the subclinical stage and ten to fourteen in the silent stage (Stabel, 2006). Although the herd has not been tested for the diagnosis of infection, it is believed that other animals are affected and that they may also present the clinical form of paratuberculosis. It was not possible to carry out the serological examination of the herd because, when the diagnosis of the animal was obtained, the animals had been sold and were not found.

Clinical signs such as progressive weight loss, dehydration, homogeneous and non-hemorrhagic feces, without mucus and with bubbles gas were also found by other authors in cattle with paratuberculosis (Fiss *et al.*, 2015; Driemeier *et al.*, 1999).

The intestinal mucosa thickened, irregular and reticulated with very evident transverse folds showed in the present study, was also observed in other studies (Fiss *et al.*, 2015; Driemeier *et al.*, 1999). It is described as a characteristic lesion of Johne's Disease in the necropsy findings.

The histopathological examination allowed the diagnosis of diffuse and accentuated granulomatous enteritis and lymphadenitis, with many intralesional acid-fast bacilli. These findings are considered characteristic of the disease (Peek *et al.*, 2018). Some authors have reported multifocal granulomatous hepatitis, observing acid-fast bacilli (AFB) associated with inflammatory infiltrate (Driemeier *et al.*, 1999). In our study, the focus of mononuclear inflammatory infiltrate was observed in the liver, however, AFBs were not visualized.

CONCLUSIONS

This is the first report of clinical paratuberculosis, confirmed by pathology and serology, in a bullock in the state of Pará. This diagnosis shows that further studies are needed to assess the impact of paratuberculosis on herds in the Amazon Biome.

REFERENCES

- DRIEMEIER, D.; CRUZ, C.E.F.; GOMES, J.P.P. *et al.* Aspectos clínicos e patológicos da paratuberculose em bovinos no Rio Grande do Sul. *Pesqui. Vet. Bras.*, v.19, p.109-115, 1999.
- FISS, L.; SANTOS, L.; ALBUQUERQUE, P.P.F. *et al.* Paratuberculose em bovinos de corte na região Sul do Rio Grande do Sul. *Pesqui. Vet. Bras.*, v.35, p.437-442, 2015.
- MANNING, E.J.B.; COLLINS, M.T. Epidemiology of paratuberculosis. *Paratuberculosis Organ. Dis. Control.*, p.22-28, 2010.
- NIELSEN, S.S.; TOFT, N. Ante mortem diagnosis of paratuberculosis: A review of accuracies of ELISA, interferon- γ assay and faecal culture techniques. *Vet. Microbiol.*, v.129, p.217-235, 2008.
- PARATUBERCULOSIS. 2022. Available in: <https://www.woah.org/en/disease/paratuberculosis/>. Accessed in: 30 Oct. 2022.
- PEEK, S.F.; MCGUIRK, S.M.; SWEENEY, R.W.; CUMMINGS, K.J. Infectious diseases of the gastrointestinal tract. *Rebhun's Dis. Dairy Cattle*, p.249-356, 2018.
- SHEPHARD, R.; WILLIAMS, S.; BECKETT, S. Farm economic impacts of bovine Johne's disease in endemically infected Australian dairy herds. *Aust. Vet. J.*, v.94, p.232-239, 2016.
- SILVA, E.B. *Diagnóstico da paratuberculose em bovinos de corte do Estado do Pará, Brasil*. 2005. 65f. Dissertação (Mestrado em Ciência Animal) – Núcleo de Ciências Agrárias, Universidade Federal Rural de Amazônia.
- STABEL, J.R. Host responses to *Mycobacterium avium* subsp. *paratuberculosis*: a complex arsenal. *Anim. Health Res. Rev.*, v.7, p.61-70, 2006.
- TIMMS, V.J.; MITCHELL, H.M.; GEHRINGER, M.M. *et al.* How accurately can we detect *Mycobacterium avium* subsp. *paratuberculosis* infection? *J. Microbiol. Methods*, v.85, p.1-8, 2011.
- TIWARI, A.; VANLEEUEWEN, J.A.; MCKENNA, S.L.B. *et al.* Johne's disease in Canada: Part 1: Clinical symptoms, pathophysiology, diagnosis, and prevalence in dairy herds. *Can. Vet. J.*, v.47, p.874-882, 2006.
- YAMASAKI, E.M.; BRITO, M.F.; MCINTOSH, D. *et al.* Diagnóstico imuno-histopatológico da paratuberculose subclínica em bovinos no estado do Rio de Janeiro. *Pesqui. Vet. Bras.*, v.33, p.1427-1432, 2013.