

## The influence of nicotine on the population of fibroblasts in cutaneous scars in rats<sup>1</sup>

### A influência da nicotina na população de fibroblastos em cicatrizes cutâneas de ratos

Maria de Lourdes Pessole Biondo-Simões<sup>I</sup>, Natali Weniger Spelling<sup>II</sup>, Sérgio Issamu Ioshii<sup>III</sup>, Rachel Biondo-Simões<sup>IV</sup>, João Carlos Domingues Repka<sup>V</sup>

<sup>I</sup> PhD, Research Methods, PUCPR and Associate Professor, Experimental Surgery, Department of Surgery, UFPR, PR, Brazil.

<sup>II</sup> Graduate Student, Scientific Initiation Program, Scholarship Araucaria Foundation, PUCPR, PR, Brazil.

<sup>III</sup> PhD, Full Professor, Division of Pathology, PUCPR and Associate Professor, Division of Pathology, UFPR, PR, Brazil.

<sup>IV</sup> Graduate Student, Scientific Initiation Program, PUCPR, PR, Brazil.

<sup>V</sup> PhD, Pasteur Institute, France, Immunologist at Angelina Caron Hospital, PR, Brazil.

---

#### ABSTRACT

**Purpose:** To study the collagen density and the population of fibroblasts in cutaneous injuries in rats under the influence of nicotine. **Methods:** The scars of abdominal wounds in rats were analyzed. 2 mg/kg/d of nicotine was administered to the animals in the experiment group and the solution used as a vehicle for the animals in the control group. Treatment was begun seven days prior to surgery and maintained for seven or fourteen days following surgery. The removed scars were prepared for histopathological study. Histological cuts were stained by Sirius Supra red F3BA for collagen analysis and submitted to the examination using the immunohistochemical technique, which enabled us to recognize the population of fibroblasts. **Results:** No significant difference was found in type I collagen density after seven days ( $p=0.912$ ), nor after fourteen days ( $p=0.211$ ). The control group had more type III collagen after seven days ( $p=0.004$ ), but after fourteen days there was no significant difference ( $p=0.720$ ). The total quantification of collagen, although higher in the control group, was not significantly so at any time during the study ( $p=0.103$  after seven days and  $p=0.549$  after fourteen days). The average of fibroblasts per field was lower after seven days ( $p=0.0001$ ) and after fourteen days ( $p=0.0000$ ). **Conclusion:** Under the conditions of this experiment, nicotine reduced the fibroblast population without modifying collagen density significantly.

**Key words:** Wound Healing. Collagen. Fibroblasts. Nicotine. Tobacco. Rats.

---

#### RESUMO

**Objetivo:** Estudar a densidade de colágeno e a população de fibroblastos em feridas cutâneas de ratos sob a influência da nicotina. **Métodos:** Analisaram-se as cicatrizes de feridas abdominais de ratos. Foi administrada 2 mg/kg/d de nicotina, por via subcutânea aos animais do grupo experimento e a solução usada como veículo para os animais do grupo controle. O tratamento foi iniciado sete dias antes do ato operatório e mantido por sete ou quatorze dias no pós-operatório. As cicatrizes ressecadas foram preparadas para estudo histo-patológico. Cortes histológicos foram corados pelo Sirius Supra red F3BA para a análise do colágeno e submetidos à exame pela técnica imuno-histoquímica permitiram reconhecer a população de fibroblastos. **Resultados:** Verificou-se que não existiu diferença significativa na densidade de colágeno tipo I, na avaliação feita com sete dias ( $p=0,912$ ) e com 14 dias ( $p=0,211$ ). O grupo controle mostrava mais colágeno tipo III com sete dias ( $p=0,004$ ), mas aos 14 dias não havia diferença significativa ( $p=0,720$ ). A quantificação do colágeno total, embora fosse maior no grupo controle, não o foi de forma significativa em nenhum dos tempos estudados ( $p=0,103$  aos sete dias e  $p=0,549$  aos 14 dias). A média de fibroblastos por campo esteve diminuída na avaliação de sete dias ( $p=0,0001$ ) e na de quatorze dias ( $p=0,0000$ ). **Conclusão:** Nas condições do experimento, a nicotina promoveu diminuição da população de fibroblastos sem modificar a densidade do colágeno de forma significativa.

**Descritores:** Cicatrização de Feridas. Colágeno. Fibroblastos. Nicotina. Tabaco. Ratos.

---

<sup>1</sup>Research performed at the Division of Research, School of Medicine, Pontific Catholic University of Parana (PUCPR), Brazil.

#### Introduction

The healing of wounds is the sequence of cellular and molecular events that lead to the reconstitution of damaged tissues. It is a dynamic process involving biochemical and physiological phenomena<sup>1</sup>.

Impaired healing has been attributed to smoking. Mosely and Finseth<sup>2</sup> were the first researchers to describe the harmful effects of smoking on the healing of wounds, when they reported the impaired healing of the hand of a female smoker.

Several authors have published the deleterious effects of smoking on healing. Rees *et al.*<sup>3</sup> found that patients who smoke

have a 12.46 times greater chance of developing ischemic skin flaps when undergoing plastic surgery to the face. Reus *et al.*<sup>4</sup> studying patients with free skin grafts observed that smokers had significant ischemia ( $p=0.03$ ) at the graft edges. Sorensen *et al.*<sup>5,6</sup> monitored a group of patients who had been submitted to a laparotomy to treat gastro-intestinal diseases and found that smokers developed incisional hernias four times more than non-smokers. In another report, they followed a group of patients who had undergone an inguinal herniorrhaphy and found that smokers were 2.22 times more likely to suffer a relapse. Kasperk *et al.*<sup>7</sup>, making a univariate and multivariate analysis of variables related to colon and rectal anastomotic dehiscence found that smoking was an independent variable.

Nicotine is the most active component in tobacco. It is a tertiary amine composed of pyridine and pyrrolidine rings. There are stereoisomeric racemic mixtures of a three-dimensional structure. In tobacco, two are permanently present: L-nicotine and D-nicotine. L-nicotine is a hundred times more active than D-nicotine and constitutes 90% of the total<sup>8</sup>.

Nicotine is known to cause vasoconstriction<sup>9</sup>. Consequently, it reduces the blood flow and partial pressure of oxygen on tissues. Oxygen is a necessary substrate for proline and lysine hydroxylation in collagen synthesis, essential for the formation of fibrils and for the stability of the triple helix of the molecule, which results in resistance to scarring<sup>10</sup>.

Several experimental studies have reported cytoplasmatic modifications, degeneration and inactivity of fibroblasts<sup>11-13</sup>, in addition to a reduced number of these cells and their differentiation<sup>11,12,14-17</sup> and deficiencies in collagen synthesis<sup>11,13,15,18,19</sup>.

Recently, when studying healing in the bladders of rats, Machado found no significant differences in collagen I and II concentrations, and Balatsouka *et al.*<sup>21</sup>, when studying bone restoration, also found no alterations in collagen concentration. Marimoto *et al.*<sup>22</sup> found that nicotine in small doses induces angiogenesis and accelerated wound healing.

The aim of this study is to study the deposition of collagen and recognize the fibroblast population in cutaneous wounds under the influence of nicotine.

## Methods

The project for this study was evaluated and approved by the Ethics Committee for the Use of Animals in experiments at the PUC University (Pontificia Universidade Católica) and was allotted Registration Number 117 and its sub-project was allotted Number 237. Throughout the study, the guidelines of the Brazilian Animal Experiments College (COBEA) were followed.

Forty male Wistar rats (*Rattus norvegicus albinus*, *Rodentia mammalia*) aged 200-220 days and weighing  $285 \pm 54$  grams, were divided at random into two groups: experiment and control. The animals in the experiment group were given 2mg de nicotine/Kg/day, diluted in 0.3 ml of physiological solution at 0.9%, adjusted to pH 7.4. The dose was divided and administered twice daily, at 7:00 and 19:00, applied sub-cutaneously to the dorsum. The control group was given only the watery solution in a phosphate buffer, pH 7.4. The treatment was begun seven days prior to the surgical procedure and was continued up to the day of euthanasia.

A solution composed of 1ml of ketamine (50mg) and 1ml of xylazine (20mg) was used as an anesthetic and applied in the form of an intra-muscular injection at the back of the right thigh at a ratio of 0.1ml/100g. The trichotomy was done, followed by anti-sepsis of the ventral abdominal wall with iodine-polyvinylpyrrolidone. An incision of approximately two centimeters was made in the infra-umbilical abdominal wall, and synthesis with three separate stitches of 5.0 monofilament nylon thread.

Immediately following the surgery, the animals were given a single intra-muscular 10mg/kg dose of potassium diclophenac as an anesthetic and anti-inflammatory. Once they had recuperated, they were returned to their boxes and given free access to water and feed.

Ten rats from each group were selected at random for euthanasia on the seventh and fourteenth days following surgery. They were given a lethal intra-peritoneal dose of sodium thiopental (120mg/kg).

A three-centimeter segment of the skin was removed from the side containing the scar on the central part. The flap was extended on filter paper and submerged in formalin for the setting and later processing for histopathological study.

Cuts were made in the two paraffin blocks containing the material. The cuts were four centimeters in thickness. Placed on blades, they were submitted to picosirius staining<sup>23</sup>. In the analysis, the thicker and doubly refracting (birefringent) collagen fibers were reddish orange in hue (collagen I); the thinner, weakly birefringent fibers were greenish (collagen III)<sup>33</sup>. The images were captured by a Sony® CCD101 camera and transmitted to a Sony Trinitron® color monitor, frozen and digitalized through an Oculus® TCX frame grabber. The images were analyzed using Image-Plus® 4.5 for Windows® from MediaCybernetics on a Pentium microcomputer. Five fields at 200x magnification on the line of the scar were analyzed. In each field, the percentage of the area occupied by red and yellow fibers (collagen I) was calculated, along with the green fibers (collagen III)<sup>23</sup>. Considering that other types of collagen constitute very small fractions for practical means, the sum of collagens I and III was considered the total collagen of the scar.

The areas of interest on the blades examined were demarcated for later removal of the block and the conducting of new blade tests by the tissue array or micro array process. The cuts were submitted to the immuno-histochemical technique through the streptavidin-biotin method. The antibody used was the anti-vimentin diluted at a ratio of 1:50 and incubated for 120 minutes. The cuts were exposed to the secondary antibody and the revealing complex at 1:1000. 0.03% diaminobenzidine was used as a chromogen for revelation of the reaction and counter-staining was done using Mayer's hematoxylin. Analyzed at two fields per cut with 400x magnification, a stellate cell was considered positive when the cytoplasm was of a brownish color.

The results obtained were expressed as averages, standard deviations, medians, minimum and maximum values or frequencies and percentages. For comparison of the groups in relation to quantitative variables, the non-parametric Mann-Whitney test was used. For parametric values, the student-*t* test was used. Values of  $p<0.05$  indicated statistical significance. The data were organized on an Excel flowchart and analyzed with the help of the Statistica 8.0 computer program.

**Results**

There was no loss of sample during the study.

The collagen density analysis for the evaluation carried out after seven days showed an average value of  $52.66 \pm 14.08$  for the control group and  $43.81 \pm 7.12$  for the experiment group

( $p=0.105$ ). When analyzed after fourteen days, the control group's average was  $60.96 \pm 13.71$  and the experiment group's was  $55.38 \pm 8.47$  ( $p=0.549$ ). Although the scars of the control group had more collagen than the experiment group, the difference was not significant (Figure 1).

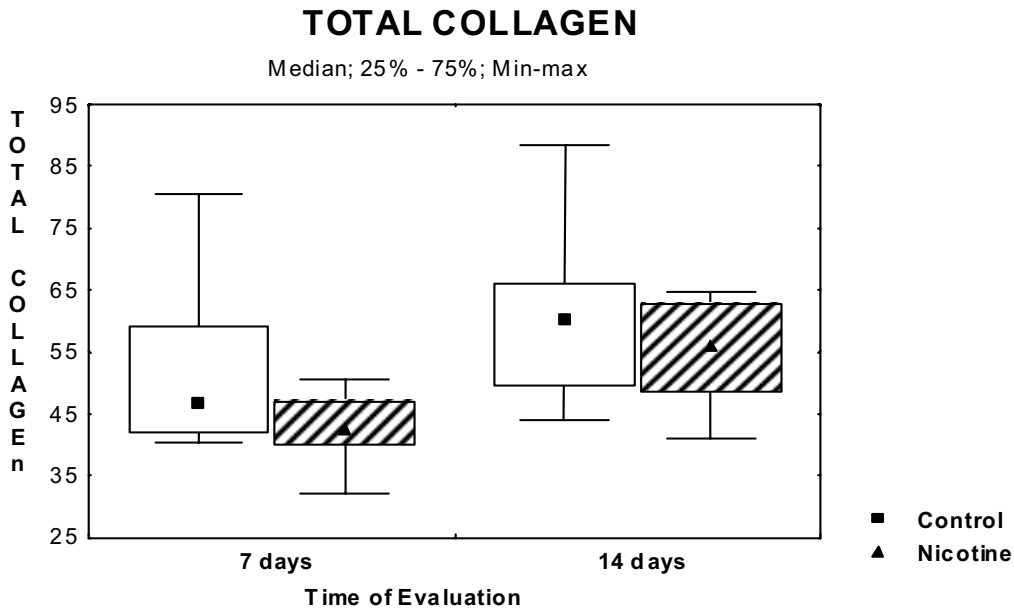


FIGURE 1 – Total collagen value, average and standard deviation

The quantification of collagen I, although higher in the control group, was not significantly so at any time during the study

( $p=0.912$  after seven days and  $p=0.211$  after fourteen days) (Figure 2).

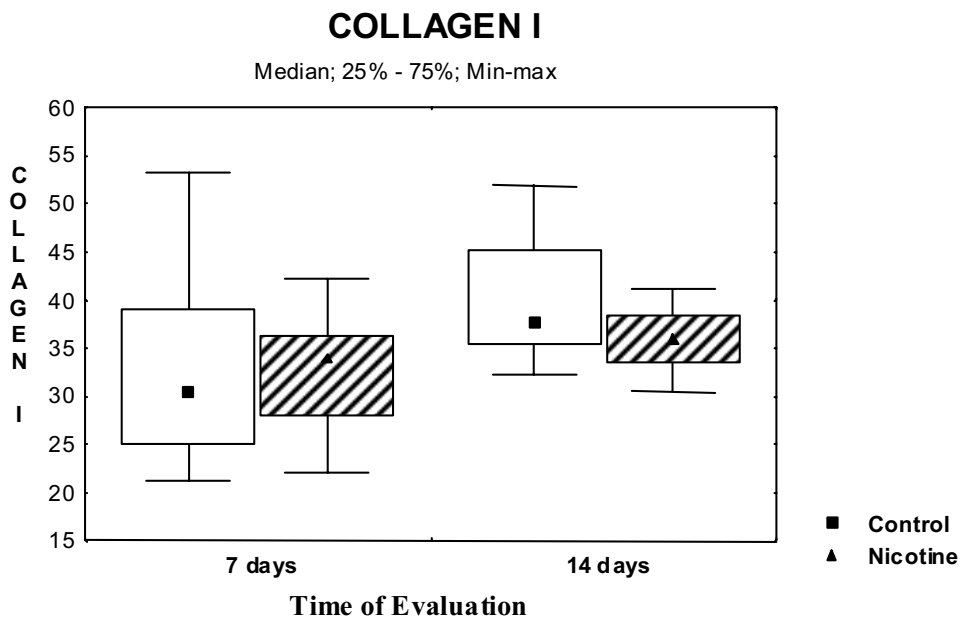


FIGURE 2 – Results of the collagen I evaluation, averages and standard deviations

The control group had more collagen III after seven days ( $p=0.004$ ), but after fourteen days there was no significant difference ( $p=0.720$ ) (Figure 3).

The average number of fibroblasts per field was lower in the scars of animals treated with nicotine at both times studied (Table 1).

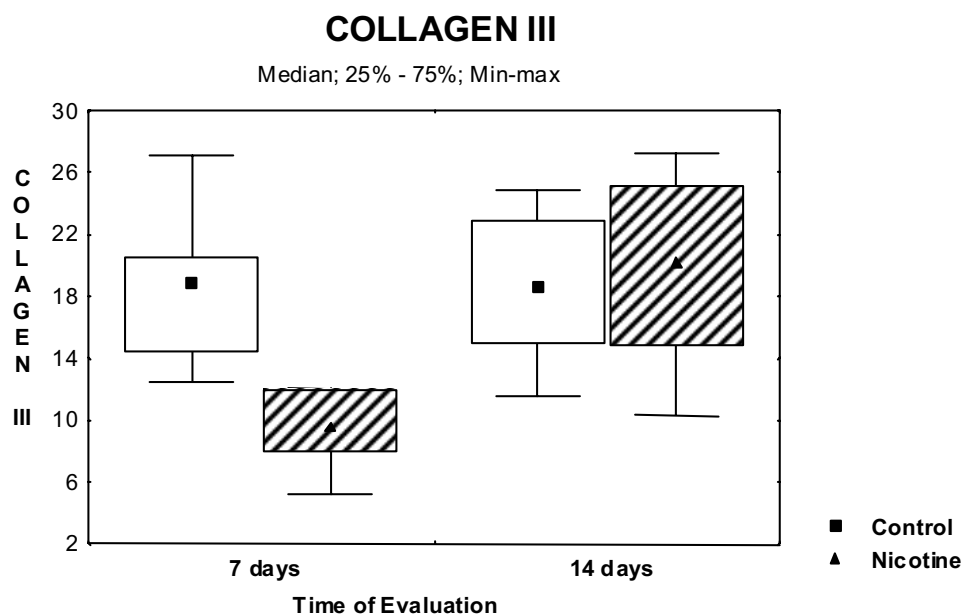


FIGURE 3 – Results of the collagen III evaluation, averages and standard deviations

TABLE 1- Result of the average number of fibroblasts per field in scars from the two groups at both evaluations

Time of Evaluation	Group	n	Average	Minimum	Maximum	Standard Deviation	P value
7 days	Control	10	19.5	15	25	2.88	0.0001
	Nicotine	10	12.1	10	17	2.18	
14 days	Control	10	19.1	16	25	2.96	0.0000
	Nicotine	10	13.2	10	16	1.87	

### Discussion

Several authors have reported the consequences of nicotine on fibroblasts. Silverstein pointed out the deleterious effects of nicotine not only lowering the number of fibroblasts but the number of macrophages<sup>16</sup>. Bosco *et al.*<sup>14</sup>, in a study conducted on rats, reported that under the influence of nicotine, the number of these cells in healing wounds fell. Tipton and Dabbous<sup>11</sup> exposed fibroblast cultures to different concentrations of nicotine. They reported reduced proliferation of these cultures in proportion to the concentration they were exposed to. Giannopoulou *et al.*<sup>12</sup> studied the multiplication of fibroblasts exposed to nicotine and found that this substance was capable of reducing replication, in proportion to the concentration, and even inhibit it. They also reported that under the influence of nicotine the migration of these cells was inhibited.

According to some of these authors, fibroblasts exposed to nicotine undergo morphological alterations, principally cytoplasmic vacuolization. They become inactive and even unviable<sup>11-13,17</sup>.

In some studies, the collagen concentration in wounds that are healing has reduced<sup>11,15,22</sup>. According to Galatz *et al.*<sup>19</sup>, under the influence of nicotine, there would be a lower RNA expression for type I collagen and Tipton and Dabbous<sup>11</sup> found a higher concentration of collagenases. Furthermore, Knuutinen *et al.*<sup>18</sup> found alterations in the extracellular matrix, especially of the metalloproteinases, which alone would be enough to hinder the healing process. However, there is no consensus concerning the

fact that under the influence of nicotine there is a reduction in collagen synthesis. Machado *et al.*<sup>20</sup>, studying the healing of rabbit bladders, found no changes to collagen density in the scars.

In this study, although the fibroblast population was reduced in the scars of the animals exposed to nicotine, there was no significant difference in collagen concentration, although the collagen density of the control group was lower. Nevertheless, the fibroblast population was smaller in the group treated with nicotine at both times of evaluation. In this study, the animals began treatment with nicotine one week before the lesion was caused. Marimoto *et al.*<sup>22</sup> observed that low doses of nicotine induce angiogenesis and improve healing. Longer exposure could possibly lead to lower densities. Cucina *et al.*<sup>24</sup> reported that under treatment with nicotine there would be a change in the expression of several proteins, among them the basic fibroblast growth factor (bFGF) and the transforming growth factor beta-1 (TGF-β1), factors related to the chemotaxis and replication of fibroblasts. This may account for the reduced number of these cells, but perhaps there was not enough time to cause morphological and physiological changes.

Nicotine causes vasoconstriction and thus reduces the partial pressure of oxygen on tissues, stimulating angiogenesis, in addition to monocytes<sup>25,26</sup>. If the dose and time of exposure have not been sufficient to reach cytotoxic levels, bearing in mind that collagen synthesis is dependent on oxygen, that would explain why, even with the reduced the number of fibroblasts, the collagen synthesis has not been compromised.

## Conclusion

The analysis of the results leads to the conclusion that, in experimental conditions, nicotine causes a reduction in the fibroblast population, although without significantly modifying collagen density.

## References

1. Mandelbaum SH, Di Santis EP, Mandelbaum MHS. Cicatrização: conceitos atuais e recursos auxiliares – Parte I. *An Bras Dermatol*. 2003; 78(4):393-410.
2. Mosely LH, Finseth F. Cigarette smoking: impairment of digital blood flow and wound healing in the hand. *Hand*. 1977; 9(2):97-101.
3. Rees TD, Liverett DM, Guy CL. The effect of cigarette smoking on skin-flap survival in the face lift patient. *Plast Reconstr Surg*. 1984; 73(6):911-5.
4. Reus WF, Colen LB, Straker DJ. Tobacco smoking and complications in elective microsurgery. *Plast Reconstr Surg*. 1992; 89(3):490-4.
5. Sorensen LT, Hemmingsen UB, Kirkeby LT, Kallehave F, Jorgensen LN. Smoking is a risk factor for incisional hernia. *Arch Surg*. 2005; 140(2):119-23.
6. Sorensen LT, Friis E, Jorgensen T, Vennits B, Andersen BR, Rasmussen GI, Kjaergaard J. Smoking is a risk factor for recurrence of groin hernia. *World J Surg*. 2002; 26(4):397-400.
7. Kasperk R, Philipps B, Vahrmeyer M, Willis S, Schumpelick V. Risk factors for anastomosis dehiscence after very deep colorectal and coloanal anastomosis. *Chirurg*. 2000; 71(11):1365-9.
8. Rosenberg J. Nicotina: droga universal. Disponível em: <http://www.inca.gov.br/tabagismo/publicacoes/nicotina.pdf> Acesso em 07 Apr 2008.
9. Haustein KO. Smoking tobacco, microcirculatory changes and the role of nicotine. *Int J Clin Pharmacol Ther*. 1999; 37(2):76-85.
10. Wicke C, Halliday BJ, Scheuenstuhl H, Foree EF, Hunt TK. Examination of expanded polytetrafluoroethylene wound healing models. *Wound Repair Regen*. 1995; 3(3):284-91.
11. Tipton DA, Dabbous MK. Effects of nicotine on proliferation and extracellular matrix production of human gingival fibroblasts in vitro. *J Periodontol*. 1995; 66(12):1056-64.
12. Giannopoulou C, Geinoz A, Cimasoni G. Effects of nicotine on periodontal ligament fibroblasts in vitro. *J Clin Periodontol*. 1999; 26(1):49-55.
13. Duygulgu F, Karaoglu S, Zeybek ND, Kaymaz FF, Günes T. The effect of subcutaneously injected nicotine on achilles tendon healing in rabbits. *Knee Surg Sports Traumatol Arthrosc*. 2006; 14(8):756-61.
14. Bosco AF, Okamoto T, Nagata MJH, Machado GJR. Efeitos da nicotina no processo de reparo de feridas cutâneas associadas à aplicação tópica de clorexedine. *Rev Odonto Cienc*. 2004; 19(45):207-13.
15. Medeiros AC, Lima FP, Dantas Filho AM, Melo NMC, Azevêdo ÍM. A nicotina atua como fator deletério na reparação da parede abdominal. *Acta Cir Bras*. 2003; 18(Supl 1):19-23.
16. Silverstein P. Smoking and wound healing. *Am J Med*. 1992; 93(1A):22S-4.
17. Martinez AET, Silvério KG, Rossa Júnior C. Efeito da nicotina na viabilidade e morfologia de fibroblastos – estudo *in vitro*. *Pesq Odontol Bras*. 2002; (163):234-8.
18. Knuutinen A, Kokkonen N, Risteli J, Vähäkangas K, Kallioinen M, Salo T, Sorsa T, Oikarinen A. Smoking affects collagen synthesis and extracellular matrix turnover in human skin. *Br J Dermatol*. 2002; 146(4):588-94.
19. Galatz LM, Silva MJ, Rothermich SY, Zaegel MA, Havlioglu N, Thomopoulos S. Nicotine delays tendon-to-bone healing in a rat shoulder model. *J Bone Joint Surg Am*. 2006; 88(9):2027-34.
20. Machado C, Chin EWK, Ioshii SO, Tâmbara Filho R, von Bathen A. Influence of nicotine on healing of vesical sutures in rabbits. *Acta Cir Bras*. 2007; 22(6): 479-84.
21. Balatsouka D, Gotfredsen K, Sorensen L, Lindh CH, Berglundh T. Effect of systemic administration of nicotine on healing in osseous defects. An experimental study in rabbits. Part II. *Clin Oral Implants Res*. 2006; 17(5):488-94.
22. Morimoto N, Takemoto S, Kawazoe T, Suzuki S. Nicotine at a low concentration promotes wound healing. *J Surg Res*. 2008; 145(2):199-204.
23. Junqueira LC, Cossemelli W, Bretani R. Differential staining of collagen type I, II and III by sirius red and polarization microscopy. *Arch Histol. Jpn* 1978; 41(3):267-74.
24. Cucina A, Sapienza P, Corvino V, Borrelli V, Mariani V, Randone B, Santoro D'Angelo L, Cavallaro A. Nicotine-induced smooth muscle cell proliferation is mediated through bFGF and TGF-beta 1. *Surgery*. 2000; 127(3):316-22.
25. Macklin KD, Maus AD, Pereira EF, Albuquerque EX, Conti-Fine BM. Human vascular endothelial cells express functional nicotinic acetylcholine receptors. *J Pharmacol. Exp Ther*. 1998; 287(1):435-9.
26. Melkonian G, Le C, Zheng W, Talbot P, Martins-Green M. Normal patterns of angiogenesis and extracellular matrix deposition in chick chorioallantoic membranes are disrupted by mainstream and sidestream cigarette smoke. *Toxicol Appl Pharmacol*. 2000; 163(1):26-37.

Conflict of interest: none

Financial Source: PIBIC – Araucaria Foundation

## Correspondence:

Maria de Lourdes Pessole Biondo-Simões

Rua Ari José Valle, 1987,

82030-000 Curitiba - PR Brazil

Phone: (55 41)3297-4359/3223-4637/9991-5566

[biondo@avalon.sul.com.br](mailto:biondo@avalon.sul.com.br)

Received: April 08, 2009

Review: June 12, 2009

Accepted: July 29, 2009

## How to cite this article

Biondo-Simões MLP, Spelling NW, Ioshii SI, Biondo-Simões R, Repka JCD. The influence of nicotine on the population of fibroblasts in cutaneous scars in rats. *Acta Cir Bras*. [serial on the Internet] 2009 Nov-Dec;24(6). Available from URL: <http://www.scielo.br/acb>