

Study on adhesion formation and the healing of colon anastomosis in rats with induced peritoneal sepsis¹

Estudo da formação de aderências e da cicatrização de anastomoses colônicas em ratos com sepse peritoneal induzida

Silvana Marques e Silva¹, Marcos Vinícius Melo de Oliveira^{II}, Alexandre Malta Brandão^{II}, Fabiana Pirani Carneiro^{III}, Vânia Maria Moraes Ferreira^{IV}, Rogério Serafim Parra^V, Omar Feres^{VI}, João Batista de Sousa^{VII}

^IFellow PhD degree, Program in Medical Sciences, School of Medicine, UnB, Brasília-DF, Brazil. Responsible for intellectual and scientific content of the study, designed the protocol, involved with technical procedures, acquisition and interpretation of data, statistical analysis, critical revision and manuscript writing.

^{II}Graduate student, School of Medicine, UnB, Brasília-DF, Brazil. Involved with technical procedures, acquisition and interpretation of data and statistical analysis.

^{III}PhD, Associate Professor of Pathology, School of Medicine, UnB, Brasília-DF, Brazil. Macroscopic and histopathological examinations, interpretation of data and critical revision.

^{IV}Associate Professor, Pharmaceutical Sciences, School of Health Sciences, UnB, Brasília-DF, Brazil. Designed the protocol, involved with interpretation of data and critical revision.

^VFellow Master degree, Department of Surgery and Anatomy, FMRP-USP, Ribeirão Preto-SP, Brazil. Critical revision.

^{VI}PhD, Assistant Professor, Division of Coloproctology, Department of Surgery and Anatomy, FMRP-USP, Ribeirão Preto-SP, Brazil. Designed the protocol, involved with interpretation of data and critical revision.

^{VII}PhD, Associate Professor, Surgical Clinics, School of Medicine, UnB, Brasília-DF, Brazil. Responsible for intellectual and scientific content of the study; designed the protocol, involved with technical procedures, interpretation of data, critical revision and manuscript writing.

ABSTRACT

PURPOSE: To evaluate the effects of abdominal sepsis on adhesion formation and colon anastomosis healing in rats.

METHODS: Forty rats were distributed in two groups containing 20 rats each for left colon anastomosis in the presence (Group S) or absence (Group N) of induced sepsis by cecal ligation and puncture. Each group was divided into subgroups for euthanasia on the third (N3 and S3) or seventh (N7 or S7) post-operative day. The amount of adhesions was evaluated and a segment of the colon was removed for histopathologic analysis, bursting strength assessment, hydroxyproline and the determination of tissue collagen.

RESULTS: The subjects which underwent cecal ligation and puncture presented a higher amount of intra-abdominal adhesions in both third ($p=0,00$) and seventh ($p=0,00$) post-operative days. Smaller bursting strengths were found in the S3 subgroup, and greater bursting strengths were found in the S7 subgroup. There was no difference in the variations on the concentrations of hydroxyproline, tissue collagen and histopathology.

CONCLUSIONS: The peritoneal infection which was developed by cecal ligation and puncture raised the amount of intra-cavitary adhesions. There was a decrease in the amount of colonic anastomosis on the third post-operative day with a following raise on the seventh without any effects on other healing parameters.

Key words: Anastomosis, Surgical. Colon. Sepsis. Tissue Adhesions. Rats.

RESUMO

OBJETIVO: Avaliar os efeitos da sepse abdominal sobre a formação de aderências e a cicatrização de anastomoses colônicas em ratos.

MÉTODOS: 40 ratos distribuídos em dois grupos contendo 20 animais, para anastomose do cólon esquerdo na presença (grupo S) ou ausência (grupo N) de indução de sepse por ligadura e punção do ceco (CLP). Cada grupo foi dividido em subgrupos para eutanásia no terceiro (N3 e S3) ou sétimo (N7 e S7) dia de pós-operatório (DPO). Foi avaliada a quantidade de aderências e removido um segmento colônico contendo a anastomose para análise histopatológica, força de ruptura, hidroxiprolina e conteúdo de colágeno tecidual.

RESULTADOS: Os animais submetidos à CLP apresentaram maior quantidade de aderências intra-abdominais tanto no 3º DPO ($p=0,00$) quanto no 7º DPO ($p=0,00$). Tiveram menores valores de força de ruptura no 3º DPO ($p=0,00$), porém maiores valores no 7º DPO ($p=0,00$). Não houve diferença na variação da concentração de hidroxiprolina, conteúdo de colágeno e histopatologia.

CONCLUSÕES: A infecção peritoneal desencadeada por CLP aumentou a quantidade de aderências intra-cavitárias. Houve diminuição da resistência de anastomoses cólicas no 3º DPO, com posterior aumento no 7º DPO, sem efeito sobre os outros parâmetros da cicatrização.

Descritores: Anastomose Cirúrgica. Cólon. Sepse. Aderências Teciduais. Ratos.

Introduction

Anastomosis dehiscence is a potential complication in colo-rectal surgery. It has a variable incidence from 2.4 to 3.8% of cases. It is the most serious complication of such surgical procedure and is associated to a higher morbidity and mortality, as well as a higher length of hospital stay and the costs associated to treatment¹.

Intraperitoneal infection has been described as a risk factor for intestinal anastomosis dehiscence. It may harm healing by lowering the amount of tissue collagen and consequently wound mechanical strength². Several studies discussed the safety in performing such procedures when peritonitis is present though the results are controversial^{3,4}.

Adhesions are a consequence of normal healing process and develop in almost every patient who undergoes surgery with interventions in the peritoneal cavity⁵. The presence of peritonitis may be responsible for adhesion formation by itself, even when there are no injuries ascribed to surgery⁶.

In bacterial peritonitis, fibrin is formed in the peritoneal cavity as a result of the activation of the coagulation cascade and plays a key role in the host's response to bacterial infection by preventing early bacteremia and sepsis. The decrease in fibrinolytic activity following bacterial peritonitis also contributes to adhesion formation⁶.

This study aimed to evaluate the effects of abdominal sepsis on the adhesion formation process and the healing of colic anastomosis in rats which underwent abdominal sepsis by cecal ligation and puncture.

Methods

This study was approved by the Ethics Committee on the Use of Animals (CEUA) at University of Brasília's (UnB) Department of Biological Sciences. 40 healthy male rats (*Rattus norvegicus*, Wistar breed) were included in the study aged 90-120 days, and with a body weight ranging from 379 and 566g.

The animals were distributed using block randomization in two groups of 20 animals each, for euthanasia on the third or seventh post-operative day (Figure 1). A new block randomization was performed afterwards to allocate the subjects in subgroups according the presence or absence (normal conditions) of sepsis.

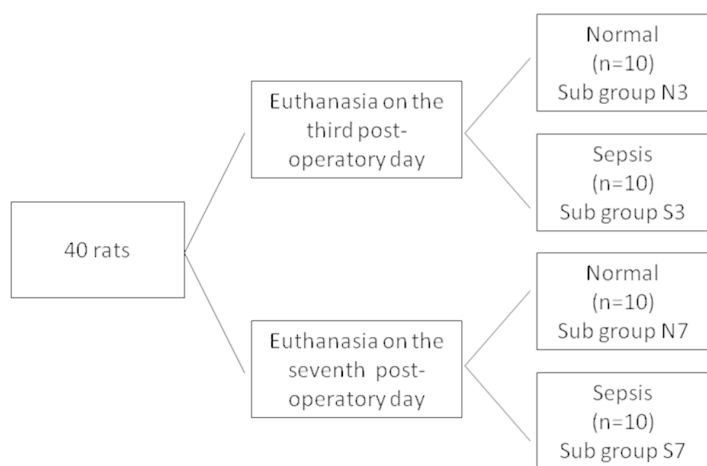


FIGURE 1 - Allocation of subjects in

General anesthesia was performed by administering 10mg/kg of xylazine hydrochloride and 75 mg/Kg of ketamine hydrochloride via intramuscular injection. All surgical procedures were performed by the same surgeon and consisted of a 4 cm median laparotomy, started 1 cm above the rats' genitals, distal colon exposure, resection of a 0.5 cm left colon segment, around 2.5 to 3.5 above the peritoneal reflexion and terminal colocolic anastomosis at a single transmural plane, with continuous 6.0 poly-propylene Shalon® thread stitches using a cylindrical needle.

In the animals from the sepsis group, peritonitis was induced after the anastomosis by cecal partial ligation as described by Rittirsch and colleagues⁷. A 50% ligation with 3.0 Shalon® silk threads was performed and punctures in the extreme distal cecum in 10 different points were made using a 40 x 13 mm venous puncture needle, by which a part of the fecal matter was exposed. Abdominal wall repair was performed by making continuous 3.0 Shalon® silk stitch planes.

The animals which did not survive the first 24 post-operative hours were excluded from the study. The reoperation was performed on specific dates for each subgroup. After the abdominal cavity was exposed, it was evaluated for signs of peritonitis, abscess or anastomosis dehiscence. The total amount of intra-abdominal adhesions was evaluated by using the Nair Score⁸:

- 0 – Absence of adhesions;
- 1 – a single strip between bowels or between bowel and the abdominal wall;
- 2 – two strips between bowels or between bowel and the abdominal wall;
- 3 - two or more strips between bowels or between bowel and the abdominal wall, or the whole intestine forming a mass which is not adhered to the abdominal wall;
- 4 –bowels directly adhered to the abdominal wall, regardless the number of strips or their length.

A 4 cm colon segment containing the anastomosis in their central portion was removed along with the structures adhered to it. After its removal, the ratio of anastomosis covered by adhesions was evaluated. The piece was opened by the anti-mesenteric edge and divided in three longitudinal segments for tensile strength, histopathological, hydroxyproline and tissue collagen later analysis. The latter was performed by using the Image J software. The slides were stained with picosirius and analyzed by polarization microscopy.

The statistical assessment was performed using the SPS software, version 17.0. The exact Fischer's test was used to evaluate the intraoperative finding, adherence occurrence and histopathological findings. The Mann Whitney's test was used to analyze the bursting strength, hydroxyproline and tissue collagen. A significance $p < 0.05$ was considered.

Results

Only one S7 subgroup subject died due to causes unrelated to anastomosis complications. There was one case of free anastomosis dehiscence with fecal matter present in the abdominal cavity upon reoperation in the S7 Subgroup. There was no statistical

difference regarding anastomosis dehiscence between the subgroups neither on the third nor on the seventh day. There was one case of anastomosis dehiscence blocked by the omentum in a S7 Subgroup subject in the seventh post-operative day. There was no statistical difference regarding anastomosis dehiscence between the subgroups neither on the third ($p=1,00$) nor on the seventh ($p=0,47$) day.

There was a higher frequency of peritonitis findings in the subjects which underwent cecal ligation and puncture (Subgroups S3 and S7), with a significant difference on both third ($p=0,00$) and seventh ($p=0,00$) post-operative days. There was no difference between the groups regarding the presence of paralytic ileus, intestinal obstruction or intra-cavitary abscess in both periods studied.

The subjects which underwent cecal ligation and puncture (S3 and S7 subgroups presented a higher amount of intra-abdominal adhesions on both third and seventh post-operative days ($p=0,00$). However, There were no significant differences between the subgroups regarding the percentage of anastomosis covered by adhesions on both third ($p=0,31$) and seventh ($p=0,65$) post-operative days.

On the third post-operative day, the S3 Subgroup subjects presented lower bursting strength values than the control subjects ($p=0,00$ – Figure 2). On the contrary, on the seventh post-operative day, the subjects which underwent cecal ligation and puncture (S7 Subgroup) presented a higher bursting strength when compared to those which were operated under normal circumstances ($p=0,00$ – Figure 3).

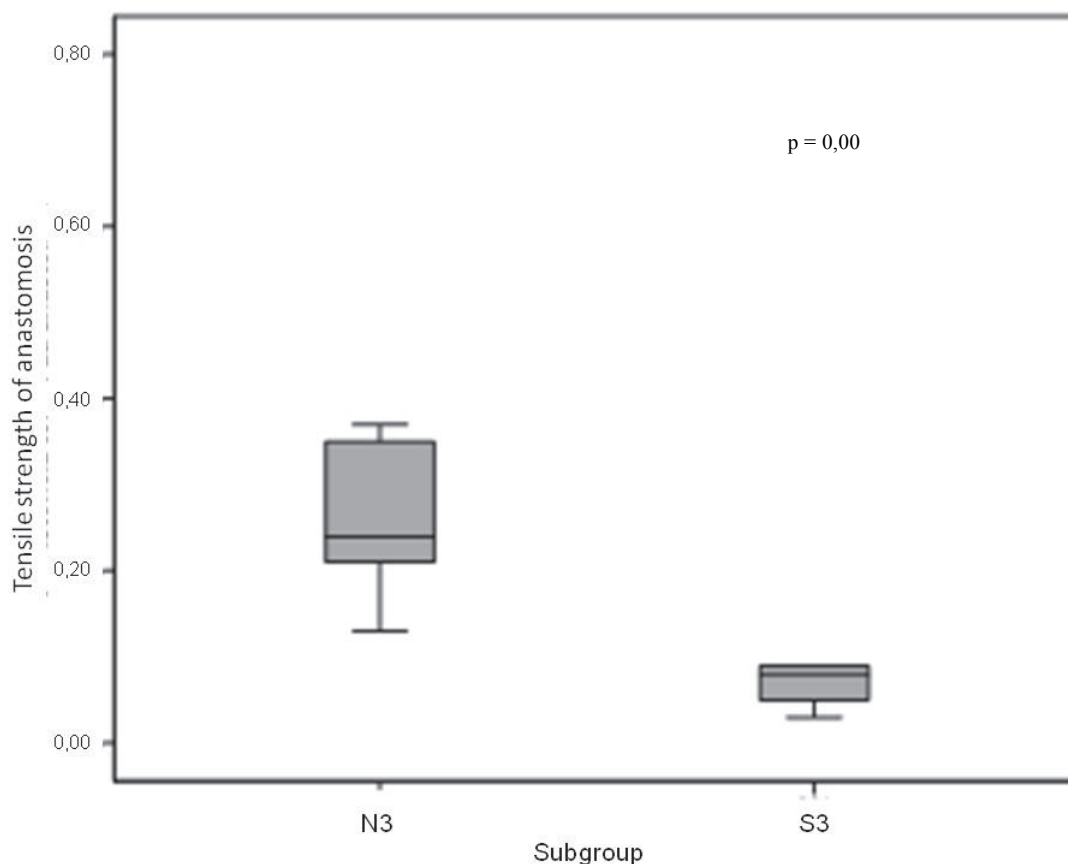


FIGURE 2 - Median and interval values for bursting strength in the anastomosis of subjects which underwent euthanasia on the third post-operative day

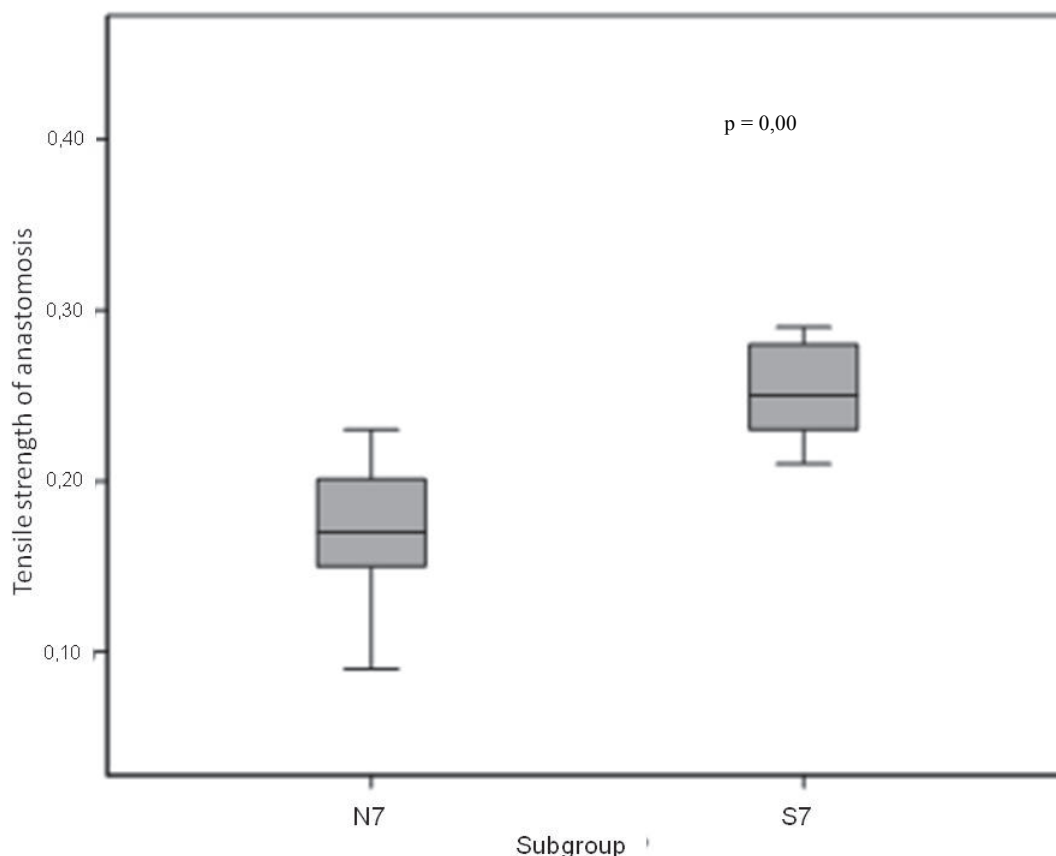


FIGURE 3 - Median and interval values for bursting strength in the anastomosis of subjects which underwent euthanasia on the seventh post-operative day

There was no significant statistical differences in the hydroxyproline concentration variations in both subjects which underwent euthanasia on the third ($p=0,27$) and seventh ($p=0,51$) post-operative days.

There was also no statistical difference between the subgroups regarding the amount of tissue collagen in the anastomosis on the seventh post-operative day ($p=0,45$).

On the third post-operative day, the following histopathological findings were predominant: moderate amount of fibroblasts ($p=1,00$), mononuclear cells ($p=1,00$), neo-vessels ($p=1,00$) and a high amount of polymorphonuclear cells ($p=1,00$). Necrosis ($p=0,47$) and colonies were also predominant with no statistical difference between the subgroups. All the evaluated subjects presented moderate edema, ulcerations, abscesses and a crust composed of fibrin and leukocytes and no foreign bodies.

Discussion

The cecal ligation and puncture method was first described in 1978 and is associated to polymicrobial sepsis and bacteremia. It became one of the abdominal sepsis model most used in physiopathological studies and in studies on the treatment of abdominal sepsis and its systemic consequences. It has the advantage of combining tissue injury with the capacity of

modulating the degree of bacterial contamination and mortality⁹.

This model may present different results. Mortality varies with the needle size and the number of punctures. It also depends on the amount of fecal matter in the cavity and it increases with the length of the ligated cecum and the amount injected. The model used in this study was determined in a pilot study. The goal was to provide a degree of contamination which could be evidenced by inflammatory and infectious alterations in the abdominal cavity contents upon reoperation, but also with a minimal mortality rate, without using any antibiotics.

There was no difference between the groups in terms of anastomosis dehiscence and other intraoperative findings, except for peritonitis. It was higher in the subgroup which underwent cecal ligation and puncture.

The subjects exposed to sepsis presented a higher amount of adhesions under the Nair Score in both third and seventh post-operative days, though there was no difference between the subgroups related to the percentage of anastomosis covered by adhesions. The latter would be the actually beneficial ones, once the blocking caused by adjacent organs would act as a protection for the anastomosis.

Intra-abdominal infection could increase the formation of intra-cavitary adhesions and the cecal ligation and puncture model seems to be one of the most important factors responsible

for that¹⁰. The gastrointestinal tract's bacterial flora seems to play an important role in the formation of adhesions around the anastomosis¹¹. Anastomosis in germ-free subjects showed fewer adhesions than those which were mono contaminated with *Escherichia coli* or *Lactobacillus* and healthy controls. The authors suggested that bacterial translocation or leaks in minor flaws could stimulate the formation of adhesions or this very effect could be triggered by the influence on the immune system or modifying the fibrinolytic system's response to trauma¹².

Bursting strength was smaller in the subgroup which underwent cecal ligation and puncture on the third post-operative day but these subjects also presented a bursting strength higher than the control subjects on the seventh post-operative day. Most studies proved the deleterious effects of peritoneal infection in the first post-operative days, but on the seventh day the results are conflicting.

Rocha *et al.*¹³ demonstrated that peritonitis made the total bursting energy values decrease significantly on the fourth day after performing anastomosis in rats' distal colon. De Hing *et al.*¹⁴ evidenced that peritonitis decreased the anastomosis' mechanical resistance on the third post-operative day, returning to normality on the fifth day. Teke *et al.*¹⁵ demonstrated that secondary peritonitis triggered by cecal ligation and puncture harmed the healing process of left colon anastomosis in rats by decreasing the tensile strength on the seventh post-operative day. Wang *et al.*¹⁶ found a decrease in the bursting pressure values on the fifth day in subjects which underwent anastomosis 24 hour prior to cecal ligation and puncture.

On the contrary, Biondo-Simões *et al.*³ evaluated the healing of left colon anastomosis in rats performed in control subjects and after 24-hour-peritonitis triggered by colon injury. In 1997 the same study groups didn't find any differences regarding the amount of adhesions, tensile strength and microscopic evaluation in anastomosis performed 24 hours after cecal ligation and puncture neither on the third nor on the seventh post-operative day when compared to control subjects¹⁷.

Even though peritoneal infection is associated to an increase in collagenolysis and an impairment of the collagen genesis, there was no difference between the groups regarding the amount of collagen present in the anastomosis line. Some authors claim that the concentration of collagen may not be as important as its organization. An RNA analysis was performed on the first and fourth post-operative anastomosis days 24 hours after sepsis induced by cecal ligation and puncture. Collagen genesis was diminished in both subjects on the first and fourth post-operative days after exposure to sepsis. Alterations on the expression of collagen types I and III harmed collagen neogenesis decreased anastomosis strength².

The evaluation of the intact intestine after cecal ligation and puncture had a decrease of 30% in collagen I after 24 hours. Anastomosis performed in the absence of cecal ligation and puncture showed a decrease in type I collagen on the first post-operative day, and level raise above the base line on the fourth post-operative day. The Anastomosis performed after cecal ligation and puncture showed an early rise in type I collagen without further raises until the fourth post-operative day. The authors concluded that intra-abdominal infection harms collagen repair mechanisms and protein synthesis, apart from altering gene regulation of

collagen types I and III, and that these alterations contribute to a decrease in colon mechanical strength.

Biondo-Simões *et al.*¹⁸ conducted a study in which 40 rats subdivided in control and peritonitis groups underwent transverse colon anastomosis followed by euthanasia on the fourth and seventh post-operative days. Collagen concentration was lower in the subjects exposed to peritonitis on both third and seventh post-operative days. On the seventh post-operative day, the peritonitis group presented a higher amount of type III collagen on both third and seventh post-operative days. On the seventh day, the Peritonitis Group presented a higher concentration of type III collagen. Tensile strength was similar between groups in both periods studied and was increased over time. These results demonstrated that there is a decrease in the concentration and maturation of collagen in the colocolic anastomosis performed in the presence of peritonitis, but these alterations may not interfere in the anastomosis' capacity of withstanding pressure.

There were no differences between the subgroups regarding the histopathological findings, which is in accordance to previous studies^{3,17}.

Hydroxyproline isn't always in the direct relation with other healing parameters¹⁹. Previous studies have already demonstrated a reduction in tensile strength without any differences in the concentrations of hydroxyproline in subjects exposed to aseptic inflammation, distant site infection, local and systemic infection²⁰.

There were no differences between the groups regarding variations in the concentration of hydroxyproline. These results confirm Biondo-Simões *et al.*³ study. However, other studies demonstrated a decrease in the concentration of hydroxyproline in subjects which underwent cecal ligation and puncture. When compared to control subjects^{15,16}.

Conclusions

Peritoneal infection was associated to a raise in the amount of intra-cavitary adhesions. There was a decrease in the mechanical strength of colic anastomosis on the third post-operative day, with a later rise on the seventh day, with no effects on the histopathological findings, hydroxyproline content and tissue collagen.

References

1. Buchs NC, Gervaz P, Secic M, Mugnier-Konrad B, Morel P. Incidence, consequences and risk factors for anastomotic dehiscence after colorectal surgery: a prospective monocentric study. *Int J Colorectal Dis.* 2008;23:265-70.
2. Ahrendt GM, Tantry US, Barbul A. Intra-abdominal sepsis impairs colonic reparative collagen synthesis. *Am J Surg.* 1996;171:102-7.
3. Biondo-Simões MLP, Adur RC, Quiintana LFCL, Gonçalves CA, Demarchi HL, Mello ALC, Vaz LI, Repka JC. Evolução de anastomosis do cólon esquerdo após a indução de peritonite focal, em ratos. *Arq Gastroenterol.* 1996;33:79-85.
4. Naresse LE, Leite CVS, Rodrigues MAM, Angeleli AYO, Minossi JG, Kobayasi S. Efeito da peritonite fecal na cicatrização do cólon distal no rato. Avaliação anatomopatológica, estudo da força de ruptura e da hidroxiprolina tecidual. *Acta Cir Bras.* 1993;8:48-53.

5. Liakakos T, Thomakos N, Fine PM, Dervenis C, Young RL. Peritoneal adhesions: ethiology, pathophysiology and clinical significance. Recent advances in prevention and management. *Dig Surg.* 2001;18:260-73.
6. Cahill RA, Wang JH, Redmond HP. Enteric bacteria and their antigens may stimulate postoperative peritoneal adhesion formation. *Surgery.* 2007;141:403-10.
7. Rittirsch D, Huber-Lang MS, Flierl MA, Ward PA. Immunodesign of experimental sepsis by cecal ligation and puncture. *Nature Protocols.* 2009;4:31-6.
8. Nair SK, Bhat IK, Aurora AL. Role of proteolytic enzyme in the prevention of postoperative intraperitoneal adhesion. *Arch Surg.* 1974;108:849-53.
9. Ozen IO, Ekingen G, Taslipinar MY, Bukan N, Demirogullari B, Karabulut R, Sönmez K, Basaklar AC, Kale N. Effect of melatonin on healing of colonic anastomosis in a rat model of peritonitis. *Eur Surg Res.* 2007;39:122-7.
10. Aydin C, Aytakin FO, Tekin K, Kabay B, Yenisey C, Kocbil G, Ozden A. Effect of temporary abdominal closure on colonic anastomosis and postoperative adhesions in experimental secondary peritonitis. *World J Surg.* 2006;30:612-9.
11. Bedirli A, Gokahmetoglu S, Sakrak O, Ersoz N, Ayangil D, Esin H. Prevention of intraperitoneal adhesion formation using beta-glucan after ileocolic anastomosis in a rat bacterial peritonitis model. *Am J Surg.* 2003;185:339-43.
12. Bothin C, Okada M, Midtvedt T, Perbeck L. The intestinal flora influences adhesion formation around surgical anastomosis. *Br J Surg.* 2001;88:143-5.
13. Rocha AA, Leal RF, Ayrizono MDL, Chung WF, Coy CS, Lee HD, Fagundes JJ. Hyperbaric oxygen therapy and mechanical resistance of the colonics anastomosis in rats with peritonitis. *Acta Cir Bras.* 2010;25:368-74.
14. De Hingh IH, De Man BM, Lomme RM, Van Goor H, Hendriks T. Colonic anastomotic strength and matrix metalloproteinase activity in an experimental model of bacterial peritonitis. *Br J Surg.* 2003;90:981-8.
15. Teke Z, Sacar S, Yenisey C, Atalay AO, Kavak T, Erdem E. Role of activated protein C on wound healing process in left colonic anastomosis in the presence of intra-abdominal sepsis induced by cecal ligation and puncture: an experimental study in the rat. *World J Surg.* 2008;32:2434-43.
16. Wang P, Gong G, Li Y, Li J. Hydroxyethyl starch 130/0.4 augments healing of colonic anastomosis in a rat model of peritonitis. *Am J Surg.* 2010;199:232-9.
17. Biondo-Simões MLP, Canalli LS, Ferreira C, Meschino R, Kaimoto T, Collaço LM. Evaluation of the cicatrization of left colon anastomosis in the presence of peritonitis. An experimental study on rats. *Acta Cir Bras.* 1997;12:94-9.
18. Biondo-Simões M LP, Greca FH, Junior AB, Komatsu MCG, Bittencourt FO, Greca LM. Influence of peritonitis on the synthesis of collagen of the distal colon: experimental study in rats. *Acta Cir Bras.* 2000;15:69-73.
19. Agalar F, Hamaloglu E, Daphan C, Tarim A, Onur R, Renda N. Effects of CO2 insufflation and laparotomy on wound healing in mice. *Aust N Z J Surg.* 2000;70:739-42.
20. De Hann BB, Ellis H, Wilkis, M. The role of infection on wound healing. *Surg Gynecol Obst.* 1974;138:693-700.

Correspondence:

Silvana Marques e Silva
SQS 405, Bloco B/205
70239-020 Brasília – DF Brasil
silvismarques@yahoo.com.br

Conflict of interest: none

Financial source: none

¹Research performed at Experimental Surgery Laboratory, Clinical Surgery Practice, Brasilia's University Medical School (UNB) in collaboration with the Pathology Laboratory at Brasilia's University Medical School – UNB and the Biochemistry and Liver Transplant Laboratory at the Experimental Surgery Practice at Sao Paulo's University Ribeirao Preto Medical School – USP, Brazil.

Presented at the XII National Congress on Experimental Surgery of the Brazilian Society for Development of Research in Surgery-SOBRADPEC, 2011 October 26-29 Ribeirao Preto-SP, Brazil.