

Beneficial effects of β -glucan against cisplatin side effects on the nervous system in rats¹

Kürşat Kaya^I, Osman Ciftci^{II}, Ashı Cetin^{III}, Mehmet Tecellioglu^{IV}, Neşe Başak^V

DOI: <http://dx.doi.org/10.1590/S0102-865020160030000008>

^IAssistant Professor, Department of Biochemistry, Faculty of Pharmacy, Adıyaman University, Adıyaman, Turkey. Conception and design of the study, analysis and interpretation of data, manuscript preparation and writing.

^{II}Associate Professor, Department of Pharmacology, Faculty of Medicine, Inonu University, Malatya, Turkey. Conception and design of the study, analysis and interpretation of data, statistical analysis.

^{III}Assistant Professor, Department of Histology and Embryology, Faculty of Medicine, İnönü University, Malatya, Turkey. Histopathological examinations.

^{IV}Assistant Professor, Department of Neurology, Faculty of Medicine, İnönü University, Malatya, Turkey. Technical procedures, acquisition of data.

^VFellow PhD degree, Department of Pharmaceutical Toxicology, Faculty of Pharmacy, İnönü University, Malatya, Turkey. Technical procedures, acquisition of data.

ABSTRACT

PURPOSE: To investigate the protective effect of Bg on cisplatin (CP)-induced neurotoxicity in rats.

METHODS: Twenty eight rats were randomly distributed into four groups. The first group was kept as a control. In the second group, CP was given at the single dose of 7 mg/kg intraperitoneally. In the third group, β g was orally administered at the dose of 50 mg/kg/day for 14 days. In the fourth group, CP and β g were given together at the same doses.

RESULTS: CP treatment caused significant oxidative damage via induction of lipid peroxidation and reductions antioxidant defense system potency in the brain tissue. In addition, histopathological damage increased with CP treatment. On the other hand, β g treatment largely prevented oxidative and histopathological negative effects of CP.

CONCLUSIONS: Cisplatin has severe neurotoxic effects in rats and β g supplementation has significant beneficial effects against CP toxicity depending on its antioxidant properties. Thus, it appears that β g might be useful against CP toxicity in patients with cancer in terms of nervous system.

Key words: Cisplatin. beta-Glucans. Nervous System. Oxidative Stress. Rats.

Introduction

Cisplatin, cisplatinum or cis-diamminedichloroplatinum (II) (CP), is an effective antineoplastic agent. CP is widely used alone or combined with other cancer drugs for the treatment of many types of cancers including lung, ovarian, neck and brain¹cisplatinum, or cis-diamminedichloroplatinum (II). However usage of CP is limited because it has toxic effects on the many organs and systems such as nephrotoxicity, hepatotoxicity, ototoxicity and neurotoxicity^{1,2}cisplatinum, or cis-diamminedichloroplatinum (II). Neurotoxicity is one of the most prevalent side effect of CP and this case restricts dose of CP³. The mechanism of CP induced neurotoxicity is still unknown exactly but past studies indicated that CP direct connects with neuronal DNA and increases formation of reactive oxygen species (ROS)^{4,5}. In accordance, our previous studies showed that CP leads to oxidative damage on the nervous system^{6,7}the beneficial effect of hesperidin (HP). Therefore, many antioxidant compounds such as selenium⁸, D-Methionine⁹ were tried with a view to can prevent CP induced oxidative damage on the nervous system. However, to our knowledge, Beta glucan (β g) was not tried opposite to CP induced neurotoxicity.

β gs are natural polysaccharides that have pharmacological activities such as immunomodulation and antioxidant activity, obtained from many mushrooms, fungus and cereals species^{10,11}. Many useful effects on the health of β gs have manifested in previous studies. Immune modulatory¹⁰, anti-allergic¹², anti-hepatic steatosis¹³, on the skin health¹⁴, blood glucose lowering¹⁵ and anti-cardiovascular diseases¹⁶ effects are some of those useful effects only. In addition to various studies showed that β g has affirmative effect opposite to CP toxicity including myelotoxicity¹⁷, genotoxicity¹⁸ and nephrotoxicity¹⁹. To our knowledge, there is no reported study as to whether the treatment of β g can prevent CP neurotoxicity.

In that context, we hypothesised that β g added diet may reduce or prevent CP induced neurotoxicity owing to antioxidant, anti-inflammatory and immunomodulatory properties.

Methods

The protocol of this study was approved by the Institutional Animal Ethical Committee.

In total, 28 Sprague Dawley male rats obtained from Experimental Animals Unit of İnönü University were used this study. Rats of 250–300 g body weight were used (aged between 2–3 months). Animals were kept in sterilized polypropylene rat cages, under controlled environmental conditions at room

temperature (21°C) and cycle of 12 h light and 12 h dark. Rats fed standard pellet food and given an *ad libitum* supply of water.

Rats were separated into four groups randomly (n = 7 each). Group 1 (control) served as negative control and isotonic saline was given once as intra peritoneal (i.p.) injection and 14 days as orally. Group 2 (CP group), CP (7 mg/kg) was given as a single injection (i.p.) on day 1, and then isotonic saline was given for 14 days as orally. Group 3 (β g group) were treated with a single injection (i.p.) isotonic saline on day 1, and then β g (50 mg/kg) for 14 days orally. Group 4 (CP+ β g group) were treated with CP and β g together; identical dose, volume and mode of administration with other groups. The animals were euthanised under ether anesthesia, and tissue samples were removed immediately and dissected on ice-cold glass on day 14 after CP treatment. Tissue samples were stored at -86°C until analysis.

Chemicals

CP (10 mg per 10 ml, Code 1876A) was obtained from Faulding Pharmaceuticals Plc (Warwickshire, UK). β g was purchased from drugstore as IMUNEKS (Mustafa Nevzat Drug Industry, İst, Turkey), in which it is capsule form. Each capsule is containing 50 mg β g obtained from bread yeast. All other chemicals were purchased from Sigma Chemical Co. (St. Louis, MO) and were of analytical grade or of the highest grade available.

Biochemical assay

Ten percentage (w/v) homogenate of brain tissue was prepared with a blander homogenizer (IKA T 10 basic Ultra-Turrax) in 150 mM phosphate buffer (pH 7.4), conforming to cold chain. Lipid peroxidation was determined by measuring the MDA level as Thiobarbituric acid reactive substances (TBARS) using the method described by Yagi²⁰. TBARS level is an index of lipid peroxidation. The product was evaluated spectrophotometrically at 532 nm, and results are expressed as nmol/g tissue. To the end that evaluate of antioxidant defense system, levels of glutathione (GSH), superoxide dismutase (SOD), catalase (CAT), and glutathione peroxidase (GPx) was determined. SOD, CAT, GPx are enzymatic and GSH is non-enzymatic members of the antioxidant defense systems, which protect against oxidative damage, may cause ROS. The GSH level was measured at 412 nm and expressed as nmol/ml using the method of Sedlak and Lindsay²¹. SOD activity was measured using the method described by Sun *et al.*²². According to that method, the activity is performed by taking into account the inhibited reduction of NBT (nitro blue tetrazolium) by

the enzyme extract. One unit of SOD activity was defined as the amount of protein causing 50% inhibition of the NBT reduction rate. The product was evaluated spectrophotometrically at 560 nm. Results are expressed as IU/mg protein. CAT activity in the brain tissue was determined by using the method described by Aebi *et al.*²³. The principle of this method is based on the CAT present in the sample to convert H₂O₂ to H₂O and O₂. The enzymatic decomposition of H₂O₂ was followed directly by the decrease in absorbance at 240 nm. Enzyme activities are given in k mg/protein. GPx were determined using spectrophotometric methods, as described by Paglia and Valentine²⁴. GPx activity was expressed as IU mg/protein. Protein quantity of brain tissue was determined of method of Lowry²⁵.

Histological evaluation

For light microscopic evaluation, brain samples were fixed in 10% formalin and were embedded in paraffin. Paraffin-embedded specimens were cut into 5µm thick sections, mounted on slides and stained with Hematoxylen- Eosin (H-E). Tissue samples were examined using a Leica DFC280 light microscope and a Leica Q Win Image Analysis system (Leica Micros Imaging Solutions Ltd., Cambridge, UK).

For immunohistochemically analysis, thick sections were mounted on polylysine- coated slides. After rehydrating, samples were transferred to citrate buffer (pH 7.6) and heated in a microwave oven for 20 minutes. After cooling for 20 minutes at room temperature, the sections were washed with phosphate-buffered saline (PBS). Then sections were kept in 0.3% H₂O₂ for 7 minutes and afterward washed with PBS. Sections were incubated

with primary rabbit-polyclonal Caspase-3 antibody (Abcam, Ab4051) for two hours. Then they were rinsed in PBS and incubated with biotinylated goat anti-polyvalent for 10 minutes and streptavidin peroxidase for 10 minutes at room temperature. Staining was completed with chromogen + substrate for 15 minutes, and slides were counterstained with Mayer's hematoxylin for 1 minute, rinsed in tap water, and dehydrated. The Caspase-3 kit was used according to the manufacturer's instructions.

Statistical analysis

SPSS 18.0 (SPSS Inc.; Chicago, IL, USA) was used for statistical analyses. The statistical analyses were conducted using one-way analysis of variance (ANOVA) and post hoc Tukey's Honestly Significant Differences test. The values were presented as mean ± SD and differences were considered to be significant at p<0.01.

Results

Biochemical results

TBARS, GSH, CAT, GPx, and SOD levels in rats' brain tissue are provided (Table 1). The results showed that CP apply caused to significantly increase TBARS levels and significantly decrease in GSH, CAT, SOD and GPx compared to control and other groups. However, βg treatment together with CP significantly ameliorated in elevated TBARS levels and in deteriorated GSH, CAT, SOD and GPx compared to CP alone group.

TABLE 1 - The levels of SOD, CAT, GPx, GSH and TBARS in brain tissue of rats (Mean±SD).

| | TBARS nmol/g tissue | Reduced GSH nmol/ml | CAT k/mg protein | SOD U/mg protein | GPx U/mg protein |
|-----------------------|--------------------------------|--------------------------------|-----------------------------|-----------------------------|-----------------------------|
| Control | 9.26±0.76 ^a | 224.2±7.23 ^a | 0.045±0.0013 ^a | 29.38±2.03 ^a | 256.4±15.9 ^a |
| CP | 17.8±1.09 ^b | 119.4±6.34 ^b | 0.024±0.0015 ^b | 19.21±1.83 ^b | 158.9±13.7 ^b |
| Beta glukon | 8.87±0.95 ^a | 217.7±8.21 ^{ac} | 0.039±0.0010 ^{ac} | 30.23±2.26 ^a | 243.5±16.1 ^a |
| CP+Beta glukon | 12.5±1.10 ^c | 195.9±7.59 ^c | 0.034±0.0012 ^c | 27.85±1.93 ^a | 201.7±15.9 ^c |

Means bearing different superscripts within same column were significantly different (p<0.01).

Histopathological results

In Control (Figure 1A) and βg groups (Figure 1B), brain tissue showed normal histological appearance. Neurons of cerebral cortex showed normal histological appearance in control and βg groups. Some histological alterations were detected in CP group brain tissue. These histological alterations were vascular

congestion (Figure 2 A-B) and cell infiltration in pia mater (Figure 2A), cell infiltration in cerebral cortex (Figure 2C), shrinkage cytoplasm and extensively dark picnotic nuclei in neurons of the cerebral cortex (Figure 2D) in CP group. In contrast, βg treatment significantly attenuated the harmful effects. These findings were decreased in CP + βg group (Figure 3 A-B).

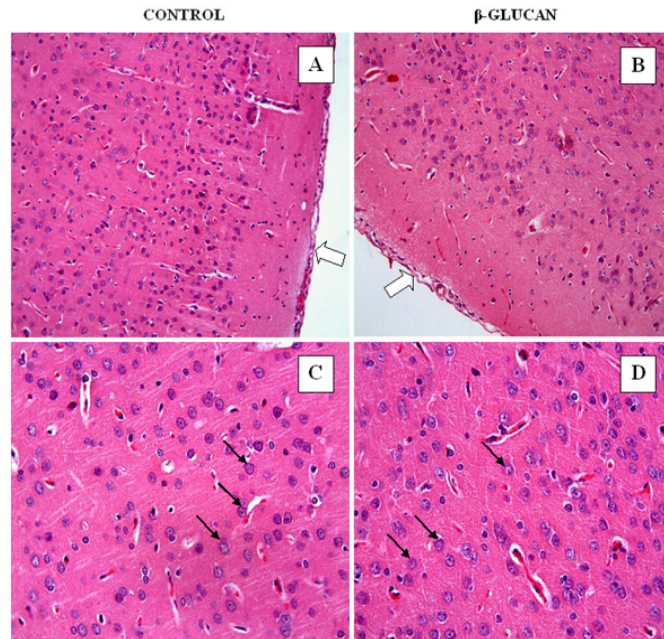


FIGURE 1 - Control (A,C) and β -glucan (B,D) groups. Normal histological appearance were observed in control and β -glucan groups. Neurons of cerebral cortex showed normal histological appearance in control and β -glucan groups. A,B (H-E; x20); C,D (H-E; x40).

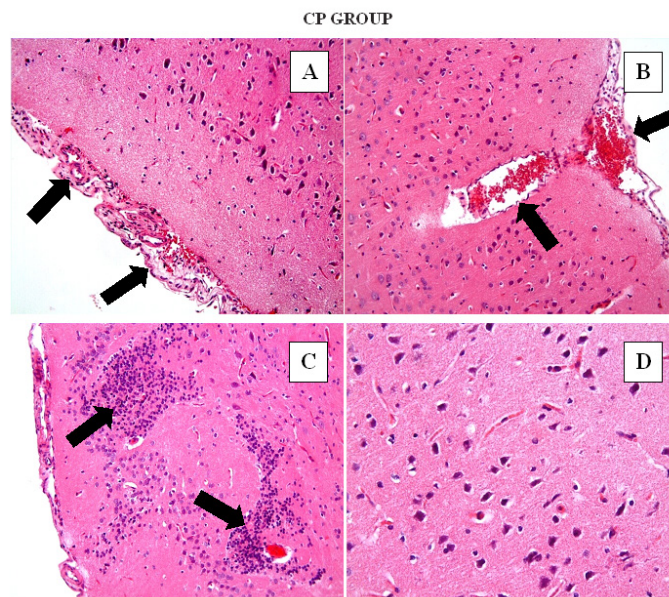


FIGURE 2 - CP Group. Vascular congestion (A, B) and cell infiltration in pia mater (2A), cell infiltration in cerebral cortex (2C), shrinkage cytoplasm and extensively dark picnotic nuclei in neurons of the cerebral cortex (2D) in CP group. A,B,C (H-E; x20); D (H-E; x40).

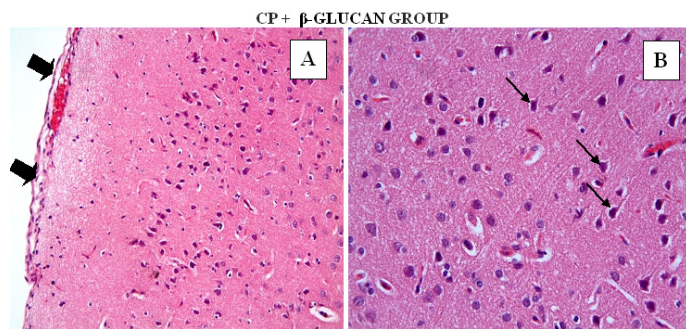


FIGURE 3 - CP + β -glucan group. A few vascular congestion and cell infiltration in pia mater (A) shrinkage cytoplasm and extensively dark picnotic nuclei in neurons of the cerebral cortex decreased (B) in CP + β -glucan group. A,B,C (H-E; x20); D (H-E; x40).

In control (Figure 4A) and β g (Figure 4B) groups, cerebellar cortex showed normal histological appearance. Purkinje cells showed no histological changes. We detected deeply stained,

shrunk and various shapes Purkinje cells with pyknotic nuclei in CP group (Figure 4C). In CP + β g group degenerative Purkinje cells were decreased (Figure 4D).

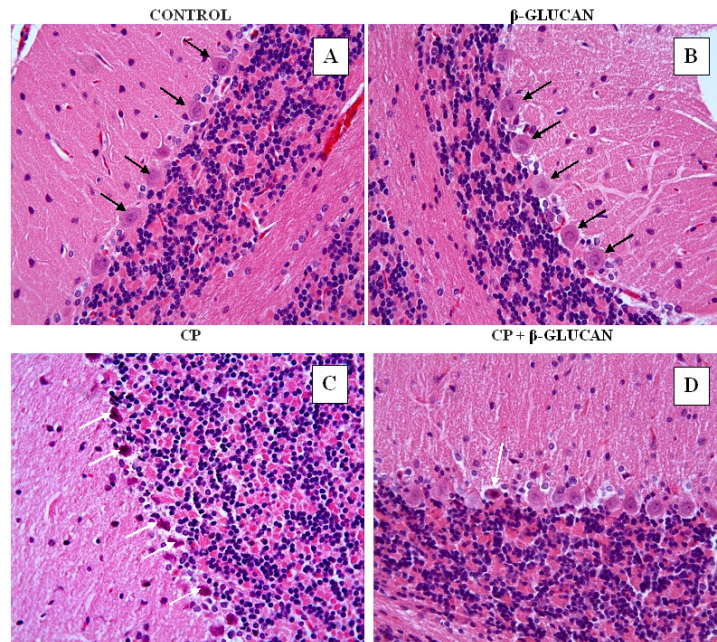


FIGURE 4 - In control (A) and β -glucan (B) groups, cerebellar cortex had showed normal histological appearance. In CP group (C), deeply stained Purkinje cells with pyknotic nuclei were detected. In CP + β -glucan group (D) purkinje cell degeneration decreased compared with CP group. (H-E; x40).

Immunohistochemically Caspase-3-stained cells were not observed in the cerebral cortex in control (Figure 5A) and β -glucan (Figure 5B) groups. The percentage of Caspase-3

positive cells was high in CP group (Figure 5C). The density of immunohistochemically Caspase-3-stained cells was minimal in CP + β g group (Figure 5D).

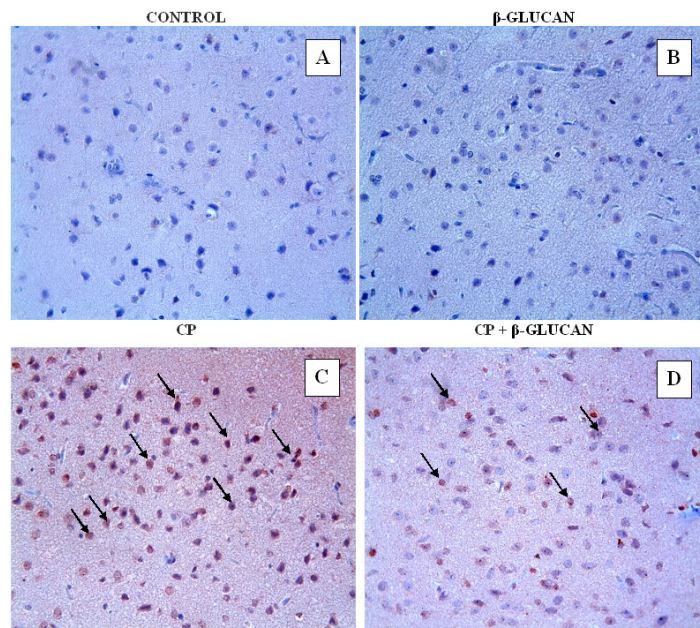


FIGURE 5 - Immunohistochemical caspase-3 staining in all experimental groups of rats. In control (A) and β -glucan (B) groups, there were no positive stained cells. The percentage of positive stained cells decreased in CP+ β -glucan group (D) compared with CP group (C). (Caspase-3; x40).

Discussion

One of most important mechanisms of CP toxicity is oxidative stress on nervous system and other systems. CP induced reactive oxygen species triggers off cell deaths¹cisplatinum, or cis-diamminedichloroplatinum (II). The nervous system tissue is between most sensitive tissues against oxidative stress because of contains plentiful polyunsaturated fatty acids the brain tissue is highly susceptible lipid peroxidation⁶the beneficial effect of hesperidin (HP). This condition restricts use of CP on the cancer patients. Therefore, prevent or diminish side effects of CP is very important in terms of medical oncology. In this study, we showed that Bg supplementation can diminish the side effect of CP on the nervous system.

Many experimental studies have demonstrated that CP was induced lipid peroxidation and was decreased members of antioxidant defense system on the nervous system²⁶⁻²⁸. Akman *et al.*²⁷ indicated that CP injection caused approximately doubled MDA level and decreased 50% GSH level. Also Turan *et al.*²⁸ reported that CP treatment led to increase 200% TBARS and myeloperokxidase in addition to decrease 60% SOD and GSH approximately. Alike, our previous studies showed that CP caused significantly increased TBARS level and decreased GSH, SOD, CAT and GPx levels on the nervous system^{6,7}. In the present study detected that TBARS level of CP group increased significantly compared with other groups, suitable for our expectation. At the same time CP caused a significant decrease in GSH, SOD, CAT and GPx levels. In this context, our results confirmed results of previous studies.

β gs are naturel polysaccharides that have anti-oxidant properties with other a lot of beneficial properties for healthy^{10,29,30}. β gs are found worth for study by many researchers due to have got beneficial properties such as immune modulatory¹⁰, blood glucose lowering¹⁵ and anti-cardiovascular diseases¹⁶. In addition, many researchers have worked beneficial effects of β g opposed to cancer and/or side effects of cancer chemotherapeutics such as CP. Schwartz and Hadar³¹ said that glucans may prevent or cure colitis associated cancer depend on anti-inflammatory properties. Both Masuda *et al.*¹⁷ and Ku *et al.*¹⁹ showed that β gs treatment reduce CP-induced nephrotoxicity. In addition Masuda *et al.*¹⁷ showed that β gs treatment enhancement antitumor and antimetastatic activity of CP. Also Tohamy *et al.*¹⁸ denoted that β g treatment significantly reduced the frequency of structural chromosomal aberrations induced by anti-neoplastic drugs including CP, in both bone marrow and spermatogonial cells. However, Bayindir *et al.*²⁹

indicated that β g treatment with CP caused significant deterioration hearing, and they explain that β g increases permeability and tissue conductance into the inner ear of CP. In the present study, β g treatment with CP significantly decreased lipid peroxidation and increased members of enzymatic and non-enzymatic antioxidant defense system compare with CP group. While TBARS level decreased 50%, levels of GSH, CAT, SOD and GPx showed that 30-50% increment.

In the present study, our results showed that CP administration caused histopathological alterations of brain tissue such as vascular congestion and cell infiltration in pia mater, cell infiltration in cerebral cortex, shrinkage cytoplasm and extensively dark picnotic nuclei in neurons of the cerebral cortex. In addition to, immunohistochemically Caspase-3 evaluation supported histopathological results. The percentage of Caspase-3-stained positive cells was high in CP group compare with control group. Our results were largely compatible with results of many previous studies. Karavelioğlu *et al.*⁸ indicated that CP gave rise to dilated capillaries, vacuolated neurons and increased glial cell in around of neurons besides increased bax positive cells and decreased bcl-2 positivity. Also, Carozzi *et al.*³² demonstrated that CP apply caused appear smaller dorsal root ganglion neurons and multinucleated neurons with eccentric nucleoli. Alike, Li *et al.*³³including neurotoxicity. Oxidative damage contributes to cisplatin-induced neurotoxicity, but the mechanism remains unclearly. Cyanidin, a natural flavonoid compound, exhibits powerful antioxidant activity. Hence, we investigated the protective effects of cyanidin on PC12 cells against cisplatin-induced neurotoxicity and explored the underlying mechanisms. The results showed that cisplatin-induced cytotoxicity was completely reversed by cyanidin through inhibition of PC12 cell apoptosis, as proved by the attenuation of Sub-G1 peak, PARP cleavage, and caspases-3 activation. Mechanistically, cyanidin significantly inhibited reactive oxygen species (ROS showed that CP lead to increase apoptosis and caspase-3 activation in neurons derived from PC12 cells. On the other hand, Nakamura *et al.*³⁴ claimed that CP produced no effect on intraneuronal transport. However, in our study, β g treatment with CP largely ameliorated histopathological and immunohistochemically deterioration. To our knowledge, there is no reported study as to whether the treatment of β g can prevent CP neurotoxicity. But, there were some studies related that β g can prevent CP toxicity on the some other tissue and system^{17,19,29}. However, there were a few studies that were made histological evaluation. Ku *et al.*¹⁹ showed that β g corrected histopathological deterioration resulted from CP-induced acute renal failure.

Conclusions

Cisplatin administration caused increase oxidative stress and histopathological deterioration on the central nervous system of rats. Also, the use of β g with CP largely prevented biochemical and histopathological changes. It is more than probable that the beneficial effect of β g against CP-induced neurotoxicity can be due to its antioxidant, anti-inflammatory and immunomodulatory properties. Thus, it appears that co-administration of β g with CP may be a useful approach to attenuate the negative effects of CP on the nervous system.

References

- Dasari S, Bernard Tehounwou P. Cisplatin in cancer therapy: molecular mechanisms of action. *Eur J Pharmacol.* 2014;740:364-78. doi: 10.1016/j.ejphar.2014.07.025.
- Albers JW, Chaudhry V, Cavaletti G, Donehower RC. Interventions for preventing neuropathy caused by cisplatin and related compounds. *Cochrane Database Syst Rev.* 2014 Mar 31;3:CD005228. doi:10.1002/14651858.CD005228.pub3.
- Carozzi VA, Chiorazzi A, Canta A, Meregalli C, Oggioni N, Cavaletti G, Marmiroli P. Chemotherapy-induced peripheral neurotoxicity in immune-deficient mice: new useful ready-to-use animal models. *Exp Neurol.* 2015;264:92-102. doi: 10.1016/j.expneurol.2014.11.002.
- Kelley MR, Jiang Y, Guo C, Reed A, Meng H, Vasko MR. Role of the DNA base excision repair protein, APE1 in cisplatin, oxaliplatin, or carboplatin induced sensory neuropathy. *PLoS One.* 2014;9(9):e106485. doi: 10.1371/journal.pone.0106485.
- Carozzi VA, Canta A, Chiorazzi A. Chemotherapy-induced peripheral neuropathy: what do we know about mechanisms? *Neurosci Lett.* 2014;596:90-107. doi: 10.1016/j.neulet.2014.10.014.
- Kamisli S, Ciftci O, Kaya K, Cetin A, Kamisli O, Ozcan C. Hesperidin protects brain and sciatic nerve tissues against cisplatin-induced oxidative, histological and electromyographical side effects in rats. *Toxicol Ind Health.* 2015 Sep;31(9):841-51. doi: 10.1177/0748233713483192.
- Kamisli S, Ciftci O, Cetin A, Kaya K, Kamisli O, Celik H. Fish oil protects the peripheral and central nervous systems against cisplatin-induced neurotoxicity. *Nutr Neurosci.* 2014;17(3):116-26. doi: 10.1179/1476830513Y.0000000074.
- Karavelioglu E, Boyaci MG, Simsek N, Sonmez MA, Koc R, Karademir M, Guven M, Eser O. Selenium protects cerebral cells by cisplatin induced neurotoxicity. *Acta Cir Bras.* 2015;30(6):394-400. doi: 10.1590/S0102-865020150060000004.
- Hinduja S, Kraus KS, Manohar S, Salvi RJ. d-Methionine protects against cisplatin-induced neurotoxicity in the hippocampus of the adult rat. *Neurotox Res.* 2015;27(3):199-204. doi: 10.1007/s12640-014-9503-y.
- Stier H, Ebbeskotte V, Gruenewald J. Immune-modulatory effects of dietary Yeast Beta-1,3/1,6-D-glucan. *Nutr J.* 2014;13(1):38. doi: 10.1186/1475-2891-13-38.
- Agostini S, Chiavacci E, Matteucci M, Torelli M, Pitto L, Lionetti V. Barley beta-glucan promotes MnSOD expression and enhances angiogenesis under oxidative microenvironment. *J Cell Mol Med.* 2014;19(1):227-38. doi: 10.1111/jcmm.12442.
- Jesenak M, Banovcin P, Rennerova Z, Majtan J. β -Glucans in the treatment and prevention of allergic diseases. *Allergol Immunopathol (Madr).* 2014;42(2):149-56. doi: 10.1016/j.aller.2012.08.008.
- You S, Hu X, Zhao Q, Chen X, Xu C. Oat β -glucan inhibits lipopolysaccharide-induced nonalcoholic steatohepatitis in mice. *Food Funct.* 2013;4(9):1360-8. doi: 10.1039/c3fo60081e.
- Du B, Bian Z, Xu B. Skin health promotion effects of natural beta-glucan derived from cereals and microorganisms: a review. *Phyther Res.* 2014;28(2):159-66. doi: 10.1002/ptr.4963.
- Tosh SM. Review of human studies investigating the post-prandial blood-glucose lowering ability of oat and barley food products. *Eur J Clin Nutr.* 2013;67(4):310-7. doi: 10.1038/ejcn.2013.25.
- Bernstein AM, Titgemeier B, Kirkpatrick K, Golubic M, Roizen MF. Major cereal grain fibers and psyllium in relation to cardiovascular health. *Nutrients.* 2013;5(5):1471-87. doi: 10.3390/nu5051471.
- Masuda Y, Inoue M, Miyata A, Mizuno S, Nanba H. Maitake β -glucan enhances therapeutic effect and reduces myelosuppression and nephrotoxicity of cisplatin in mice. *Int Immunopharmacol.* 2009;9(5):620-6. doi: 10.1016/j.intimp.2009.02.005.
- Tohamy AA, El-Ghor AA, El-Nahas SM, Noshay MM. β -glucan inhibits the genotoxicity of cyclophosphamide, adriamycin and cisplatin. *Mutat Res.* 2003;541(1-2):45-53. doi: 10.1016/S1383-5718(03)00184-0.
- Ku SK, Lee YJ, Lee SD, Cho ER, Monn SB, Kim KY, Kwon YS, Kim JW. Nephroprotective effect of POLYCAN on acute renal failure induced by cisplatin in rats. *ISRN Vet Sci.* 2012;2012:862104. doi: 10.5402/2012/862104.
- Yagi K. Simple assay for the level of total lipid peroxides in serum or plasma. *Methods Mol Biol.* 1998;108:101-6. PMID: 9921519.
- Sedlak J, Lindsay RH. Estimation of total, protein-bound, and nonprotein sulfhydryl groups in tissue with Ellman's reagent. *Anal Biochem.* 1968;25:192-205. doi: 10.1016/0003-2697(68)90092-4.
- Sun Y, Oberley LW, Li Y. A simple method for clinical assay of superoxide dismutase. *Clin Chem.* 1988;34(3):497-500. PMID: 3349599.
- Aebi H, Wyss SR, Scherz B, Skvaril F. Heterogeneity of erythrocyte catalase II. Isolation and characterization of normal and variant erythrocyte catalase and their subunits. *Eur J Biochem.* 1974;48(1):137-45. PMID: 4141308.
- Paglia DE, Valentine WN. Studies on the quantitative and qualitative characterization of erythrocyte glutathione peroxidase. *J Lab Clin Med.* 1967;70(1):158-69. PMID: 6066618.
- Lowry OH, Rosebrough NJ, AL Farr RR. Protein measurement with the Folin phenol reagent. *Readings.* 1951;193(1):265-75. doi: 10.1016/0304-3894(92)87011-4.
- Sharawy N, Rashed L, Youakim MF. Evaluation of multi-neuroprotective effects of erythropoietin using cisplatin induced peripheral neurotoxicity model. *Exp Toxicol Pathol.* 2015;67(4):315-22. doi: 10.1016/j.etp.2015.02.003.
- Akman T, Akman L, Erbas O, Terek MC, Taskiran D, Ozsaran A. The preventive effect of oxytocin to cisplatin-induced neurotoxicity: an experimental rat model. *Biomed Res Int.* 2015;2015:1-5. doi: 10.1155/2015/167235.
- Turan MI, Cayir A, Cetin N, Suleyman H, Siltelioglu Turan I, Tan H. An investigation of the effect of thiamine pyrophosphate on cisplatin-induced oxidative stress and DNA damage in rat brain tissue compared with thiamine: thiamine and thiamine pyrophosphate effects on cisplatin neurotoxicity. *Hum Exp Toxicol.* 2014;33(1):14-21. doi: 10.1177/0960327113485251.
- Bayindir T, Iraz M, Kelles M, Kaya S, Tan M, Filiz A, Toplu Y, Kalcioğlu MT. The effect of beta glucan on cisplatin ototoxicity. *Indian J Otolaryngol Head Neck Surg.* 2014;66(2):131-4. doi: 10.1007/s12070-013-0623-0.
- Chari F, Belghith-Fendri L, Zaouri-Ellouzi S, Driss D, Blibech M, Kallel F, Bouaziz F, Mehdi Y, Ellouz-Chaabouni S, Ghorbel R. Antibacterial and antioxidant properties of mixed linkage beta-

- oligosaccharides from extracted β -glucan hydrolysed by *Penicillium occitanis* EG_L lichenase. *Nat Prod Res.* 2015;(August):1-7. doi: 10.1080/14786419.2015.1056185.
31. Schwartz B, Hadar Y. Possible mechanisms of action of mushroom-derived glucans on inflammatory bowel disease and associated cancer. *Ann Transl Med.* 2014;2(2):19. doi: 10.3978/j.issn.2305-5839.2014.01.03.
 32. Carozzi VA, Canta A, Oggioni N, Sala B, Chiorazzi A, Merigalli C, Bossi M, Marmiroli P, Cavaletti G. Neurophysiological and neuropathological characterization of new murine models of chemotherapy-induced chronic peripheral neuropathies. *Exp Neurol.* 2010;226(2):301-9. doi: 10.1016/j.expneurol.2010.09.004.
 33. Li D-W, Sun J-Y, Wang K, Zhang S, Hou Y-J, Yang M-F, Fu X-Y, Zhang Z-Y, Mao L-L, Yuan H, Fang J, Fan C-D, Zhu M-J, Sun B-L. Attenuation of cisplatin-induced neurotoxicity by cyanidin, a natural inhibitor of ros-mediated apoptosis in PC12 cells. *Cell Mol Neurobiol.* 2015:995-1001. doi: 10.1007/s10571-015-0194-6.
 34. Nakamura H, Yamashita N, Kanamaru Y, Tachibana T, Sekino Y, Chen S, Gotoh T, Tanaka F, Goshima Y. Quantitative analysis of intraneuronal transport in human iPS neurons. *J Pharmacol Sci.* 2015;128(4):1-9. doi: 10.1016/j.jphs.2015.06.006.
-

Correspondence:

Kürşat Kaya
Department of Biochemistry, Faculty of Pharmacy
Adiyaman University, Adiyaman, Turkey
Phone: +90 416 223 38 00/2793
kkaya@adiyaman.edu.tr

Received: Nov 08, 2015

Review: Jan 10, 2016

Accepted: Feb 11, 2016

Conflict of interest: none

Financial source: none

¹Research performed at Experimental Animals Unit and Neuroscience Laboratory, İnönü University, Malatya, Turkey.