



Gastroprotective and antioxidant effects of *Eremurus spectabilis* Bieb. methanol extract and its isolated component isoorientin on indomethacin induced gastric ulcers in rats¹

Esen Sezen Karaođlan^I, Abdulmecit Albayrak^{II}, Zerrin Kutlu^{III}, Yasin Bayır^{IV}

^IMD, Department of Pharmaceutical Botany, Faculty of Pharmacy, Atatürk University, Erzurum, Turkey. Technical procedures, manuscript writing.

^{II}MD, Department of Medical Pharmacology, Faculty of Medicine, Atatürk University, Erzurum, Turkey. Technical procedures.

^{III}MD, Department of Biochemistry, Faculty of Pharmacy, Ataturk University, Erzurum, Turkey. Technical procedures.

^{IV}MD, Department of Biochemistry, Faculty of Pharmacy, Ataturk University, Erzurum. Turkey. Design of the study, statistical analysis.

Abstract

Purpose: To investigate the gastroprotective effect of methanol extract of *E. spectabilis* and its major component isoorientin.

Methods: Effects of isoorientin and methanol extract of *E. spectabilis* were investigated in indomethacin-induced gastric damage model on rats. Famotidine was used as the standard antiulcer drug. Numerical density of ulcer areas and oxidative status were determined on stomach tissues of rats.

Results: All doses of isoorientin and methanol extract decreased MDA level and increased SOD activity and GSH levels in the stomach tissue of rats. When numerical density of ulcer areas were analyzed, the 500 mg/kg dose of methanol extract (84%) exhibited a similar effect to 20 mg/kg dose of standart drug famotidine (87%).

Conclusions: The gastroprotective effects of *E. spectabilis* and its major constituent isoorientin in rats for the first time. Detailed analyses suggested that potential antioxidant activity of both plant extract and isoorientin mediates the gastroprotective effect.

Key words: *Eremurus spectabilis*. Stomach Ulcer. Antioxidants. Rats.

■ Introduction

The peptic ulcer is a deterioration in the gastric or duodenal mucosa down to the submucosa. The various causes of gastric ulcer are stress, trauma, some diseases, helicobacter pylori, use of alcohol and cigarettes, and steroidal and nonsteroidal anti-inflammatory drugs (NSAIDs). Peptic ulcer regarded as a important common gastrointestinal disorder which can affect individuals during their lives¹⁻³. The reactive oxygen species (ROS) play an important role in the gastric ulcer formation induced by stress, ethanol and NSAIDs. The inflammation in the gastric tissue induced by indomethacin causes the formation of ROS⁴. Superoxide dismutase, catalase, glutathione reductase, β -carotene, glutathione peroxidase, β -tocopherol, glutathione, vitamins A and C are good antioxidant agents. In addition, these antioxidants are also effective in prevention stomach damage⁵.

The *Eremurus* genus is a member of Liliaceae family, including about 50 species. *E. spectabilis* is grown naturally in the eastern regions of Turkey. This plant, locally known as 'Çiris', and its fresh leaves sold and consumed as an edible vegetable in markets⁶.

According to ethnobotanical studies, *E. spectabilis* is used for the treatment of numerous ailments like scabies, diabetes and intestinal diseases⁷⁻⁹. In addition to these, *E. spectabilis* has also antibacterial and antioxidant activities^{10,11}. Carvone, carvacrol, pentane, (E)-caryophyllene, valencene were found to be as main constituents of the essential oil of *E. spectabilis*¹². It is reported that inosine, methyl linolenate, chrysophanol, isoorientin, β -sitosterol and sucrose were also isolated from *E. spectabilis*¹³. In a previous study, we isolated a high amount of isoorientin from *E. spectabilis*¹⁴. Isoorientin is a flavonoid compound in the

structure of C-glycosylflavone¹⁵. Flavonoids are known to have many biological activities. Apart from that, gastroprotective effects of flavonoids are also recorded¹⁶. Herbal treatment has been used by people for a very long time. *E. spectabilis* is used in Turkish folk medicine to treat gastrointestinal disorders. The gastroprotective effect of *E. spectabilis* and its major component isoorientin, has not been studied previously. Therefore, the aim of this study was to investigate the effects of *E. spectabilis* methanol extract and its isolated constituent isoorientin in indomethacin-induced gastric damage model and to determine the effects of methanol extract and isoorientin on antioxidant parameters in rat stomach tissue.

■ Methods

Experiments were performed with male albino Wistar 48 rats weighing 220-280 g. All rats were provided from Ataturk University's Experimental Animal Laboratory at the Medicinal and Experimental Application and Research Centre. When working with experimental animals in this study, national rules were taken as basis and required permission was obtained from Ataturk University's local animal care committee (93722986-000-E.1700331781).

Chemicals

All of the chemicals required for the study were purchased from Sigma Chemical Co. (Munich, Germany). Indomethacin (Endol 25 mg; 25 cap.) was obtained from DEVA Holding A.S. (Istanbul, Turkey); famotidine (Famodin 20 mg; 30 tab) was obtained from Sandoz Drug Company (Istanbul, Turkey); and thiopental sodium was obtained from IE Ulagay A.S. (Istanbul, Turkey).

Plant material

The aerial parts of *E. spectabilis* were collected from İđdasor (Erzurum Province, 1920 m, Turkey) in April 2014. A voucher specimen was stored at the Herbarium of Atatürk University, Faculty of Pharmacy (AUEF1189). It was identified by Esen Sezen Karaođlan.

Previous extraction and isolation studies

Fresh *E. spectabilis* leaves were extracted with methanol (MeOH) at 40°C after drying and powdering. The MeOH extract was filtered and evaporated. The dry MeOH extract was suspended in water and extracted with n-hexane, dichloromethane (CH₂Cl₂), ethyl acetate (EtOAc), and n-butanol, respectively. Organic phases were concentrated to dryness under vacuum. Isoorientin was isolated from EtOAc extract via Sephadex LH-20 column eluting with MeOH and then silica gel column eluting with CH₂Cl₂: MeOH: H₂O (90:10:1→50:50:5). The structure of isoorientin was elucidated by ¹H NMR, ¹³C NMR, 2D NMR and Q-TOF by Sezen Karaođlan *et al.*¹⁴.

Experimental design of indomethacin-induced ulcer model

Eight experimental groups consisting of six rats were formed:

Group 1: Healthy control;

Group 2: Indomethacin 25 mg/kg control (IND);

Group 3: Indomethacin 25 mg/kg + famotidine 20 mg/kg administered orally (IND+FAM);

Group 4: Indomethacin 25 mg/kg + isoorientin 25 mg/kg administered orally (IND+ISO25);

Group 5: Indomethacin 25 mg/kg + isoorientin 50 mg/kg administered orally

(IND+ISO50);

Group 6: Indomethacin 25 mg/kg + isoorientin 100 mg/kg administered orally (IND+ISO100);

Group 7: Indomethacin 25 mg/kg + plant extract 250 mg/kg administered orally (IND+ES250);

Group 8: Indomethacin 25 mg/kg + plant extract 500 mg/kg administered orally (IND+ES500).

Ulcer model

For ulcer model induction in rats previously described indomethacin-ulcer model was used with no modification^{17,18}. NSAID induced ulcer model is one of the the most commonly used gastric ulcer models¹⁹. In this study; the isoorientin groups received 25, 50, 100 mg/kg doses and the plant extract groups received 250 and 500 mg/kg doses and of drugs as a pretreatment by oral gavage, after which the rats were fed anything for 24 hours. Healthy control and indomethacin control groups received 1 ml of saline as vehicle by oral gavage. Then, famotidine (positive control)¹⁷, isoorientin and plant extract were administered to the corresponding rat groups in the above-mentioned doses by oral gavage. Five minutes after the famotidine, isoorientin and plant extract treatments, a dose of 25 mg/kg of indomethacin was suspended in isotonic saline and administered by oral gavage to all groups except healthy group. Six hours after the administration of indomethacin, all rats were euthanized by administering intraperitoneal thiopental at a dose of 50 mg/kg. The ulcerated areas of the removed stomachs were examined macroscopically. Ulcer areas were evaluated by stereo-investigator, and numerical densities of ulcerated areas were calculated by software, as described below.

Numerical density (ND)

Numerical density can be defined as the number of particles in the unit volume. For optical dissector, total number of particles (N) counted should be divided to dissector volume calculate Numerical density of that particles. In our study Numerical Density of Ulcerated area has been calculated by dividing total number of ulcer area to total volume of stomach tissue. In our study, stereological analyses were conducted in a stereology workstation using stereology software (Stereo Investigator version 9.0; MBF Bioscience, Colchester, VT). The numerical ulcer hematoma densities were calculated by the following formula:

Numerical Density (ND): Total Markers Counted x 1000 (μm^2) / Sampling Grid Area (XY) (μm^2)

Biochemical analyses

Biochemical investigation of stomachs tissues

After the macroscopic analysis, the stomach tissues were stored at -80°C . All stomach tissues were milled in liquid nitrogen using a TissueLyser II grinding jar set (Qiagen, Hilden, Germany). The 50 mg of ground tissues were mixed fully in 1ml PBS buffer in an Eppendorf tube using the TissueLyser II, and then centrifuged. Superoxide dismutase (SOD) activity²⁰, malondialdehyde (MDA)²¹ and glutathione (GSH) levels²² from each samples were measured by repeatedly at room temperature, with an ELISA reader²³. The average absorbances were calculated. A standard curve was drawn and the equation was obtained from the absorbance of the standards. Linear SOD, GSH, and MDA concentrations were calculated considering

this equation. The SOD, GSH, MDA levels were explicated as U/mg protein, nmol/mg protein. The data are offered as mean \pm standard deviation (SD) per mg protein.

Protein determination

Protein concentration were carried out by the Lowry method using commercial protein standards (Total protein kit-TP0300- 1 KT; Sigma Chemical Co. (Munich, Germany)).

Statistical analyzes

Statistical Package for the Social Sciences (SPSS) version 20.0 (SPSS Inc., Chicago, IL) software was used for the statistical analysis. The results are presented as means \pm SD. Comparisons between groups were performed using one-way analysis of variance (ANOVA) and the Duncan Multiple Comparison Test which allows inter-comparison of all groups. Significance was accepted at a level of $p < .05$.

■ Results

Indomethacin-induced ulcer test

When we analyzed the numerical densities (ND) of the ulcer hematoma areas, the 500 mg/kg dose of methanol extract showed a significant 84% antiulcer effect ($p < 0.05$), similar to that of famotidine 87% ($p < 0.05$). Macroscopical photographs (Figure 1) and the ulcer index area of isoorientin (25, 50, 100 mg/kg doses), methanol extract (250, 500 mg/kg doses), famotidine (20 mg/kg dose) and control groups (Figure 2) are shown in figures. All doses of both extract and isoorientin exerted significant antiulcer effect ($p < 0.05$) as well as famotidine ($p < 0.05$).

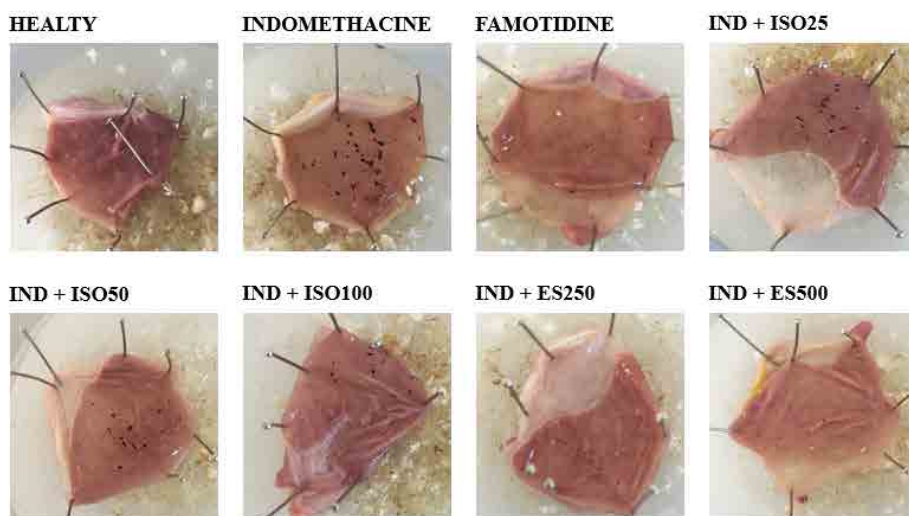


Figure 1 - Sample macroscopical photographs of experimental groups.

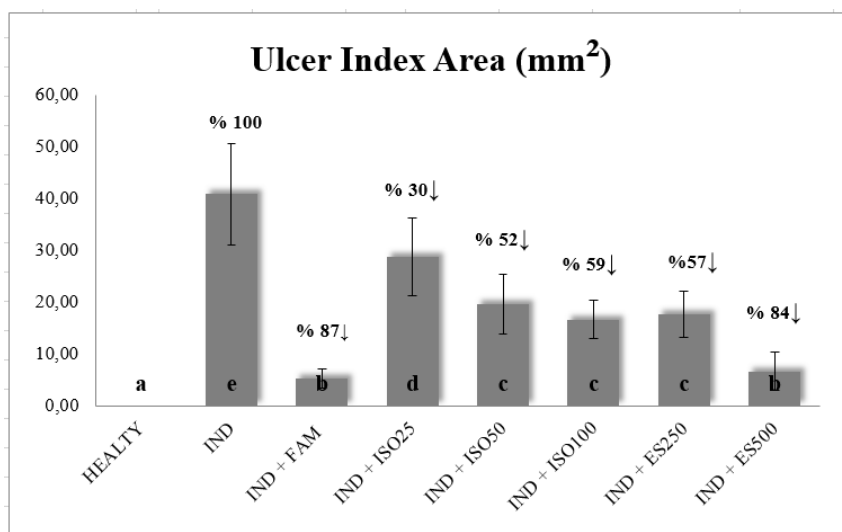


Figure 2 - Ulcer index areas of the groups underwent indomethacin ulcer model. Columns with the same letter are not significantly different; columns with different letters indicate significant differences between the groups according to the Duncan test ($p < 0.05$). Results are means \pm SD. $N = 6$ animals per group. (Numerical density can be defined as the number of particles in the unit volume. For optical dissector, total number of particles (N) counted should be divided to dissector volume calculate Numerical density of that particles. In our study Numerical Density of Ulcerated area has been calculated by dividing total number of ulcer area to total volume of stomach tissue). IND: indomethacin; ISO: isoorientin; ES: extract.

Biochemical analyses

The all doses of isoorientin and methanol extract significantly ($p < 0.05$) decreased MDA. The most effective decline

was observed at the 500 mg/kg dose of methanol extract dose. All doses of isoorientin and methanol extract significantly increased SOD activity ($p < 0.05$) and GSH levels ($p < 0.05$) in the stomach tissue of rats. the 500 mg/kg

dose of methanol extract maximally increased the SOD activity and GSH levels. The SOD activity, GSH and MDA levels of isoorientin (25,

50, 100 mg/kg doses), methanol extract (250, 500 mg/kg doses), famotidine (20 mg/kg dose) and control groups (Figures 3 to 5).

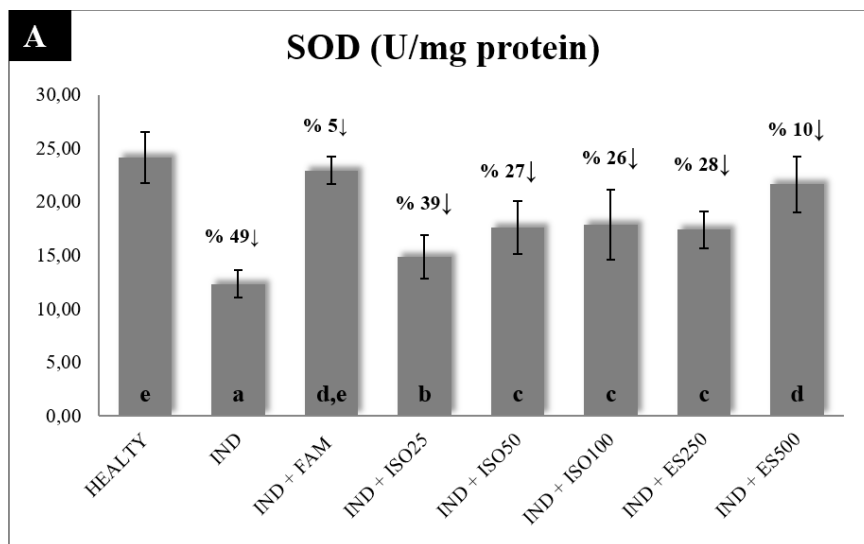


Figure 3 - Stomach tissue SOD activity in groups underwent indomethacin ulcer model. Columns with the same letter are not significantly different; columns with different letters indicate significant differences between the groups according to the Duncan test ($p < 0.05$). Results are means \pm SD. N $\frac{1}{4}$ 6 animals per group. IND: indomethacine; ISO: isoorientin; ES: extract.

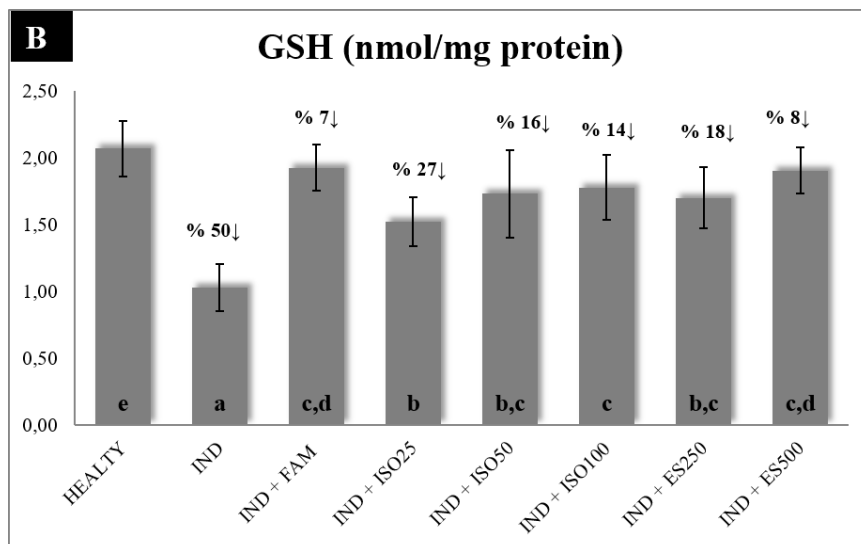


Figure 4 - Stomach tissue GSH level in groups underwent indomethacin ulcer model. Columns with the same letter are not significantly different; columns with different letters indicate significant differences between the groups according to the Duncan test ($p < 0.05$). Results are means \pm SD. N $\frac{1}{4}$ 6 animals per group. IND: indomethacine; ISO: isoorientin; ES: extract.

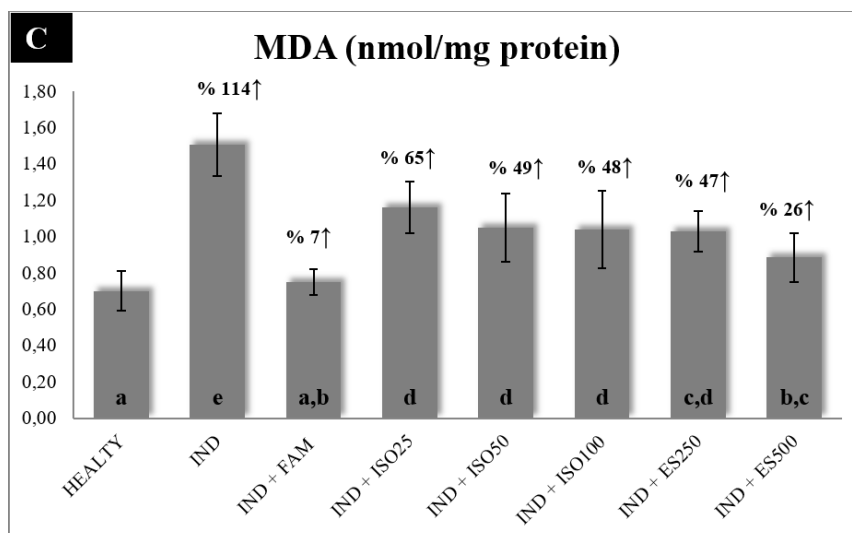


Figure 5 - Stomach tissue MDA level in groups underwent indomethacin ulcer model. Columns with the same letter are not significantly different; columns with different letters indicate significant differences between the groups according to the Duncan test ($p < 0.05$). Results are means \pm SD. N $\frac{1}{4}$ 6 animals per group. IND: indomethacin; ISO: isoorientin; ES: extract.

Discussion

People have been using plants for therapeutic purposes for many years. *E. spectabilis* is locally known as 'Çiris', and is grown naturally in Erzurum, Erzincan, Sivas, Kars, Yozgat, Bitlis, Usak, Agri, Van, Artvin and Ardahan regions in Turkey. This plant is consumed by people as vegetables. Its fresh leaves sold low-priced in markets and contains a high amount of isoorientin. Any toxic effects are not recorded for this plant.

Peptic ulcer is an important disturbance affecting people's quality of life. NSAIDs is one of the important causes of peptic ulceration process¹⁻³. It is registered that *E. spectabilis* is used in gastrointestinal disorders. In a previous study, we isolated a high amount of isoorientin from *E. spectabilis*. Isoorientin is a substance in the flavonoid structure which has many biological activities.

This study investigated the antiulcer activity and the effect on oxidant and antioxidant parameters of different doses isoorientin and methanol extract of *E. spectabilis* in rat stomach tissue. It was

observed that the gastroprotective efficacy increased both in the groups isoorientin and in the groups methanol extract depending on the dose. When numerical density of ulcer areas were analyzed, the 500 mg/kg dose of methanol extract (84%) almost exhibited a similar effect to 20 mg/kg dose of standart drug famotidine (87%).

The 500 mg/kg dose of extract showed the highest efficacy, although both extract and isoorientin were observed to be effective when compared to the indomethacin group. In a previous study, ethyl acetate extract of *Wilburandia ebracteata* showed high anti ulcer effect. This effect was attributed to the substances flavonoid structure, 3',4',5,6,7,8-hexahydroxyflavonol, orientin, luteolin, 6-methoxy-luteolin, vitexin, isoorientin, isovitexin²⁴. In our study, we also think that the high efficacy of the plant extract is not due to a single molecule isoorientin, but may be due to the synergistic effect of the different components in it.

We evaluated the effects of isoorientin and methanol extract of *E. spectabilis* on local oxidative stress parameters in the stomach

tissues of rats as a contributing antiulcer mechanism. Indomethacin dramatically increased stomach MDA content, one of the most widely used parameters as a lipid peroxidation indicator²⁵⁻²⁹, while all doses of isoorientin and methanol extract decreased MDA. In addition, indomethacin caused a significant decrease in stomach antioxidant status, namely decreased SOD activity and GSH levels. Both SOD and GSH are known to be antioxidant agents in inflammatory and ulcerative conditions^{30,31}. In previous studies it was reported that the *E. spectabilis* had significant antioxidant and free radical scavenging activity. In addition, it is known that isoorientin which is a flavonoid, has also highly antioxidant activity^{32,33}. In our study, all doses of isoorientin and methanol extract increased SOD activity and GSH levels in the stomach tissue of rats. It has been observed that especially the 500 mg/kg dose of methanol extract increased these parameters at the approximate value of standart drug famotidine.

It is registered that *E. spectabilis* leaves are used traditionally in gastrointestinal disorders¹². The results of our work are also supportive of this gastroprotective effect.

■ Conclusions

E. spectabilis is a vegetable that is consumed safely among the population. The fresh leaves of this plant are sold at low prices in the markets. It contains high amount isoorientin, has significant gastroprotective effect. Finding new molecules for the pharmaceutical industry is very important, but these studies are costly and time consuming. For this reason, the importance of effective, low-priced and easily accessible standardized plant extracts is increasing. *E. spectabilis* extract may be a potential anti-ulcer agent in the future. Scientific research in this area needs to be increased.

■ References

1. Tarnawski AS, Ahluwalia A. Molecular mechanisms of epithelial regeneration and neovascularization during healing of gastric and esophageal ulcers. *Curr Med Chem.* 2012;19:16-27. PMID: 22300072.
2. Najm WI. Peptic ulcer disease. *Prim Care.* 2011;38:383-94. PMID: 21872087.
3. Oppong P, Majumdar D, Atherton J, Bebb J. *Helicobacter pylori* infection and peptic ulcers. *Medicine* 2015;43:215-22.
4. Das D, Bandyopadhyay D, Bhattacharjee M, Banerjee RK. Hydroxyl radical is the major causative factor in stress-induced gastric ulceration. *Free Radical Biol Med.* 1997;23:8-18. PMID: 9165292.
5. Mates JM, Perez-Gomez C, Nudes de Castro I. Antioxidant enzymes and human diseases. *Clin Biochem.* 1999;32:595-603. PMID: 10638941.
6. Tuzlacı E. Çiriş plants of Turkey. *J Pharm Univ Mar.* 1985;1:69-89.
7. Karaman S, Kocabaş YZ. Traditional medicinal plants of K. Maraş (Turkey). *Sciences.* 2001;1:125-8.
8. Arıtuluk ZC, Ezer N. Halk arasında Diyabete Karşı Kullanılan Bitkiler (Türkiye)-II. *Hacettepe Üniv Ecz Fak Derg.* 2012;32:179-208.
9. Korkmaz M, Karakuş S. Traditional uses of medicinal plants of Üzümlü District, Erzincan, Turkey. *Pak J Bot.* 2015;47:125-34. PMID: 17714898.
10. Kanaani S, Sani AM. Chemical composition of essential oils and in vitro antibacterial activity of methanolic extract of *Sonchus arvensis* and *Eremurus spectabilis* against food-borne pathogenic bacteria. *J Essent Oil Bear.* 2015;18:1093-9.
11. Taskin T, Bitis L, Birteksöz S. Antioxidant and antimicrobial activities of different extracts from *Eremurus spectabilis* leaves. *Spatula DD.* 2012;2:213-7.
12. Karaman K, Polat B, Ozturk I, Sagdic O, Ozdemir C. Volatile compounds and bioactivity of *Eremurus spectabilis* (Ciris), a Turkish Wild Edible Vegetable. *J Med Food.* 2011;14:1238-43. PMID: 21548806.
13. Karakaya L, Akgül Y, Nalbantsoy A. Chemical constituents and in vitro biological activities of *Eremurus spectabilis* leaves. *Nat Prod Res.* 2017;20:1-6. PMID: 28278652.

14. Sezen Karaođlan E, Gündođdu G, Seęme M, Senol O, Demirkaya Milođlu F, Dodurga Y, Tüfekęi AR. *Eremurus spectabilis*, rich source of isoorientin: isolation, quantification and anti-cancer activity on SH-SY5Y neuroblastoma cells. *Curr Pharmaceutical Analysis*. 2018;13. [Epub ahead of print]. doi: 10.2174/1573412913666170822162527.
15. Afifi FU, Khalil E, Abdalla S. Effect of isoorientin isolated from *Arum palaestinum* on uterine smooth muscle of rats and guinea pigs. *J Ethnopharmacol*. 1999;65:173-7. PMID: 10465658.
16. Zayachkivska OS, Konturek SJ, Drozdowicz D, Konturek PC, Brzozowski T, Ghegotsky MR. Gastroprotective effects of flavonoids in plant extracts. *J Physiol Pharmacol*. 2005;56:219-31.
17. Halici Z, Polat B, Cadirci E, Topcu A, Karakus E, Kose D, Albayrak A, Bayir Y. Inhibiting renin angiotensin system in rate limiting step by aliskiren as a new approach for preventing indomethacin induced gastric ulcers. *Chem Biol Interact*. 2016;25;258:266-75.
18. Atalay F, Odabasoglu F, Halici M, Cakir A, Cadirci E, Aslan A, Aydin Berktas O, Kazaz C. Gastroprotective and antioxidant effects of *Lobaria pulmonaria* and its metabolite rhizonyl alcohol on indomethacin-induced gastric ulcer. *Chem Biodivers*. 2015;12(11):1756-67.
19. Suleyman H, Albayrak A, Bilici M, Cadirci E, Halici Z. Different mechanisms in formation and prevention of indomethacin-induced gastric ulcers. *Inflammation*. 2010;33(4):224-34.
20. Sun Y, Oberley LW, Li YA. A simple method for clinical assay of superoxide dismutase. *Clin Chem*. 1988;34:497-500. PMID: 3349599.
21. Ohkawa H, Ohishi N, Yagi K. Assay for lipid peroxides in animal tissues by thiobarbituric acid reaction. *Anal Biochem* 1979;95:351-8. PMID: 36810.
22. Sedlak J, Lindsay RH. Estimation of total, protein-bound, and nonprotein sulfhydryl groups in tissue with Ellman's reagent. *Anal Biochem*. 1968;25:192-205. PMID: 4973948.
23. Bayir Y, Karagoz Y, Karakus E, Albayrak A, Sengul O, Can I, Yayla N, Kuskun U, Keles MS. *Nigella sativa* reduces tissue damage in rat ovaries subjected to torsion and detorsion: oxidative stress, proinflammatory response and histopathological evaluation. *Gynecol Obstet Invest*. 2012;74:41-9. PMID: 22441173.
24. Coelho RG, Gonzalez FG, Sannomiya M, Di Stasi LC, Vilegasa W. Gastric anti-ulcer activity of leaf fractions obtained of polar extract from *Wilbrandia ebracteata* in mice. *Nat Prod Res*. 2009;23:51-9. PMID: 18989825.
25. Suleyman H, Cadirci E, Albayrak A, Polat B, Halici Z, Koc F, Hacimuftuoglu A, Bayir Y. Comparative study on the gastroprotective potential of some antidepressants in indomethacin-induced ulcer in rats. *Chem-Biol Interact*. 2009;180:318-24. PMID: 19497431.
26. Dengiz GO, Odabasoglu F, Halici Z, Cadirci E, Suleyman H. Gastroprotective and antioxidant effects of montelukast on indomethacin-induced gastric ulcer in rats. *J Pharmacol Sci*. 2007;105:94-102. PMID: 17895592.
27. Altinbas B, Yilmaz MS, Savci V, Jochem J, Yalcin M. Centrally injected histamine increases posterior hypothalamic acetylcholine release in hemorrhage-hypotensive rats. *Aut Neurosci Basic Clin*. 2015;187:63-9. PMID: 25468497.
28. Jochem J, Zwirska-Korcza K, Sowa P, Berdowska A. Interactions between the histaminergic and angiotensinergic systems in the central cardiovascular regulation in rats. *Inflam Res*. 2006;55:69-70. PMID: 16547806.
29. Cadirci E, Suleyman H, Aksoy H, Halici Z, Ozgen U, Koc A, Ozturk N. Effects of *Onosma armeniacum* root extract on ethanol-induced oxidative stress in stomach tissue of rats. *Chem Biol Interact*. 2007;170:40-8. PMID: 17681286.
30. Kaplan KA, Odabasoglu F, Halici Z, Halici M, Cadirci E, Atalay F, Aydin O, Cakir A. Alpha-Lipoic acid protects against indomethacin-induced gastric oxidative toxicity by modulating antioxidant system. *J Food Sci*. 2012;77:224-30. PMID: 23057764.
31. Odabasoglu F, Halici Z, Cakir A, Halici M, Aygun H, Suleyman H, Cadirci E, Atalay F. Beneficial effects of vegetable oils (corn, olive and sunflower oils) and alpha-tocopherol on anti-inflammatory and gastrointestinal profiles of indomethacin

in rats. Eur J Pharmacol. 2008;591:300-6.
PMID: 18621042.
32. Tosun M, Erciřli E, Ozer H, Turan M, Polat T, Ozturk E, Padem H, Kilicgun H. Chemical composition and antioxidant activity of foxtail lily (*Eremurus spectabilis*). Acta Sci Pol Hortorum Cultus. 2012;11:145-53.

PMID: 25649168.
33 Joshi KR, Devkota HP, Nakamura T, Watanabe T, Yahara S. Chemical constituents and their DPPH radical scavenging activity of nepalese crude drug *Begonia picta*. Rec Nat Prod. 2015;9:446-50.

Correspondence:

Esen Sezen Karaođlan
Department of Pharmaceutical Botany, Faculty of Pharmacy
Atatürk University, Erzurum Turkey
Phone: 0 543 659 29 03
Fax: +90 (442) 2315201
esen.karaoglan@atauni.edu.tr

Received: Mar 10, 2018

Review: May 08, 2018

Accepted: June 12, 2018

Conflict of interest: none

Financial source: none

¹Research performed at Department of Pharmaceutical Botany, Faculty of Pharmacy, Department of Medical Pharmacology, Faculty of Medicine and Medical Experimental Application and Research Center, Atatürk University, Erzurum, Turkey.

