

Robotic Roux-en-Y hepaticojejunostomy for primary intrahepatic lithiasis after laparoscopic right hepatectomy

Marcel Autran C MACHADO, André O ARDENGH and Fábio F MAKDISSI

Received: 4 May 2020
Accepted: 1 June 2020

Minimally invasive surgery has gained increasing acceptance in recent years, expanding to hepatobiliary procedures. The laparoscopic route is already considered viable, safe and effective. However, the applicability of this technique is still restricted to centers with enhanced resources and greater surgical volume^(1,2). Robotic system provides a good opportunity to perform these challenging procedures in the minimally invasive context and expand its use to a larger number of surgeons. Robotic hepaticojejunostomy has been more commonly used during reconstruction after pancreatoduodenectomy. This video shows a robotic Roux-en-Y hepaticojejunostomy in a patient with primary intrahepatic lithiasis and previous laparoscopic right hepatectomy (FIGURES 1 and 2).

We present the case of a 45-year-old woman with primary intrahepatic lithiasis. She has been submitted to a laparoscopic right hepatectomy by the same team 5 years earlier for intermittent cholangitis and unilateral disease. Disease has progressed, and she resumed cholangitis. Due to multiple previous papillotomies that led to stenosis, 4 months later, she progressed with severe acute cholangitis. MRI showed dilatation of the intra and extrahepatic bile ducts. Multidisciplinary team decided for a Roux-en-Y hepaticojejunostomy (E-VIDEO*). Another option may include the hepatico-duodenostomy but it is preferentially used in elderly patients. Robotic approach was proposed. Technique used five ports. The first 12-mm trocar was inserted using open method into the infraumbilical area and a pneumoperitoneum was created at 14 mm Hg pressure. After docking the robotic system, adhesions from previous surgery are divided and liver is retracted upwards. Proximal jejunum is transected 20 cm from the Treitz ligament and transposed to the subhepatic area through mesenteric window. Hepatic hilum is then identified and intraoperative fluorescent cholangiography with indocyanine green⁽³⁾ helped us to identify the common bile duct. Anterior aspect of hepatic duct is opened with scissors and a latero-lateral hepaticojejunostomy is performed with 4-0 absorbable suture in running fashion⁽⁴⁾. The anastomosis is checked using fluorescent cholangiography. Roux-en-Y loop is

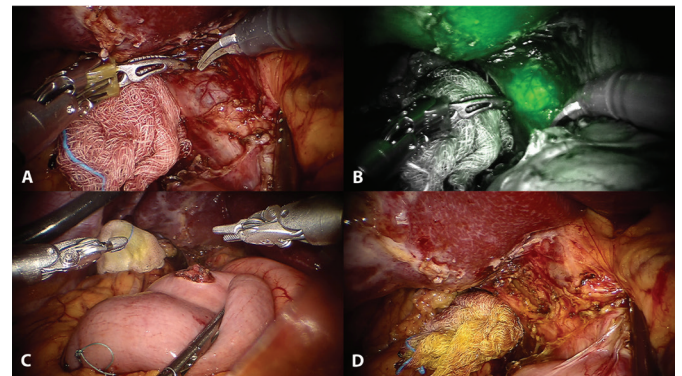


FIGURE 1. Robotic Roux-en-Y hepaticojejunostomy.

A. Intraoperative view of hilar dissection. B. Intraoperative identification of main bile duct by fluorescent cholangiography with indocyanine green. C. Intraoperative view of jejunal loop opening. D. Intraoperative view after opening of bile duct.

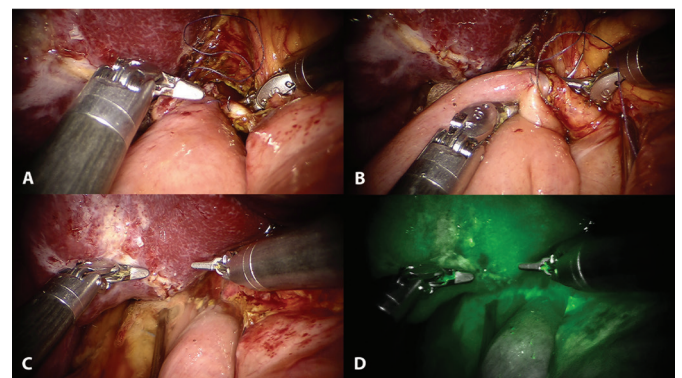


FIGURE 2. Robotic Roux-en-Y hepaticojejunostomy.

A. Intraoperative view after completion of posterior layer of hepaticojejunostomy. B. Intraoperative view after completion of hepaticojejunostomy. C. Intraoperative leak test for anastomosis patency checking. D. Anastomosis patency is checked using fluorescent cholangiography.

Declared conflict of interest of all authors: none

Disclosure of funding: no funding received

Hospital 9 de Julho, São Paulo, SP, Brasil.

Corresponding author: Marcel Autran C. Machado, M.D. E-mail: dr@drmarcel.com.br

* Video: <https://www.youtube.com/watch?v=v2r5q-95-U>

completed with the use of stapler. Opening is closed with absorbable 3-0 running suture. Operative time was 252 minutes, with minimal bleeding, and no need for blood transfusion. There was no need of intensive care unit and she was discharged on the 3rd postoperative day. She is asymptomatic 6 months after the procedure. Robotic Roux-en-Y hepaticojejunostomy is feasible and safe even in patients with previous hepatectomy. Long-term results, cost-benefit analysis as well learning curve studies are necessary^(5,6). This video shows the different steps (E-VIDEO*) necessary to perform this complex operation.

Authors' contribution

Machado MA and Makdissi FF carried out the operative procedure. Ardengh AO edited the video. Ardengh AO and Makdissi FF supervised and commented on the manuscript. All authors discussed the results and contributed to the final manuscript.

Orcid

Marcel Autran C Machado: 0000-0002-4981-7607.

André O. Ardengh: 0000-0001-6373-5598.

Fábio Ferrari Makdissi: 0000-0001-8202-5890.

Machado MAC, Ardengh AO, F Makdissi F. Hepático-jejunosomia em Y de Roux por via robótica após hepatectomia direita laparoscópica. *Arq Gastroenterol.* 2020;57(3):337-8.

REFERENCES

1. Machado MA, Makdissi FF, Surjan RC, Teixeira ARF, Sepúlveda Jr A, Bacchella T, et al. Laparoscopic right hemihepatectomy for hepatolithiasis. *Surg Endosc.* 2008;22:245.
2. Machado MA, Herman P, Rocha JR, Machado MC. Primary intrahepatic lithiasis: report of a case treated by laparoscopic bilioenteric anastomosis. *Surg Laparosc Endosc Percutan Tech.* 1999;9:207-10.
3. Vos JJ, Wietasch JK, Absalom AR, Hendriks HG, Scheeren TW. Green light for liver function monitoring using indocyanine green? An overview of current clinical applications. *Anaesthesia.* 2014;69:1364-76.
4. Monteiro Cunha JE, Herman P, Machado MCC, Penteado S, Maluf Filho F, Jukemura J, et al. A new biliary access technique for the long-term endoscopic management of intrahepatic stones. *J Hepatobiliary Pancreat Surg.* 2002;9:261-4.
5. Prasad A, De S, Mishra P, Tiwari A. Robotic assisted Roux-en-Y hepaticojejunostomy in a post-cholecystectomy type E2 bile duct injury. *World J Gastroenterol.* 2015;21:1703-6.
6. Lee H, Kwon W, Han Y, Kim JR, Kim SW, Jang JY. Comparison of surgical outcomes of intracorporeal hepaticojejunostomy in the excision of choledochal cysts using laparoscopic versus robot techniques. *Ann Surg Treat Res.* 2018;94:190-5.

