

GIANT OSTEOLASTOMA OF TEMPORAL BONE

CASE REPORT

EBERVAL GADELHA FIGUEIREDO, EDUARDO VELLUTINI*, OCTÁVIO VELASCO*,
MÁRIO SIQUEIRA*, PATRÍCIA BOUGAR***

ABSTRACT - Benign osteoblastoma is an uncommon bone tumor accounting for approximately 1% of all bone tumors. There are only 35 cases of skull osteoblastoma reported in the literature. We describe the case of a 23 year old male with a giant osteoblastoma of temporal bone submitted to a total removal of the tumor after an effective embolization of all external carotid branches. The authors discuss diagnostic and management aspects of this uncommon skull tumor.

KEY WORDS: osteoblastoma, temporal bone, embolization.

Osteoblastoma gigante de osso temporal: relato de caso

RESUMO - Osteoblastoma é tumor benigno raro representando cerca de 1% de todos os tumores ósseos. Até o momento apenas 35 casos com acometimento craniano foram descritos na literatura. Os autores descrevem um caso de osteoblastoma gigante de osso temporal em paciente de 23 anos do sexo masculino. O tumor foi completamente ressecado após embolização de ramos nutrientes oriundos da carótida externa. São discutidos aspectos diagnósticos e terapêuticos deste raro tumor craniano.

PALAVRAS-CHAVE: osteoblastoma, osso temporal, embolização.

Benign osteoblastoma is an uncommon bone tumor accounting for approximately 1% of all bone tumors¹. This neoplasm was initially reported by Jaffe and Mayer in 1932 under various names such as "osteogenic fibroma of bone" and "giant osteoma osteoid"². The current term was proposed in 1956 by Jaffe³ and Lichtenstein⁴. Since then, there was an increasing number of cases reported in the literature, most of them arising in the axial skeleton (spine and major long bones of the lower extremities).

Skull lesions have been sporadically described and count for 2.3 to 20% of all cases^{4,5}, most of them in the temporal bone. Their incidence is still controversial but there is no more than 35 cases of skull osteoblastoma reported in the literature. We present a case of a giant temporal osteoblastoma and discuss the best pre and intraoperative management of these patients.

CASE REPORT

A 23 year old male presented with a 3 years history of headache and swelling in his left temporal region associated with hearing impairment in the ipsilateral ear. The local examination disclosed a hard and painful mass in the left temporal bone with extension to the parietal region. Neurological examination was normal except

Hospital das Clínicas da Faculdade de Medicina da Universidade de São Paulo, São Paulo-SP, Brasil:
*MD, Departamento de Neurocirurgia; **MD, Departamento de Otorrinolaringologia. Aceite: 13-fevereiro-1998.

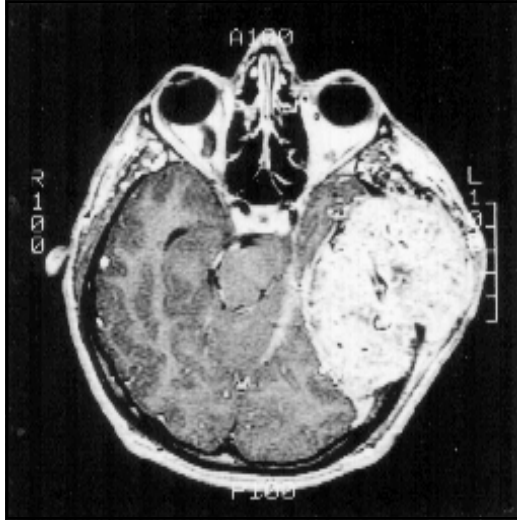

Fig 1. T1-weighted magnetic resonance image. Axial view with gadolinium enhancement showing a well-circumscribed lesion causing mass effect against temporal parenchyma.

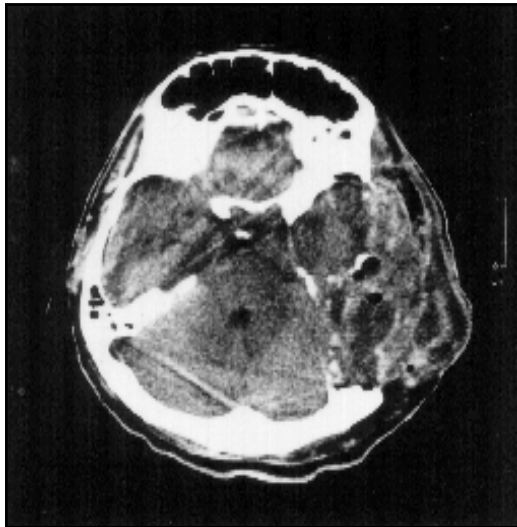


Fig 2. Postoperative axial computed tomography image displaying no residual tumor.

for a left side hearing loss. Skull X-rays demonstrated an osteolytic expansive lesion, well circumscribed, heavily mottled by scattered calcifications, involving the left temporal bone. At the CT-examination the lesion appeared to involve the mastoidal, petrous and scamous portions of temporal bone, the external auditory canal and extended anteriorly till the temporo-mandibular joint. There were no signs of brain infiltration even at MRI examination (Fig 1). The temporal lobe was elevated by a totally extradural mass. The patient was submitted to a cerebral angiography that demonstrated a highly vascularized tumor supplied by branches of the external carotid artery.

After an effective embolization of all those external carotid branches the patient was submitted to a total removal of the tumor through a transtemporal approach. There was a very thin outer bony cortex covering a very

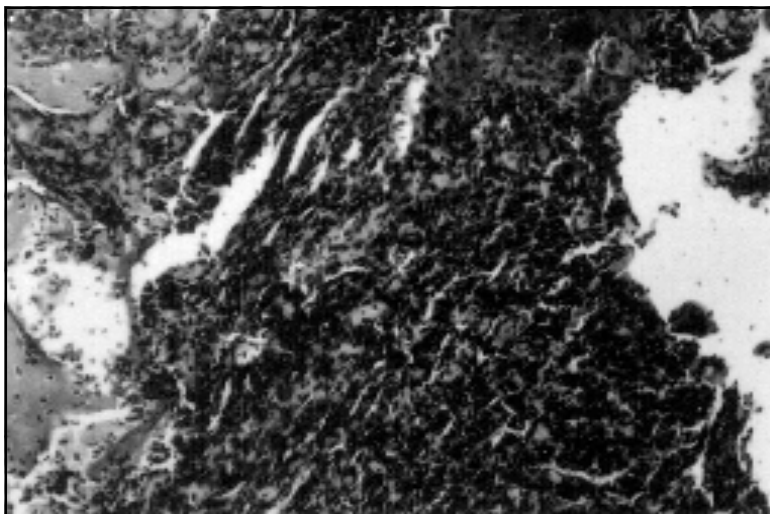


Fig 3. Hematoxylin-eosin stained sections showing proliferation of interlacing trabeculae in a fibrovascular stroma. Original magnification x40.

vascular grayish mass with areas of soft bony lamellae. Because of the large volume, the margins of the mass were first identified, then it was totally "en bloc" removed (Fig 2). There was no adherence to the facial nerve, carotid artery or jugular vein. On the other hand, the dura-mater of the floor of the fossa media was very thin and could not be totally preserved. The reconstruction was performed with temporalis fascia. In the postoperative period the patient developed a transient cerebrospinal fluid (CSF) fistula and a meningitis, responsive to lumbar drainage and antibiotic therapy. He was discharged two weeks after surgical treatment without neurologic deficits. After 18 months of follow-up, there is no evidence of recurrence. The patient refused the surgical repair of the skull defect planned for him.

The pathological examination demonstrated an actively proliferative well vascularized connective tissue with scant osteoid tissue and calcifications. There were long interanastomosing trabeculae of osteoid and woven bone rimmed by a single row of osteoblasts with a loose fibrovascular stroma compatible with an osteoblastoma (Fig 3).

DISCUSSION

Benign osteoblastoma is a rare bone tumor. Males are affected more often than females in the majority of series⁵⁻⁷. The average age of occurrence is 17 years, ranging from 4 to 78 years^{8,9}. In the patients with osteoblastoma the mean age is around 22 years¹⁰. The histological pattern is a highly vascular osteoblastic connective tissue stroma with osteoid and primitive bone deposition and osteoblasts without any mitotic activity or atypia¹¹. Although it can affect every bone in the body, the most frequent sites include vertebrae, femur, jaw bones and tibia¹³. The skull is rarely affected, and when it happens, usually does at its base than at its vault¹². The temporal bone is the preferential site for those skull tumors^{1,12,13}, and there are reports of clival and even intracerebral osteoblastomas^{12,14}.

Progressive local pain is the most frequent clinical presentation and can be observed in 87% of patients. Local swelling and tenderness are also mentioned. The average duration of those symptoms are 2 years¹¹.

The radiological evaluation demonstrates an expanding radiolucent defect with a variable amount of calcification in the matrix, involving both tables, preserving the cortical bone^{11,15-17}.

The differential diagnosis with the osteoid osteoma is sometimes very difficult, clinically an radiologically. While the osteoblastoma is situated at the medulla, the osteoid osteoma is in most

instances located at the bony cortex¹³ and usually has a sclerotic nidus¹⁸. This latter has also a smaller size at the presentation¹⁹, probably because it causes pain as the first symptom. In the osteoblastoma, probably because of its bony medullar location, pain is usually observed when there is a large mass. Other differential diagnoses should include osteogenic sarcoma, condrosarcoma, benign giant cell tumor and fibrosarcoma.

The clinical and radiological presentation of our patient was typical of osteoblastoma: a 23 years old male with a 3 years history of temporal mass associated to pain and tenderness. The unusual tumor size, 9 cm in the largest diameter, is much larger than the average size reported in the literature (3.1 cm). CT appearance of a well circumscribed osteolytic, multiloculated, expansive lesion with radiopaque granular mottling and peripheral esclerosis of an intact cortex and contrast enhancement is very suggestive of this diagnosis (Fig 1). The mass effect against the temporal lobe with lateral displacement of ventricles is seldom seen in those bone tumors (Fig 2).

Total removal is the aim of the treatment. This can be very difficult, specially in large tumors, because of the tendency to bleed at the surgery. Tom et al.²⁰ reported a 1350 ml blood loss during biopsy of a maxillary osteoblastoma. At our knowledge, this is the first case of skull osteoblastoma reported in the literature to be submitted to preoperative embolization. As the tumor is most often supplied by branches of the external carotid artery, we strongly recommend this procedure in most of the cases, as this was a very important point for the succesfully total removal of this giant tumor.

REFERENCES

1. Martin-Ferrer S. Benign osteoblastoma of parietal bone: case report. *Neurosurgery* 1989;25:109-112.
2. Jaffe HL, Mayer LF. Osteoblastic osteoid tissue-forming tumor of metacarpal bone. *Arch Surg* 1932;24:550-564.
3. Jaffe HL. Benign osteoblastoma. *Bull Hosp Jt Dis* 1956;17:141-151.
4. Lichtenstein L. Benign osteoblastoma: a category of osteoid and bone-forming tumors other than classical osteoma osteoid which may be mistaken for giant-cell tumor or osteogenic sarcoma. *Cancer* 1952;9:1044-1052.
5. Dahlin DC, Johnson EW. Giant osteoid osteoma. *J Bone Joint Surg* 1952;36:559-572.
6. Voorhies RM, Sunderesan N. Tumors of the skull. In Wilkins RH, Reganchari SS (eds). *Neurosurgery*. New York: McGraw-Hill, 1985: 984- 1001.
7. Williams RN, Boop WC Jr. Benign osteoblastoma of the skull: case report. *J Neurosurg* 1974;41:769-772.
8. Braendli AF, Bulfamante GP. Unusual osteoblastoma of the skull. *Helv Paediat Acta* 1986;41:505-508.
9. Cabezudo JM. Recurrent benign osteoblastoma of temporal bone. *Neurosurgery* 1989;25:1012-1013.
10. Berciano J, Perez-Lopez JL, Fernandez F, Val F, Leno C. Voluminous benign osteoblastoma of the skull. *Surg Neurol* 1986;20:383-386.
11. Lucas DR, Unni KK, McLeod RA, O'Connor MI, Sim FH. Osteoblastoma: clinicopathological study of 306 cases. *Hum Pathol* 1994;25:117-134.
12. Lorenzo ND, Palatinsky E, Bardella L, Maleci A. Benign osteoblastoma of the clivus removed by a transoral approach: case report. *Neurosurgery* 1994;20:52-55.
13. Kashaba A, DeDonato G, Vassalo G, et al. Benign osteoblastoma of the mastoidal part of temporal bone: case report. *J Otoralyngol-Otol* 1995;109:565-568.
14. Messina AV, Abbot GF, Gray G, Paterson RH. Primary intracerebral osteoblastoma: case report. *J Neurosurg* 1977;47:469-471.
15. Ciappeta P, Salvati M, Raco A, Artico M, Gagliard FM. Benign osteoblastoma of the sphenoid bone. *Neurochirurgia* 1991;34:97-100.
16. Gellad FE, Hafiz MA, Blanchard CL. Osteoblastoma of temporal bone: CT findings. *J Comput Assist Tomogr* 1985;9:577-579.
17. Pochaczewsky R, Yen YM, Sherman RS. The roentgen appearance of benign osteoblastoma. *Radiology* 1960;75:429-437.
18. Snow RD, Christianson MD, Dowling EA, Brogdon BG. Case report 874. *Skeletal Radiol* 1994;23:656-659.
19. Adler M, Hnatuk L, Mock D, Freeman JL. Agressive osteoblastoma of temporal bone: case report. *J Otoralyngol* 1990;19:307-310.
20. Tom LWC, Lowry LD, Quinn-Bogard A. Benign osteoblastoma of the ethmoid sinus. *Otolaryngol Head Neck Surg* 1980;88:397- 402.