

PROBABLE CAUSAL LINK BETWEEN EPILEPSY AND SLEEP APNEA

Case report

Michele Dominici^{1,2}, Fernando Pompeu Filho¹, Marleide da Mota Gomes²

ABSTRACT - Patients with epilepsy were reported to have concomitant sleep apnea, but it has been rarely linked to the epilepsy itself. We present a case of a 28-year-old, obese man with secondary medically resistant partial complex epilepsy due to a brain trauma, with progressive snoring, and sleep agitation, apneas, and important daytime somnolence. It was noticed in the polysomnographic study that he had several sleep respiratory events, probably due both to the epileptic seizures and the sleep apnea syndrome as a co-morbidity. Apnea and epilepsy will be discussed. A careful video-EEG-polysomnography study is important in evaluating refractory epileptic patients and/or epileptic patients with snoring.

KEY WORDS: snoring, obstructive sleep apnea, epilepsy.

Provável associação entre epilepsia e apnéia do sono: relato de caso

RESUMO - Pacientes com epilepsia e concomitante apnéia do sono já foram descritos na literatura, mas raramente foram associados à epilepsia como fator causal desta apnéia. Nós apresentamos o caso de um homem com 28 anos, obeso, com epilepsia parcial complexa farmacorresistente secundária a trauma crânio encefálico e roncos progressivos, sono agitado, apnéias, além de importante sonolência diurna. Foram observados, durante estudo polissonográfico, freqüentes eventos respiratórios durante o sono, provavelmente secundários a crise epilética, além da síndrome de apnéia obstrutiva do sono como uma co-morbidade. Um exame cuidadoso de vídeo-EEG-polissonografia do caso é importante na avaliação de pacientes com epilepsia fármaco resistente e/ou epiléticos com roncos.

PALAVRAS-CHAVE: ronco, apnéia obstrutiva do sono, epilepsia.

It is suggested that a third or more of epilepsy patients have obstructive sleep apnea, and it may be even more prevalent in medically resistant epilepsy patients¹. Sleep apnea does disrupt sleep and causes excessive daytime sleepiness, an inability to concentrate and headaches. If, however, the person has epilepsy, then the sleep disruption can bring on seizures. It has been shown by Devinsky et al.² and other authors that treating sleep apnea will also help to lessen the frequency of epileptic seizures. Sleep breathing disorders fragment sleep causing daytime sleepiness, migraine, attention deficits and in epileptic patients apnea may facilitate the occurrence of seizures. Patients with epilepsy and concomitant obstructive sleep apnea have been described in the literature, but epilepsy has rarely been associated "per se" to the sleep breathing apnea. The syndrome of

sudden death of unidentified cause (SUDEP) is an important cause of death among patients with epilepsy (7-17%), particularly in the group of patients with refractory epilepsy (50%). Studies in this group of patients are growing, but according to Kanner³ they have not entirely addressed the risks of death in the daily clinic patients. Studies trying to correlate SUDEP with the autonomous abnormalities in cardiac and respiratory function observed during seizures were performed⁴, however the results are not entirely established yet. The coexistence of epilepsy and apnea suggests a link between structures of the brain that are responsible for epilepsy and those which control breath like the insula, amygdala, cingulate gyrus, and orbitofrontal cortex⁵.

We report a epileptic patient whose polysomnographic monitoring study suggests that his intermit-

¹Clínica Neurológica Professor Fernando Pompeu, Rio de Janeiro, Brazil; ²Programa de Epilepsia do Instituto de Neurologia Deolindo Couto e Programa de Pós-Graduação de Psiquiatria e Saúde Mental, Universidade Federal do Rio de Janeiro, Brasil (UFRJ).

Received 21 June 2006, received in final form 9 October 2006. Accepted 17 November 2006.

Dra. Michele Dominici - Avenida Prado Jr 307 / 604 - 22011-040 Rio de Janeiro RJ - Brasil. E-mail: micheledominici@gmail.com

tent apneas were related to both the epilepsy and the obstructive apnea syndrome.

CASE

A 28-year-old obese male was referred to a polysomnographic center for his seizures evaluation. The seizures were medically resistant and secondary to a brain trauma that occurred after a vehicle accident. He also had non positional snoring, arousal, apneas and daytime sleepiness. His current medications were valproate, carbamazepine, phenobarbital and clonazepam. The patient complained of progressive daytime somnolence. His Epworth Sleepiness Scale (ESS) was 15 and his weight was 100 kg (BMI=39).

Whole night video-EEG-polysomnography study was performed as part of his epilepsy investigation. It was registered results of a 18 channels EEG, electro-oculogram, electromyogram, electrocardiogram, nasal/oral airflow and

abdominal/thoracic respiratory movements. Sleep stages were visually scored following standard criteria. A magnetic resonance image (MRI) demonstrated areas of encephalomalacia in cortical and sub-cortical frontal lobes. The neurologic examination showed only cognitive decline. The video-EEG-polysomnography revealed: inter-ictal multifocal spikes (frontal left and right independent and mid temporal left and right); ictal EEG seizure pattern alternatively beginning in both hemispheres and sometimes spreading to the contra-lateral side (Figs 1, 2, 3). It was registered several auto motor seizures, frequently (58) associated with autonomic changes (central apneas, bradycardia) and obstructive sleep apneas and hypopneas (Figs 4, 5, 6). In the whole exam, there were detected 21 obstructive sleep apneas, 29 central apneas and 126 hypopneas with an apnea and hypopnea index (AHI) of 28/h and 226 dessaturations.

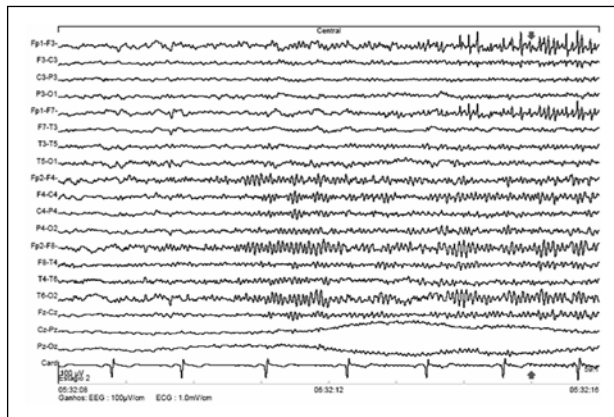


Fig 1. Epoch with 8 s of EEG. The ictal EEG seizure pattern begin in the right hemisphere and spread to the contra-lateral side, with related EEG runs of polyspike in the left anterior areas related to the central sleep apnea (Fig 4).

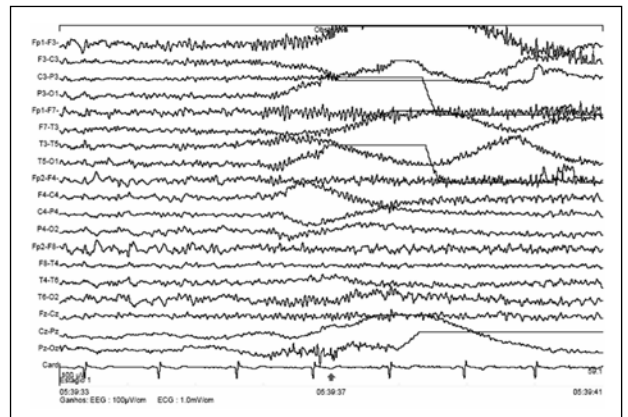


Fig 2. Epoch with 8 s of EEG. The ictal EEG seizure pattern is in the left hemisphere. Related EEG showing runs of polyspike in the left fronto-polar area compatible with the patient brain injury related to the obstructive sleep apnea (Fig 5).

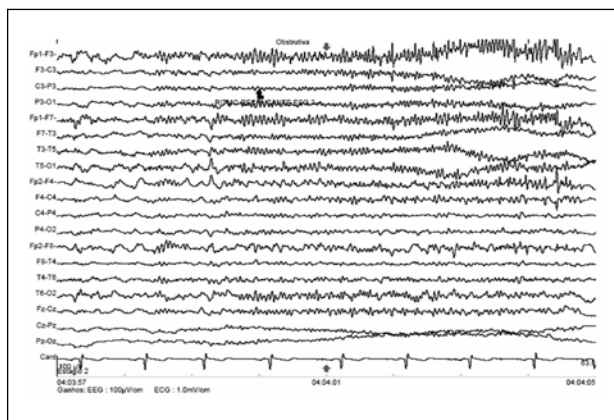


Fig 3. Epoch with 8 s of EEG. The ictal EEG seizure pattern is dominant in the left hemisphere. Related EEG showing runs of polyspike in the left fronto-polar area compatible with the patient brain injury related to the obstructive sleep apnea (Fig 6).

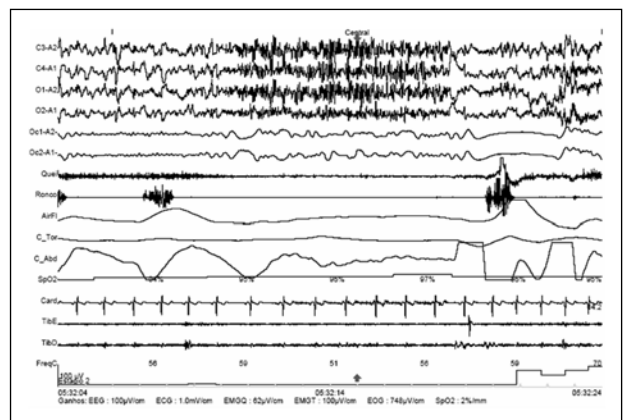


Fig 4. Epoch with 20 s of standard PSG, showing a central sleep apnea, associated with a seizure rhythm pattern in the EEG ending in a auto-motor seizure recorded by the video-registration. Probable central apnea (polysomnographic view) seizure related.

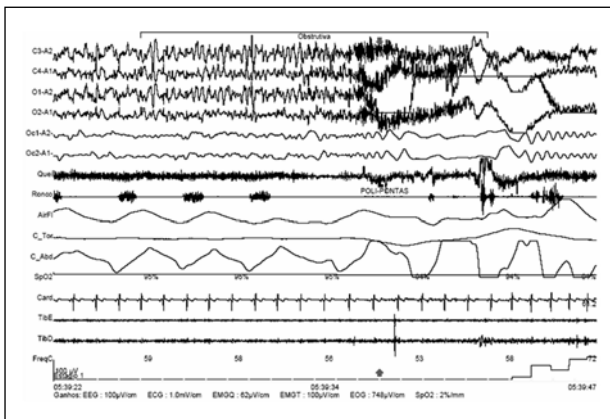


Fig 5. Epoch with 25 s of standard PSG, showing an obstructive sleep apnea associated with an ictal seizures EEG pattern ending with an automotor crises registered in the videomonitorization. Probable obstructive critical apnea (polysomnographic view).

DISCUSSION

Cases with multiple risk factors such as brain lesions, exposure to several drugs with respiratory and central nervous system suppressant effects and obesity render it difficult to the physician to realize what is cause and effect. Obstructive sleep apnea has been reported in people with epilepsy. Nevertheless, there have been only a limited number of reports of sleep apneas due to epileptic seizures. Thus, we speculate that this condition may be neglected in most instances. Our case presented both types of apnea: central and obstructive, either primary or secondary to seizures. Clinicians should investigate apnea in epileptic patients when indicated. Polysomnography can help to identify seizure's related apnea and also permits the clinician to provide the best medical care. In our opinion, this study should be performed in all medically resistant epilepsy patient suspected to have apnea or unexplained daytime somnolence. Better understanding the role of these two related events (apnea and epilepsy) in the spectrum of the sudden unidentified death epileptic syndrome (SUDEP), may help to clarify the etiopathogenesis of this syndrome.

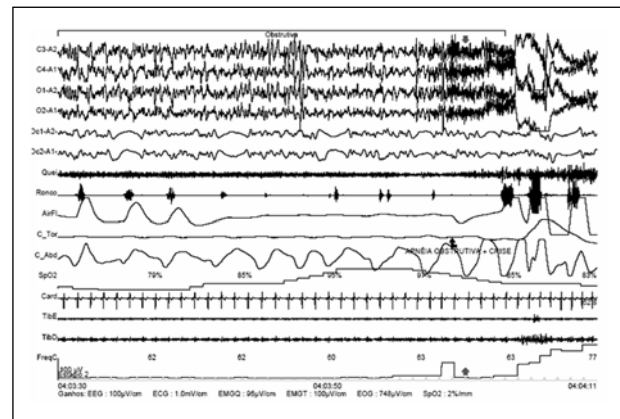


Fig 6. Epoch with 40 s of standard PSG, showing an obstructive sleep apnea ending with an ictal EEG seizure pattern and in the video registration we can see an automotor crises. Possible obstructive critical apnea (polysomnographic view).

In conclusion, we presented a case of a patient with refractory epilepsy, which video-EEG-polysomnography demonstrated a significant amount (33%) of respiratory events associated to seizures. We believe that these apneic related events may help to unravel the etiopathogenesis of SUDEP and to better understand the daytime symptoms of epileptic patients. This case shows also the importance of using more frequently a Video- EEG-PSG study in a subset of refractory epilepsy patients with or without snoring.

Acknowledgments – We acknowledge the thoroughly paper English revision made by Ms Livia Sanches Dominici.

REFERENCES

1. Malow BA, Levy K, Maturen K, Bowes R. Obstructive sleep apnea is common in medically refractory epilepsy patients. *Neurology* 2000;55:1002-1007.
2. Devinsky O, Ehrenberg B, Barthlen GM, Abramson HS, Luciano D. Epilepsy and sleep apnea syndrome. *Neurology* 1994;44:2060-2064.
3. Kanner AM. Unrevealing the secrets of sudden death in epilepsy: is it possible? *Epilepsy Curr* 2004;4:225-226.
4. O'Regan ME, Brown JK. Abnormalities in cardiac and respiratory function observed during seizures in childhood. *Dev Med Child Neurol* 2005;47:4-9.
5. Devinsky O. Effects of seizures on autonomic and cardiovascular function. *Epilepsy Curr* 2004;4:43-46.