

# NORMAL HEARING AFTER RESECTION OF A LARGE VESTIBULAR SCHWANNOMA

Bruno Perocco Braga<sup>1</sup>, Guilherme Cabral-Filho<sup>2</sup>, Marcelo Duarte Vilela<sup>3</sup>

Advances in anesthesia and surgical techniques have brought the surgical mortality rate for vestibular schwannomas (VS) to less than 1%<sup>1-3</sup>. Increased preservation rates of facial and cochlear function were observed in the most recent large series by Samii et al.<sup>1</sup>. Nevertheless, preservation of House-Brackmann grade I and Hannover Class H1 (PTA <20dB and SDS >95%) hearing function postoperatively after total removal of large tumors is still a challenge, even in experienced hands<sup>1,2,4-6</sup>.

Our objective is to add to the literature a case of a large VS that was totally excised, with preservation of normal facial and hearing functions. Details on the surgical technique are presented.

## CASE

### Case description

A 30-year-old female presented with a 2-month history of trigeminal neuralgia in the right V3 distribution, along with normal hearing, an unusual symptomatology for a large VS. Neurological examination was normal. Imaging studies showed a large (34 × 33 × 28 mm), enhancing, spherical mass in the right cerebellopontine angle with erosion of the porus acusticus but no dural tail. A vestibular schwannoma, extension Class T4b (IV ventricle was compressed and distorted), was diagnosed (Fig 1). Her audiometry showed Class H1 hearing in the right ear.

### Surgical technique

A three-quarter prone position was used, with the nose pointing up 10 degrees and vertex tilted 15 degrees down, relative to the operating room floor. A lumbar drain was used to drain 50 cc mL CSF throughout the opening. A standard suboccipital retrosigmoid approach was used and the cerebellum was gently retracted after opening the Cisterna Magna. The bed was totally rotated away so the surgeon could have a tangential view of the internal auditory canal (IAC). The configuration of the lesion allowed drilling the posterior lip of the porus, which was followed by internal debulking of the tumor using

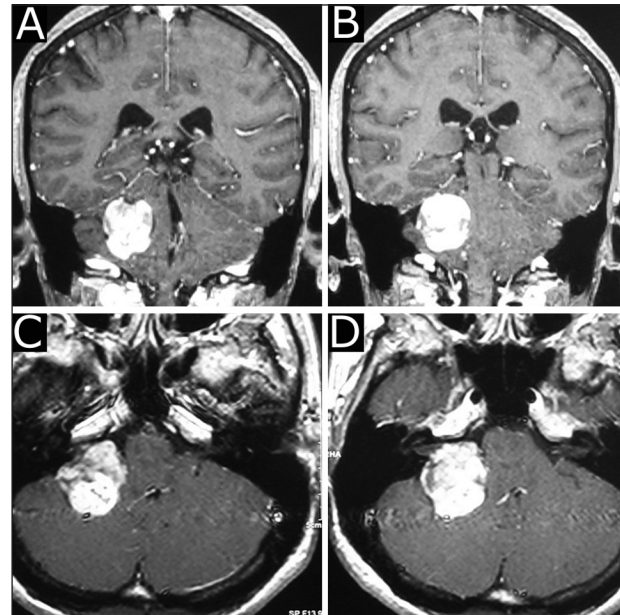


Fig 1. (A–D) Preoperative MR coronal and axial T1-weighted images with Gadolinium demonstrate a globular, uniformly enhancing lesion in the cerebellopontine angle, distorting the brainstem and fourth ventricle. Small extension into the porus acusticus is seen.

microinstruments. The intrameatal portion of the facial nerve was then identified at the fundus with the aid of a monopolar stimulator. We used facial nerve monitoring throughout but no cochlear nerve monitoring was done. Although we did not expect preservation of hearing, all attempts were made to preserve the cochlear nerve intact. The cochlear and facial nerves were preserved anatomically with a glistening layer of arachnoid overlying their posterior surface, to avoid any stretching on them. Facial nerve function was confirmed at the end of the case by stimulation at the brainstem using a 0.1 mA current. Total removal was confirmed after inspection of the tumor bed. Hemostasis was carefully done. The meatus was covered with a free muscle graft and biological glue. A cranioplasty was performed using polymethylmethacrylate after a watertight dural

## AUDIÇÃO NORMAL APÓS RESSECÇÃO DE UM GRANDE SCHWANNOMA DO VESTIBULAR

<sup>1</sup>Staff Neurosurgeon, Hospital Mater Dei, Belo Horizonte MG, Brazil; <sup>2</sup>Chief of Neurosurgery, Hospital Mater Dei, Belo Horizonte MG, Brazil; <sup>3</sup>Assistant Professor, Department of Neurological Surgery, Harborview Medical Center, University of Washington, Seattle, WA, USA.

Received 4 July 2008, received in final form 15 September 2008. Accepted 1 October 2008.

Dr. Marcelo D. Vilela – Department of Neurological Surgery / Harborview Medical Center - 325 9<sup>th</sup> Avenue - Seattle WA - 98104 - USA - Box 359766. E-mail: mdvilela@u.washington.edu

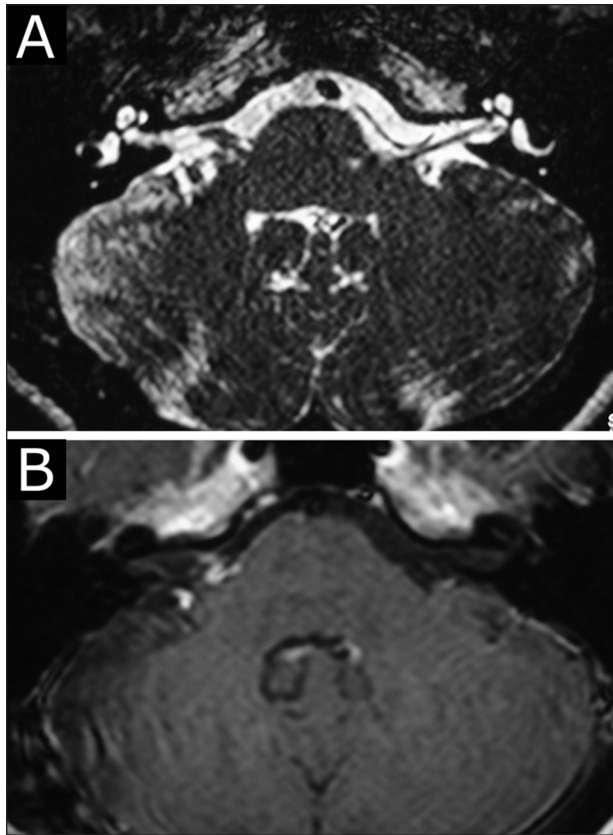

Fig 2. (A–B) Postoperative MR axial T2 and T1 Gad-weighted images demonstrating no recurrence two years after surgery.

closure. The time spent on the tumor dissection was approximately four hours.

The neurological examination showed House-Brackmann grade I function in the immediate postoperative period. On the following morning, vomiting and somnolence was seen. A head CT demonstrated a hematoma in the right cerebellopontine angle, thought to have happened due to an elevation of the blood pressure during the postoperative period. Prompt clot evacuation plus placement of a ventriculostomy was performed. The patient had a full recovery without any other complications and was discharged home seven days later. At the four week follow-up visit, the neurological examination was normal, with House-Brackmann grade I function and good hearing. Postoperative MRI more than two years later showed no recurrence (Fig 2). Audiogram documented a Hannover Class H1 (PTA<20dB and SDS >95%) hearing on both sides (Fig 3).

**DISCUSSION**

Total resection with preservation of cranial nerve function is the ideal outcome when dealing with vestibular schwannomas. However, large tumors (>3 cm) pose treatment difficulties with reported cranial nerve preservation rates well below the rates seen for small or medium tumors<sup>1, 5-8</sup>.

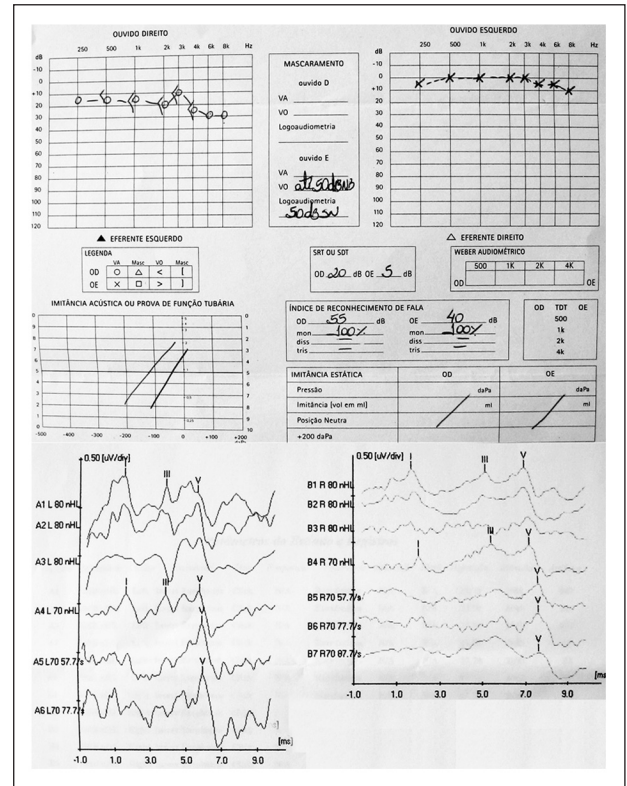


Fig 3. Postoperative audiogram demonstrating a SRT<of 20 dB on the right and 5 dB on the left, with a speech discrimination of 100% in both ears. Slight delay in wave V latency on the right compared to left ear.

**Facial nerve function** – Preservation of House-Brackmann grade I function in large tumors is still a challenge, even with the aid of intraoperative monitoring. Gormley reported a 38% preservation rate (grade I–II) for tumors larger than 4 cm<sup>7</sup>. Ojemann reported a 57% preservation rate (grades I–II) in his series of 161 large tumors<sup>9</sup>. Sammi, in a recent large series of 200 patients, had 18% and 35% House-Brackmann Grade I preservation rates for patients with T4b tumors (compressing the IV ventricle) and T4a tumors (compressing the brainstem), respectively<sup>1</sup>. This is in contrast with 67% and 75% for T2 (intra and extrameatal tumor not filling the CP cistern) and T1 (intrameatal) tumors, respectively<sup>1</sup>.

**Hearing function** – Attempting hearing preservation is a matter of controversy when dealing with large tumors. Yates et al. questioned whether hearing preservation should be attempted at all in large tumors, since in his series of 23 patients with large tumors that had a preoperative hearing grade A or B, none had serviceable hearing after surgery<sup>5</sup>. Raftopoulos et al. operated on 16 patients with tumors larger than 3 cm with the attempt of preservation of cranial nerve function. Two patients had a Gardner-Robertson Grade 1 preoperatively, and both downgraded to grade 2 postoperatively, with one of them

having had only a partial resection and subsequent radiotherapy for tumor control<sup>4</sup>. Mohr et al. reported that in 27 patients with tumors larger than 2.1 cm only one had serviceable hearing postoperatively<sup>8</sup>.

Post et al., out of a series of 56 patients in which hearing was present preoperatively had seven patients with large tumors, but none had a Hannover Class H1 hearing postoperatively<sup>3</sup>. Samii, in a series of 1000 patients, had 28 patients with large tumors and preoperative class H1 hearing, with only one patient having Class H1 hearing postoperatively<sup>6</sup>. Fischer et al. preserved Hannover Class H1 hearing function in one patient harboring a tumor larger than 3 cm<sup>10</sup>. Fahlbusch et al., after operating on 14 patients with a tumor  $\geq 3$  cm who had good preoperative hearing, were able to preserve Hannover Class I hearing function in two patients<sup>2</sup>.

It is still unclear which factors are most important to predict preservation of hearing postoperatively. It is well documented that there can be normal hearing with large tumors and deafness with very small intrameatal lesions<sup>6</sup>. Elevation of pressure in the internal auditory canal has been demonstrated to occur in tumors with intracanalicular extension, and pressure on the cochlear nerve and on the vascular structures can make the nerve vulnerable during drilling and dissection<sup>8</sup>. Most often, despite anatomic cochlear nerve preservation, there is no function postoperatively<sup>1</sup>.

Accepted prognostic factors for hearing preservation seem to be tumor size and extension, pre-operative hearing and the degree of involvement of the IAC<sup>1,3,8</sup>. If the tumor extends deeply to the fundus, it is difficult to expose the lesion without entering the labyrinth, and the extent of labyrinth opening influences hearing preservation<sup>11</sup>. Samii has reported the usefulness of the endoscope to dissect tumor out of the fundus and avoid overdrilling into the labyrinth<sup>1</sup>. Male sex, short duration of hypoacusis and vestibular disturbances were also found to be predictive factors for postoperative cochlear function<sup>6</sup>, as well as extension of the tumor inferiorly with stretching of the eighth nerve<sup>6</sup>. Ciric et al. noted the presence of at least waves I and V on pre-operative BAEP, tumor growth away from the cochlear nerve and blood supply to the cochlear nerve from the inferior or ventral side to be prognostic determinants for preserved hearing after surgery<sup>12</sup>. Interestingly, in Post et al. series, tumor consistency did not seem to affect hearing preservation<sup>3</sup>. Yates et al. cite deep involvement of the fundus, marginal hearing and wide erosion of the porus as poor prognostic factors weighing against hearing preservation surgery<sup>5</sup>.

In our case, retrospectively, we can cite little erosion of the porus and no extension into the fundus as favor-

able factors for hearing preservation. Additionally, we were able to preserve a nice layer of arachnoid overlying the nerves, which prevented any form of traction on the nerves during the dissection. A Grade I House-Brackmann function and a Hannover Class H1 hearing function were seen after surgery and maintained during follow-up, with no evidence of tumor recurrence at 2 years.

This case demonstrates that preservation of normal cochlear nerve function can be seen after complete excision of large vestibular schwannomas. This outcome is likely due to the combination of multiple factors cited before, such as minimal extension into the fundus, minimal erosion of the porus, excellent preoperative hearing and a meticulous surgical technique.

In conclusion, microsurgery is a safe and effective option in the treatment of vestibular schwannomas. It is our opinion that careful dissection with preservation of the arachnoidal membrane is critical in order to preserve the integrity of the cranial nerves, and at the same time avoids any form of traction injury. Preservation of Hannover Class I hearing in large tumors can be achieved and should be attempted when favorable circumstances are seen preoperatively.

**ACKNOWLEDGEMENTS** – We thank Dr. Robert Goodkin for reviewing this manuscript.

## REFERENCES

1. Samii M, Gerganov V, Samii A. Improved preservation of hearing and facial nerve function in vestibular schwannoma surgery via the retrosigmoid approach in a series of 200 patients. *J Neurosurg* 2006;105:527-535.
2. Fahlbusch R, Neu M, Strauss C. Preservation of hearing in large acoustic neurinomas following removal via suboccipito-lateral approach. *Acta Neurochirurg* 1998;140:771-777.
3. Post KD, Eisenberg MB, Catalano PJ. Hearing preservation in vestibular schwannoma surgery: what factors influence outcome? *J Neurosurg* 1995;83:191-196.
4. Raftopoulos C, Serieh A, Duprez T, Docquier MA, Guerit JM. Microsurgical results with large vestibular schwannomas with preservation of facial and cochlear nerve function as the primary aim. *Acta Neurochirurg* 2005;147:697-706.
5. Yates PD, Jackler RK, Satar B, Pitts LH, Oghalai JS. Is it worthwhile to attempt hearing preservation in larger acoustic neuromas? *Otol Neurotol* 2003;24:460-464.
6. Samii M, Matthies C. Management of 1000 vestibular schwannomas (acoustic neuromas): hearing function in 1000 tumor resections. *Neurosurg* 1997;40:248-262.
7. Gormley WB, Sekhar LN, Wright DC, Kamerer D, Schessel D. Acoustic neuromas: results of current surgical management. *Neurosurg* 1997;41:50-60.
8. Mohr G, Sade B, Dufour J, Rappaport JM. Preservation of hearing in patients undergoing microsurgery for vestibular schwannoma: degree of meatal filling. *J Neurosurg* 2005;102:1-5.
9. Ojemann RG. Management of acoustic neuromas (vestibular schwannomas) (honored guest presentation). *Clin Neurosurg* 1993;40:498-535.
10. Fischer G, Fischer C, Remond J. Hearing preservation in acoustic neuroma surgery. *J Neurosurg* 1992;76:910-917.
11. Tatagiba M, Samii M, Matthies C, el Azm M, Schonmayr R. The significance for postoperative hearing of preserving the labyrinth in acoustic neurinoma surgery. *J Neurosurg* 1992;77:677-684.
12. Ciric I, Zhao JC, Rosenblatt S, Wiet R, O'Shaughnessy B. Suboccipital retrosigmoid approach for removal of vestibular schwannomas: facial nerve function and hearing preservation. *Neurosurgery* 2005;56:560-570.