

to 100 mg daily. After 13 days of treatment, she developed continuous visual illusions upon waking in the morning; when looking at human faces, they were distorted and swollen. On many occasions, objects in front of her appeared to be either nearer or farther away. These visual phenomena persisted for approximately 12 hours and gradually disappeared with the discontinuation of topiramate. Thereafter, she never had similar experiences. None of these events was accompanied by the loss of consciousness or headache. The patient's impressions of reality and self-recognition were preserved. The neurological and psychiatric examination was normal, and a complete examination by a neuro-ophthalmologist was normal. An EEG,

with activation procedures (hyperventilation and photic stimulation), and the MRI of the brain were normal.

Metamorphopsia is a visual illusion affecting the perception of the size, shape or inclination of objects<sup>1</sup>. Although this condition occurs in migraine aura, topiramate has been reported to induce other visual illusions, such as palinopsia (the illusion of a persistent or recurrent visual images following the removal of the exciting stimulus)<sup>2</sup> and alterations in body perception ("Alice in Wonderland syndrome") in patients with migraines<sup>3</sup>.

The mechanism by which topiramate may cause these visual illusions in migraineurs is unknown. However, because it may occur in the aura of migraines, these visual illusions are likely to be a result of the migraine.

## References

1. River Y, Ben Hur T, Steiner I. Reversal of vision metamorphopsia: clinical and anatomical characteristics. *Arch Neurol* 1998;55:1362-1368.
2. Evans RW. Reversible palinopsia and the Alice in Wonderland syndrome associated with topiramate use in migraineurs. *Headache* 2006;46:815-818.
3. Jürgens TP, Ihle K, Stork JH, May A. "Alice in Wonderland syndrome" associated with topiramate for migraine prevention. *J Neurol Neurosurg Psychiatry* 2011;82:228-229. doi:10.1136/jnnp.2009.187245

# Behavioral changes on amyotrophic lateral sclerosis (ALS): a case of ALS/FTD TDP-43 proteinopathy

Deterioração comportamental na esclerose lateral amiotrófica (ELA): um caso de proteinopatia TDP-43 associada à ELA e demência frontotemporal

*Bruno Lopes dos Santos<sup>1</sup>, Guilherme Riccioppo Rodrigues<sup>1</sup>, Vitor Tumas<sup>1</sup>, José Eymard Homem Pittella<sup>2</sup>*

<sup>1</sup>Movement Disorders and Cognitive Neurology Unit, Department of Neuroscience and Behavior Sciences, Medical School of Ribeirão Preto, University of São Paulo (USP), Ribeirão Preto SP, Brazil;

<sup>2</sup>Department of Pathology, Medical School of Ribeirão Preto, USP, Ribeirão Preto SP, Brazil.

**Correspondence:** Bruno Lopes dos Santos; Setor de Distúrbios do Movimento e Neurologia Cognitiva, Departamento de Neurociências e Ciências Comportamentais, Faculdade de Medicina de Ribeirão Preto, USP; Av. Bandeirantes 3900; 14049-900 Ribeirão Preto SP - Brasil; E-mail: bruls4@usp.br

**Conflict of interest:** There is no conflict of interest to declare.

Received 26 June 2011; Received in final form 28 September 2011; Accepted 05 October 2011

The frontotemporal dementia (FTD) is the second most common form of dementia in patients younger than 65 years, and its behavioral variant (bvFTD) is the most prevalent form<sup>1,2</sup>. During the last years, the overlapping between FTD and amyotrophic lateral sclerosis (ALS) has been frequently recognized, with symptoms of FTD preceding ALS and vice-versa. Herein, we report a case of ALS, which afterwards presented psychotic and behavioral symptoms, whose neuropathological diagnosis was compatible with bvFTD-ALS with TAR DNA-binding protein 43 (TDP-43) inclusion<sup>3</sup>.

## CASE REPORT

A 58-year-old man was admitted in our Emergency Unit with a one-year history of progressive weakness of limbs, associated with dysarthria, dysphonia, difficulty to close mouth and hands atrophy. Four days before admission, he developed dyspnea and acute respiratory failure. In the hospital, it was seen generalized weakness, global hyperreflexia, fasciculations on right arm, no sensory abnormalities, and the electroneuromyography showed chronic and acute denervation signs in cranial, cervical

and lumbosacral segments, confirming the diagnosis of amyotrophic lateral sclerosis. As the patient had no social and economic home support, he lived the rest of his life hospitalized, with mechanic ventilation. In the first year after admission, the patient showed anxious and depressive symptoms, associated with a permanent refusal of his condition, with great hopes of cure, even after exhaustive explanation about the diagnosis. This behavior was considered as mechanism of denial.

Progressively, the patient became hostile to nurses and physicians, blaming his disease to clinical staff, with frequent verbal aggression. He said that the family was visiting him, but there were no proof of these visits. After 2 years of hospitalization, the aggressivity worsened, without improvement with antidepressants drugs. The patient affirmed that the disease could be resolved with antibiotic, but the physicians did not want to treat him. In his last months, the persecutory delusions became more intense, associated with visual hallucinations. As there were no clinical signs of delirium, a psychotic delusional disorder was diagnosed and neuroleptic medications were started. His psychiatric status progressively worsened, with auditory hallucinations and physical aggression to the clinical staff. After 2 years and 9 months of hospitalization, the patient died by asphyxia by tracheal blood clot.

On necropsy (Fig), it was seen moderate reduction in hypoglossus nucleus and in anterior column of spinal cord

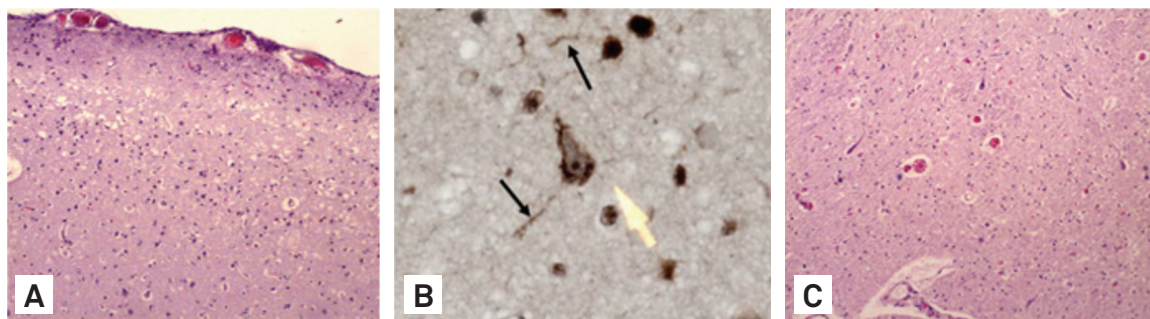
motor neurons, and myelin pallor on anterior and lateral funiculi, sparing posterior funiculus (Fig C), and the brain showed spongiosis in layer II, predominantly in temporal cortex (Fig A and B). The immunoreactivity to protein tau was negative, but there were granular neuronal intracytoplasmic inclusions and dystrophic neurites positive to ubiquitin and TDP-43 (subtype 3 from Mackenzie et al.)<sup>4</sup>.

## DISCUSSION

The discovery of TDP-43<sup>3-5</sup> in brains of patients with the association FTD-ALS has improved the comprehension of its pathophysiology. This specific phenotype often shows the presence of delusions and hallucinations<sup>1</sup>, as seen in our case, and these symptoms should draw our attention to the possibility of TDP-43 proteinopathy on motor neuron disease. As the patient was hospitalized during almost 3 years, it was possible to register details of his behavioral degeneration.

## ACKNOWLEDGMENTS

We thank Dr. Lea Tenenholz Grinberg, MD, PhD, UCSF Memory and Aging Center, USA, for immunohistochemical reaction to TDP-43.



**Fig.** (A) Temporal cortex. Microvacuolization of layer II. Hematoxylin and Eosin, X100. (B) Frontal cortex. Neuronal intracytoplasmic inclusions (yellow arrows) and in dystrophic neurites (black arrows). Immunohistochemistry for TDP-43, X400. (C) Anterior horn of the spinal cord. Marked loss of motor neurons. Hematoxylin and Eosin, X100.

## References

- Lillo P, Garcin B, Hornberger M, Bak TH, Hodges JR. Neurobehavioral features in frontotemporal dementia with amyotrophic lateral sclerosis. *Arch Neurol* 2010;67:826-830.
- Piguat O, Hornberger M, Mioshi E, Hodges JR. Behavioural-variant frontotemporal dementia: diagnosis, clinical staging, and management. *Lancet Neurol* 2011;10:162-172.
- Neumann M, Sampathu DM, Kwong LK, et al. Ubiquitinated TDP-43 in frontotemporal lobar degeneration and amyotrophic lateral sclerosis. *Science* 2006;314:130-133.
- Mackenzie IR, Rademakers R, Neumann M. TDP-43 and FUS in amyotrophic lateral sclerosis and frontotemporal dementia. *Lancet Neurol* 2010;9:995-1007.
- Geser F, Lee VMY, Trojanowski JQ. Amyotrophic lateral sclerosis and frontotemporal lobar degeneration: a spectrum of TDP-43 proteinopathies. *Neuropathology* 2010;30:103-112.