

Pseudoxanthoma elasticum presenting as akinetic-rigid parkinsonism and dementia

Pseudoxantoma elástico se apresentando como parkinsonismo acinético-rígido e demência

Paulo Victor Sgobbi de SOUZA¹, Igor Braga FARIAS¹, Bruno de Mattos Lombardi BADIA¹, Luiz Henrique Libardi SILVA¹, Daniel Delgado SENEOR¹, Vitor Dias Gomes Barrios MARIN¹, Carlos Alberto Castro TEIXEIRA JÚNIOR¹, Marco Antônio Troccoli CHIEIA¹, Wladimir Bocca Vieira de Rezende PINTO¹, Acary Souza Bulle OLIVEIRA¹

A 54-year-old man presented with a three-year history of progressive cognitive decline, abulia, apathy, slowing movements and global rigidity. Medical history, confirmed by skin biopsy, revealed a definite diagnosis of pseudoxanthoma elasticum. Examination disclosed angioid streaks at fundoscopic evaluation, skin lesions (Figure 1), bradykinesia and marked symmetrical akinetic-rigid parkinsonism with cogwheel rigidity. Neuroimaging studies showed

multiple lacunar infarcts in the basal ganglia and brainstem. Tc-99m SPECT imaging showed bilateral frontal hypoperfusion (Figure 2).

Pseudoxanthoma elasticum is a rare autosomal recessive ectopic mineralization disorder^{1,2}, which can present a complex neurological picture due to severe vascular compromise, rarely with movement disorders^{1,2}.

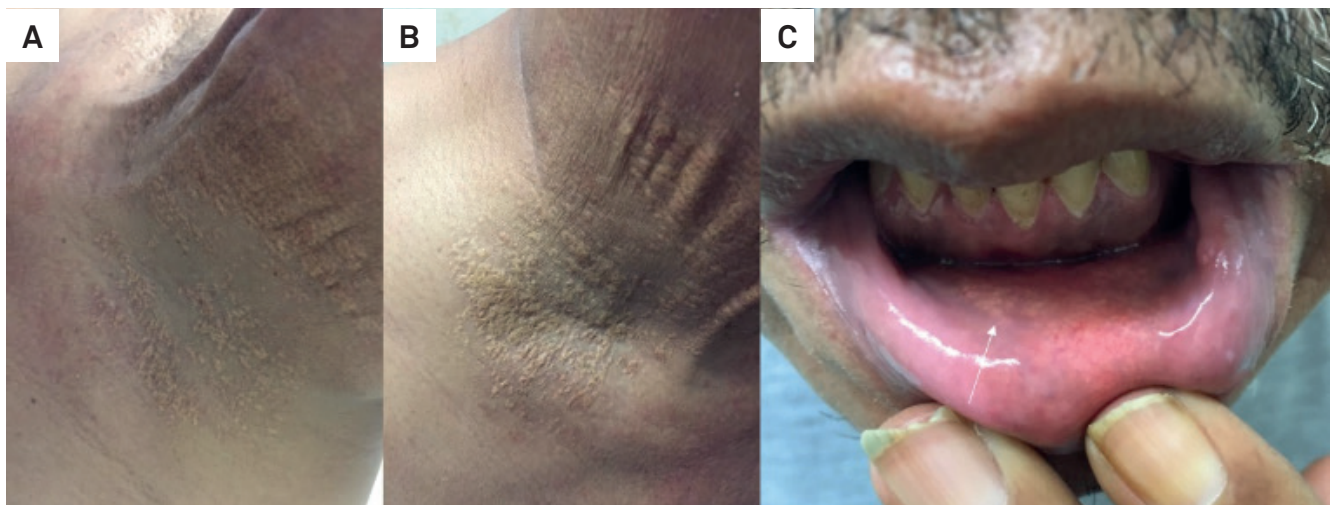






Figure 1. Typical skin lesions in pseudoxanthoma elasticum. Note the presence of (A,B) axillary and neck yellowish papules and plaques with cobblestone appearance and (C) mucosal lesions in the inner aspect of the lower lip (white arrow).

¹Universidade Federal de São Paulo, Departamento de Neurologia e Neurocirurgia, São Paulo SP, Brasil.

Paulo Victor Sgobbi de Souza  <https://orcid.org/0000-0002-7416-7108>; Bruno de Mattos Lombardi Badia  <https://orcid.org/0000-0001-7360-0494>; Wladimir Bocca Vieira de Rezende Pinto  <https://orcid.org/0000-0002-0150-525X>; Acary Souza Bulle Oliveira  <https://orcid.org/0000-0002-6986-4937>

Correspondence: Wladimir Bocca Vieira de Rezende Pinto; Departamento de Neurologia e Neurocirurgia da UNIFESP; Rua Estado de Israel, 899; 04022-002 São Paulo SP, Brasil; E-mail: wladimirbvpinto@gmail.com

Conflict of interest: There is no conflict of interest to declare.

Ethical statement: Full consent was obtained from the patient for the case report. This study was approved by our Ethics Institution.

Received 14 December 2018; Received in final form 03 February 2019; Accepted 16 February 2019.

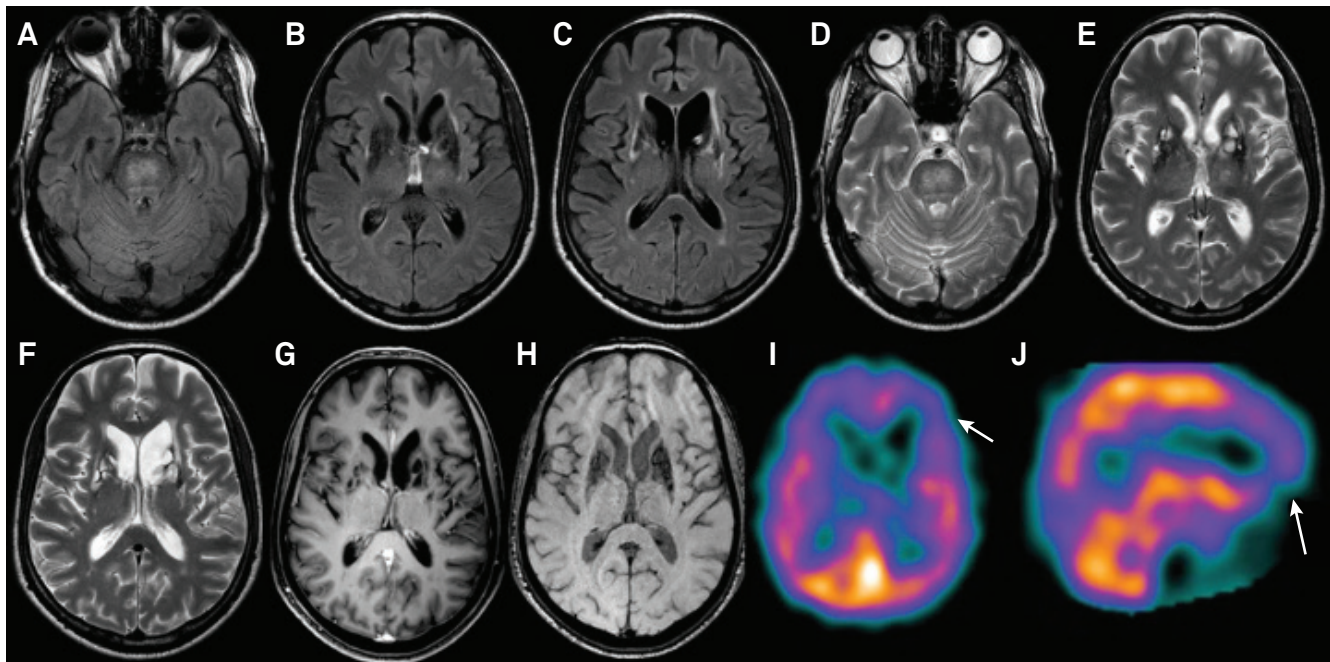


Figure 2. Neuroimaging findings in pseudoxanthoma elasticum. Axial brain MR imaging showing multiple pontine and bilateral basal ganglia lacunar infarcts with iron deposition in FLAIR sequence (A-C), T2-weighted imaging (D-F), T1-weighted imaging (G) and SWI sequences (H). (I,J) Brain Tc-99m SPECT disclosing bilateral frontal hypoperfusion (white arrows).

References

1. Chassaing N, Martin L, Calvas P, Le Bert M, Hovnanian A. Pseudoxanthoma elasticum: a clinical, pathophysiological and genetic update including 11 novel ABCC6 mutations. *J Med Genet* 2005 Dec;42(12):881-92. <https://doi.org/10.1136/jmg.2004.030171>
2. Renard D, Castelnovo G, Jeanjean L, Perrochia H, Brunel H, Labauge P. Teaching neuroimage: microangiopathic complications in pseudoxanthoma elasticum. *Neurology*. 2008 Nov;71(22):e69. <https://doi.org/10.1212/01.wnl.0000335934.11120.83>