

Teaching brainstem anatomy using a sharply-located demyelinating plaque of multiple sclerosis

Ensinando anatomia do tronco cerebral através da exata localização de uma placa desmielinizante de esclerose múltipla

Yara Dadalti FRAGOSO^{1,2}, Francisco Martinez de CARVALHO³, Valeria Mendes AKIAU³, Eduardo A. Guimaraes NOGUEIRA², Vitor Martinez de CARVALHO²

Studying neuroanatomy can be made more interesting when clinical and imaging findings show correlations within areas of the central nervous system. This young woman presented with diplopia and had a demyelinating plaque in the region of the left abducens nucleus. Remaining lesions and spinal fluid analysis confirmed her diagnosis of multiple

sclerosis¹. In neuroanatomy classes, vascular lesions and tumors are often used to show the exact location of brain structures, but multiple sclerosis is not usually presented to students with this purpose. Students may improve their understanding of neuroanatomy when the relevance of the subject is made clear by medical cases (Figure).

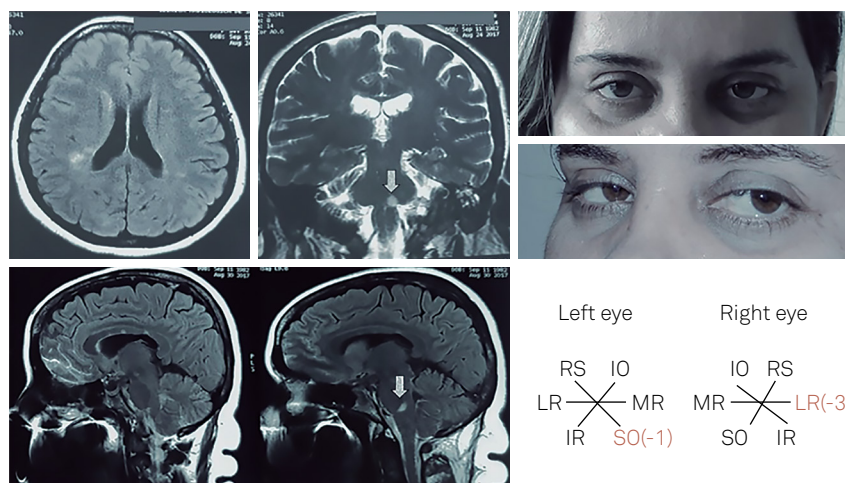


Figure. Demyelinating lesion at the posterior limit of the pons and mesencephalon marked the exact spot (left abducens nucleus) of a plaque generating the clinical findings of diplopia due to left abducens nerve paresis (shown in the patient's photograph).






Reference

1. Krieger SC, Cook K, De Nino S, Fletcher M. The topographical model of multiple sclerosis: A dynamic visualization of disease course. *Neurol Neuroimmunol Neuroinflamm*. 2016 Sep;3(5):e279. <https://doi.org/10.1212/NXI.0000000000000279>.

¹Universidade Metropolitana de Santos, Santos SP, Brasil;

²Instituto de Pesquisa de Cefaleia e Esclerose Múltipla, Santos SP, Brasil;

³Clínica de Olhos Francisco Carvalho, São Vicente, SP, Brasil.

Yara Dadalti Fragoso  <https://orcid.org/0000-0001-8726-089X>; Francisco Martinez de Carvalho  <https://orcid.org/0000-0001-8053-6435>; Valeria Mendes Akiau  <https://orcid.org/0000-0002-2762-2120>; Eduardo A. Guimaraes Nogueira  <https://orcid.org/0000-0002-6035-560X>; Vitor Martinez de Carvalho  <https://orcid.org/0000-0001-6220-877X>

Correspondence: Yara Dadalti Fragoso; Departamento de Neurologia da Faculdade de Medicina / UNIMES. Avenida Conselheiro Nebias, 536 - 11045-002 Santos SP, Brasil; E-mail: yara@bsnet.com.br

Conflict of interest: There is no conflict of interest to declare.

Received 10 December 2018; Received in final form 04 March 2019; Accepted 26 March 2019.