

Transient lesion in the splenium of the corpus callosum associated with COVID-19

Lesão transitória no esplênio do corpo caloso associada à COVID-19

Felipe Araújo Andrade DE OLIVEIRA^{1,2}, Tiago Feitosa Bastos DE MELO¹, Pedro Augusto Sampaio ROCHA-FILHO²

A healthy 40-year-old man experienced flu-like symptoms for four days and sought hospital care due to presenting progressive paresthesias in the extremities, mild headache, and visual turbidity. He had used only ivermectin and azithromycin. In the neurological examination, the patient presented a decrease in visual acuity in the left eye. The COVID-19 test using the nasal swab reverse transcription-polymerase chain reaction (RT-PCR) technique was positive. There were no metabolic disorders. The symptoms

improved within seven days. Magnetic resonance imaging (MRI) demonstrated an ovoid lesion in the splenium of the corpus callosum with fluid-attenuated inversion recovery (FLAIR) hyperintensity, restricted diffusion and no gadolinium enhancement (Figure 1), which disappeared in a follow-up MRI one month later (Figure 2). Transient lesions of the splenium of the corpus callosum can be caused by other viruses^{1,2}, but to our knowledge this is the first report of association with COVID-19^{3,4,5}.

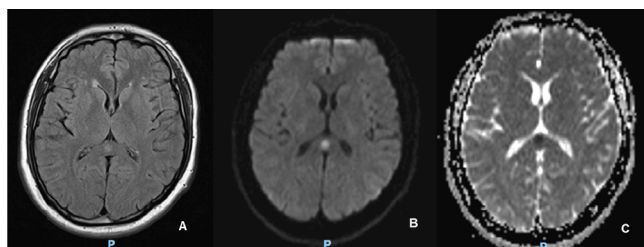


Figure 1. Magnetic resonance imaging demonstrating an ovoid lesion in the splenium of the corpus callosum with fluid-attenuated inversion recovery hyperintensity (A) and restricted diffusion (B, C).

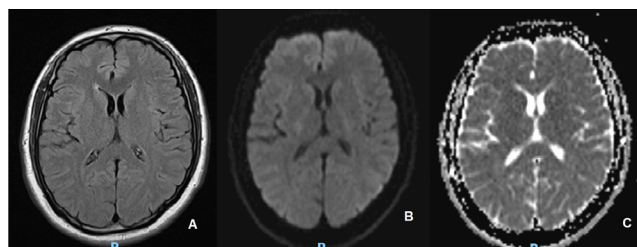





Figure 2. Follow-up magnetic resonance imaging one month later demonstrating complete resolution of the lesion in fluid-attenuated inversion recovery (A) and diffusion (B, C).

References

1. Tetsuka S. Reversible lesion in the splenium of the corpus callosum. *Brain Behav.* 2019 Nov;9(11):e01440. <https://doi.org/10.1002/brb3.1440>
2. Starkey J, Kobayashi N, Numaguchi Y, Moritani T. Cytotoxic lesions of the corpus callosum that show restricted diffusion: mechanisms, causes, and manifestations. *Radiographics.* 2017 Mar;37(2):562-76. <https://doi.org/10.1148/rg.2017160085>
3. Munhoz RP, Pedrosa JL, Nascimento FA, De Almeida SM, Barsottini OGP, Cardoso FEC, Teive HAG. Neurological complications in patients with SARS-CoV-2 infection: a systematic review. *Arq Neuropsiquiatr.* 2020 May;78(5):290-300. <https://doi.org/10.1590/0004-282X20200051>
4. Vacchiano V, Riguzzi P, Volpi L, Tappatà M, Avoni P, Rizzo G, et al. Early neurological manifestations of hospitalized COVID-19 patients. *Neurol Sci.* 2020 Aug;41(8):2029-31. <https://doi.org/10.1007/s10072-020-04525-z>
5. Niazkar HR, Zibae B, Nasimi A, Bahri N. The neurological manifestations of COVID-19: a review article. *Neurol Sci.* 2020 Jul;41(7):1667-71. <https://doi.org/10.1007/s10072-020-04486-3>

¹Real Hospital Português de Beneficência de Pernambuco, Recife PE, Brazil.

²Universidade Federal de Pernambuco, Centro de Ciências Médicas, Área Acadêmica de Neuropsiquiatria, Recife PE, Brazil.

Felipe Araújo Andrade DE OLIVEIRA  <https://orcid.org/0000-0002-9583-3165>; Tiago Feitosa Bastos DE MELO  <https://orcid.org/0000-0002-5975-7804>; Pedro Augusto Sampaio ROCHA-FILHO  <https://orcid.org/0000-0001-5725-2637>

Correspondence: Felipe Araújo Andrade de Oliveira; E-mail: felipe.oliveira1983@gmail.com

Conflict of interest: There is no conflict of interest to declare.

Authors' contribution: FAAO: conceptualization, data curation, investigation, writing of original draft, review & editing of final version. TFBM: conceptualization, data curation & investigation. PASRF: writing of original draft, review & editing of final version.

Received on August 19, 2020; Received in its final form on September 9, 2020; Accepted on September 14, 2020.