

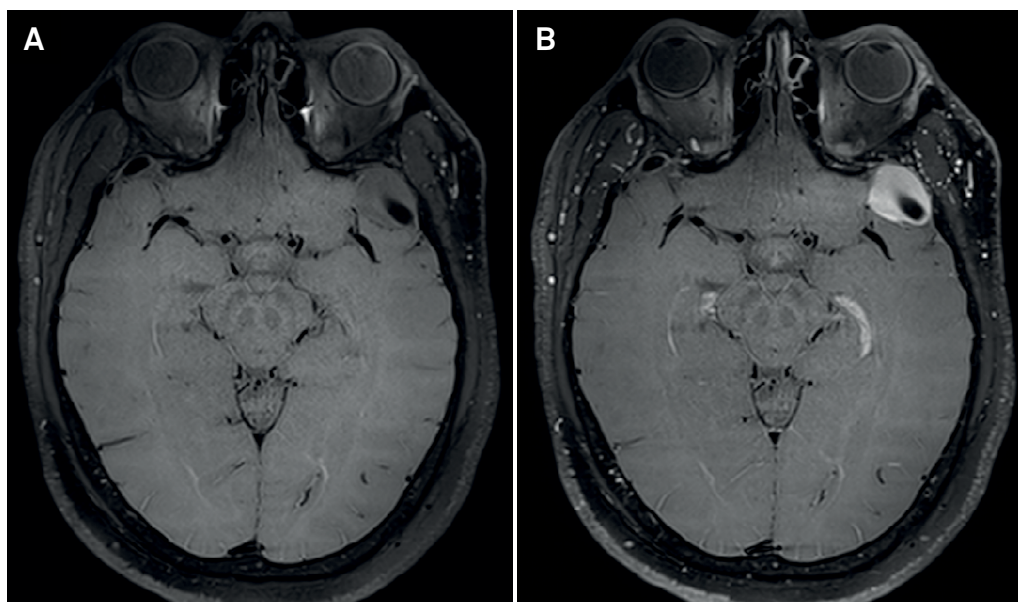
# Intracranial isolated varix mimicking a meningioma: the relevance of modern MRI techniques for reliable diagnosis

Variz intracraniana isolada mimetizando um meningioma: a relevância de técnicas modernas de RM para um diagnóstico confiável

Diogo Goulart CORRÊA<sup>1,2</sup>, Luiz Celso HYGINO DA CRUZ JR.<sup>1</sup>

A 37-year-old man presented with headache. Brain vessel wall magnetic resonance imaging revealed a left temporal vascular ectasia with heterogeneous flow (Figure 1). Four-dimensional time-resolved magnetic resonance angiography (4DMRA) showed the lesion being progressively filled by contrast during the venous phase, with no arterial feeders (Figure 2 and Video).



Isolated intracranial varix is a focal dilatation of a vein, without neural tissue or other vessels anomalies<sup>1</sup>. Its main differential diagnoses are meningioma and arteriovenous fistula<sup>2</sup>. Vessel wall imaging and 4DMRA can appropriately show the internal flow, absence of arterial components and progressive filling, during the venous phase, confirming the diagnosis and avoiding unnecessary surgery.



**Figure 1.** Isolated intracranial varix. Ectasia of a left temporal cortical venous vessel, well identified in the axial 3-D T1 dark-blood image, for intracranial vessel wall MRI, pre- (A) and postintravenous contrast injection (B), with heterogeneous filling by the contrast agent. Note the flow-void inside the lesion and its well-demarcated and smooth contours, marking the vascular nature of the lesion.

<sup>1</sup>Clínica de Diagnóstico por Imagem (CDPI), Rio de Janeiro RJ, Brasil.

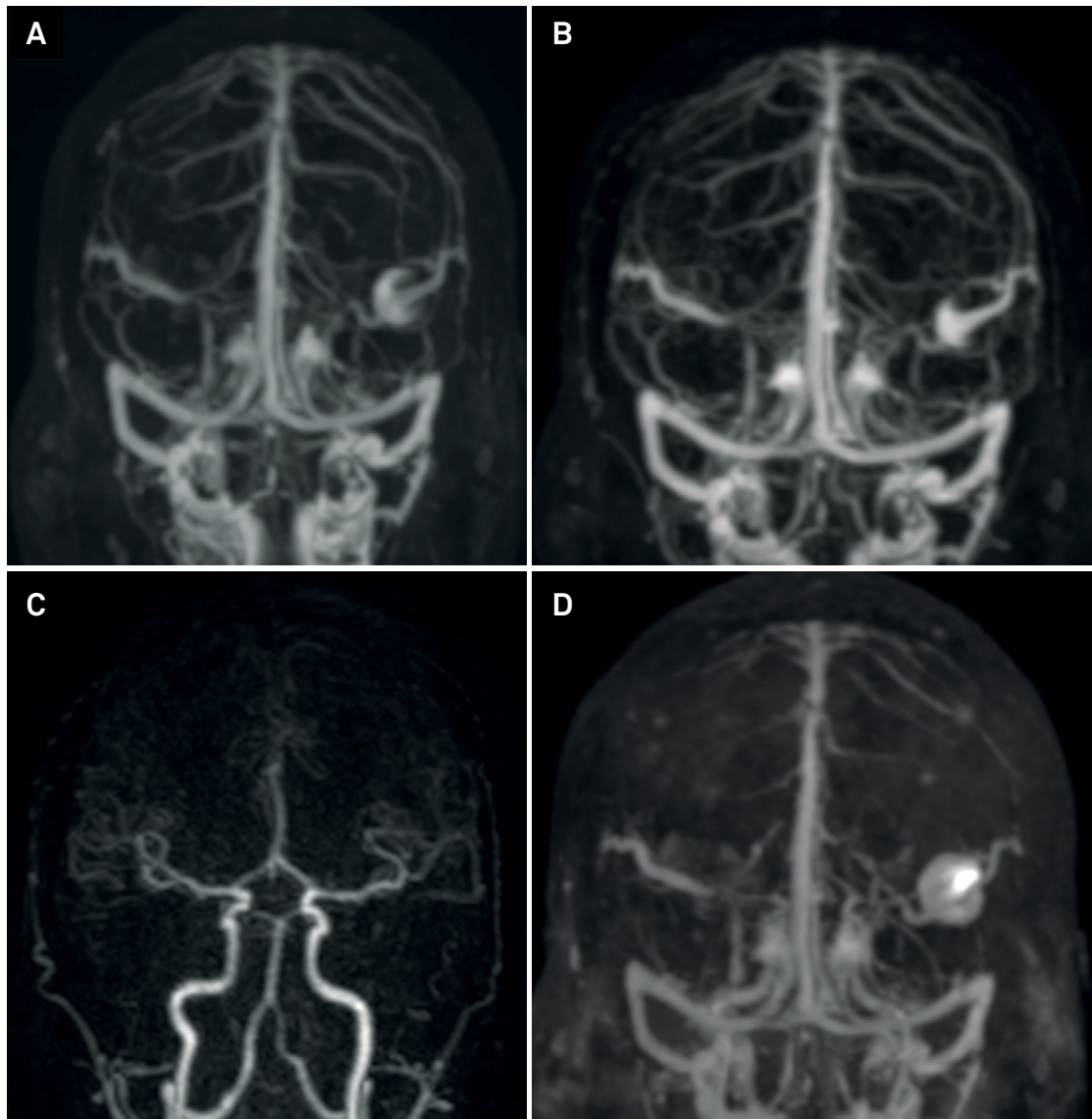
<sup>2</sup>Universidade Federal do Rio de Janeiro, Hospital Universitário Clementino Fraga Filho, Departamento de Radiologia, Rio de Janeiro RJ, Brasil.

Diogo Goulart Corrêa  <https://orcid.org/0000-0003-4902-0021>; Luiz Celso Hygino da Cruz Jr  <https://orcid.org/0000-0002-9771-5832>

**Correspondence:** Diogo Goulart Corrêa; UFRJ; Rua Rodolpho Paulo Rocco 255, Cidade Universitária, Ilha do Fundão; 21941-913 Rio de Janeiro RJ, Brasil; E-mail: diogogoulartcorrea@yahoo.com.br

**Conflict of interest:** There is no conflict of interest to declare.

Received 29 January 2019; Received in final form 30 March 2019; Accepted 19 May 2019.



**Figure 2.** Isolated intracranial varix. 4D time-resolved MR angiography showed no arterial abnormalities (A) and progressive filling of the intracranial varix during the venous phase (B, C and D), with no arterial feeders or signs of arteriovenous malformation.

## References

1. Hoell T, Hohaus C, Beier A, Holzhausen HJ, Meisel HJ. Cortical venous aneurysm isolated cerebral varix. *Interv Neuroradiol.* 2004 Jun;10(2):161-5. <https://doi.org/10.1177/159101990401000210>
2. Tan ZG, Zhou Q, Cui Y, Yi L, Ouyang Y, Jiang Y. Extra-axial isolated cerebral varix misdiagnosed as convexity meningioma: a case report and review of literatures. *Medicine (Baltimore).* 2016 Jun;95(26):e4047. <https://doi.org/10.1097/MD.0000000000004047>

**ERRATUM**

In the manuscript “Intracranial isolated varix mimicking a meningioma: the relevance of modern MRI techniques for reliable diagnosis”, DOI: 10.1590/0004-282X20190125, published in the Arq Neuropsiquiatr 2020;78(2):124-5. Epub Jan 20, 2020, on page 125, Figure 2

**Where it shows:**

**It should be:**

