

Reply to the letter “Multifocal T2-/DWI-hyperintense cerebral lesions in COVID-19 not necessarily imply demyelination”

Resposta à carta “Lesões cerebrais multifocais hiperintensas em T2/DWI na COVID-19 não implicam necessariamente desmielinização”

Agábio Diógenes PESSOA NETO¹, Manoella do Monte ALVES², Paulo Santiago de Moraes BRITO¹, Manuel MOREIRA NETO³, Rodrigo Alencar e SILVA¹, Mario Emílio TEIXEIRA DOURADO JUNIOR¹, Clécio de Oliveira GODEIRO JUNIOR¹

We would like to thank Finsterer et al.¹ for their interest in our short clinical vignette. Their comments and concerns give us an opportunity to further discuss this case report.

Neurological complications in COVID-19 patients are a knowledge in progress. We agree that our case may have several differential diagnoses. Although our patient's lesions did not show post-contrast enhancement, they had a perivenular aspect (Figure 1) and disappeared after high doses of corticosteroids.

Contrast enhancement may not occur in some demyelinating lesions, including in ADEM-like presentations, which was the main possibility for our case. Gadolinium enhancement in ADEM is variable and may be absent, not invalidating its demyelinating nature². The DWI sequence was normal and the lesions disappeared, which did not favor the diagnosis of ischemic injury. Our patient, in addition, had no previous cardiovascular risk factors, and his echocardiogram and electrocardiogram were normal. Lesions were transitory and without bleeding, which goes against the diagnosis of acute necrotizing encephalitis.

We agree that we must include the possibility of PRES. We know that PRES syndrome can be precipitated by the use of corticosteroids³. There was also no evidence of hypertensive hemodynamic changes of note in this patient. That is why we used the term possible and not definitive worsening symptoms. SWI and ADC did not provide any additional data

(Figure 1). Spectroscopy and perfusion-weighted imaging sequences were not available in our center.

We did not perform electroneuromyography, although his clinical presentation was suggestive of critically ill patient neuropathy.

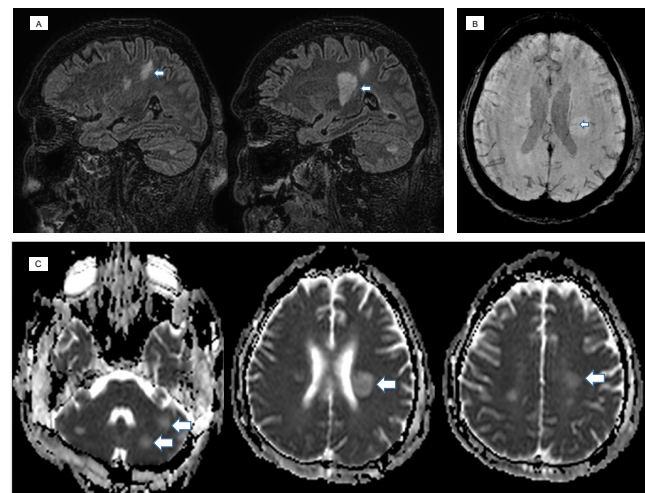






Figure 1. (A) FLAIR/T2 images in the sagittal plane showing lesions with hyperintensity with a larger axis perpendicular to the ependymal surface of the lateral ventricles (see arrows) and absence of restriction to diffusion, suggesting demyelinating lesions; (B) axial SWI showing periventricular lesions with perivenular involvement (see arrows), suggesting demyelinating lesions. (C) ADC map showing lesions with hyperintensity (high diffusion of water molecules, see arrows).



¹Hospital Universitário Onofre Lopes, Departamento de Neurologia, Natal RN, Brazil.

²Hospital Giselda Trigueiro, Departamento de Doenças Infecciosas, Natal RN, Brazil.

³Hospital Universitário Onofre Lopes, Departamento de Radiologia, Natal RN, Brazil.

Agábio Diógenes PESSOA NETO  <https://orcid.org/0000-0003-2937-5298>; Manoella do Monte ALVES  <https://orcid.org/0000-0003-2485-3502>;

Paulo Santiago de Moraes BRITO  <https://orcid.org/0000-0002-0010-7217>; Manuel MOREIRA NETO  <https://orcid.org/0000-0002-3478-5323>;

Rodrigo Alencar e SILVA  <https://orcid.org/0000-0002-3311-0164>; Mario Emílio TEIXEIRA DOURADO JUNIOR  <https://orcid.org/0000-0002-9462-2294>;

Clécio de Oliveira GODEIRO JUNIOR  <https://orcid.org/0000-0002-4312-1633>

Correspondence: Agábio Diógenes Pessoa Neto; E-mail: agabio.medbio@gmail.com.

Conflict of interest: There is no conflict of interest to declare.

Authors' contributions: The authors contributed equally to the manuscript.

Received on December 7, 2020; Received in its final form on December 15, 2020; Accepted on December 15, 2020.

Peripheral nerve complications have been described in COVID-19 patients. Most reports are related to Guillain-Barré syndrome and its variants⁴. We were unable to adequately exclude the concomitance of this manifestation in our patient. Examination of cerebrospinal fluid is crucial. However, we were unable to perform it because he had an extensive pressure ulcer in the lumbosacral region, which even required antimicrobial therapy.

The main message of this case was to think about the possibility of demyelinating autoimmune lesions occurrence after COVID-19 infection, even within a scenario in which the patient does not present all the criteria and characteristics typical for this disease. In this context, high doses of corticosteroids may be considered to treat and improve clinical recovery.

References

1. Finsterer J, Scorza FA, Scorza CA, Fiorini AC. Multifocal T2-/DWI-hyperintense cerebral lesions in COVID-19 not necessarily imply demyelination. *Arq Neuro-Psiquiatr*. 2020. In Press.
2. Hardy TA, Reddel SW, Barnett MH, Palace J, Lucchinetti CF, Weinshenker BG. Atypical inflammatory demyelinating syndromes of the CNS. *Lancet Neurology*. 2016 Aug;15:976-81. [https://doi.org/10.1016/S1474-4422\(16\)30043-6](https://doi.org/10.1016/S1474-4422(16)30043-6)
3. Parikh NS, Schweitzer AD, Young RJ, Giambone AE, Lyo J, Karimi S, et al. Corticosteroid therapy and severity of vasogenic edema in posterior reversible encephalopathy syndrome. *J Neurol Sci*. 2017 Sep;380:11-5. <https://doi.org/10.1016/j.jns.2017.06.044>
4. Faqih F, Alharthy A, Memish ZA, Kutsogiannis DJ, Brindley PG, Karakitsos D. Peripheral neuropathy in severe COVID-19 resolved with therapeutic plasma exchange. *Clin Case Rep*. 2020 Oct;00:1-6. <https://doi.org/10.1002/ccr3.3397>