

# The Sistine Chapel and clothesline signs: a tale of two arteries

## *O sinal da Capela Sistina e sinal do varal: um conto sobre duas artérias*

Léo Coutinho<sup>1</sup> João Matheus Tussolini Marcon<sup>2</sup> Ellen Riedi Oliveira<sup>2</sup>  
 Camila Emi Fujiwara Murakami<sup>2</sup> Jessica Castro Silva<sup>2</sup> Juliano André Muzzio<sup>3</sup>  
 Viviane Hiroki Flumignan Zetola<sup>3</sup> Marcos Christiano Lange<sup>3</sup> Carlos Alberto Engelhorn<sup>4</sup>  
 Paulo Cesar Evaristo Souza<sup>5</sup> Hélio Afonso Ghizoni Teive<sup>1,6</sup>

<sup>1</sup> Universidade Federal do Paraná, Programa de Pós-Graduação em Medicina Interna e Ciências da Saúde, Grupo de Doenças Neurológicas, Curitiba PR, Brazil.

<sup>2</sup> Universidade Federal do Paraná, Curso de Medicina, Curitiba PR, Brazil.

<sup>3</sup> Universidade Federal do Paraná, Serviço de Neurologia, Unidade Cerebrovascular, Curitiba PR, Brazil.

<sup>4</sup> Angiolab, Curitiba PR, Brazil.

Address for correspondence Léo Coutinho  
 (e-mail: leocoutinho23@hotmail.com).

<sup>5</sup> Universidade Federal do Paraná, Serviço de Neurorradiologia, Curitiba PR, Brazil.

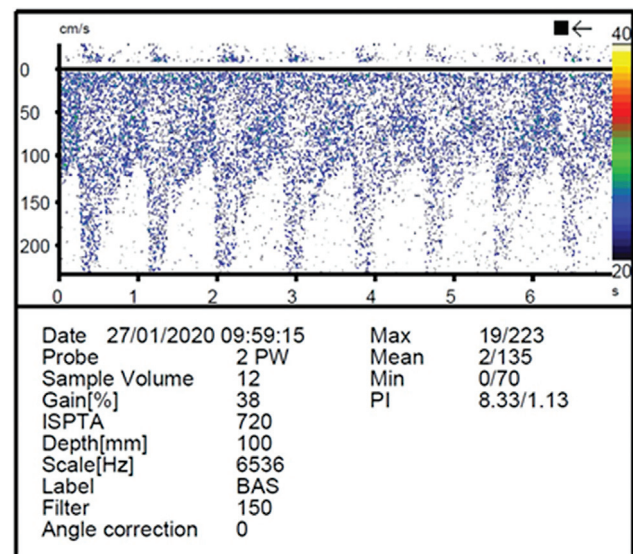
<sup>6</sup> Universidade Federal do Paraná, Serviço de Neurologia, Unidade de Distúrbios de Movimento, Curitiba PR, Brazil.

Arq. Neuropsiquiatr. 2022;80(11):1182–1183.

An 83-year-old woman presented sudden vertigo, drop attack, and transient dysarthria after head hyperextension to see the Sistine Chapel ceiling, in the Vatican. Transcranial doppler ultrasound (► **Figure 1**) suggested proximal basilar stenosis, confirmed by arteriography (► **Figure 2**). Case 2: A 77-year-old woman presented a 1-year history of transient vertigo after hanging clothes on a clothesline. Transcranial doppler ultrasound (► **Figure 3**) revealed left subclavian artery steal phenomenon secondary to proximal subclavian artery stenosis, confirmed by arteriography (► **Figure 4**). They received stenting and dual antiplatelet therapy. Transient ischemic symptomatology triggered by head/neck and arm movements demands vertebrobasilar and subclavian evaluation.<sup>1–3</sup>

### Authors' Contributions

LC: Organization and execution of the research project, writhing of the first draft and of the final manuscript; JMTM, ERO, CEFM, JCS, JAM, VHFZ, MCL, CAE, PCES: organization and execution of the research project, writhing of the first draft of the manuscript; HAGT: conception

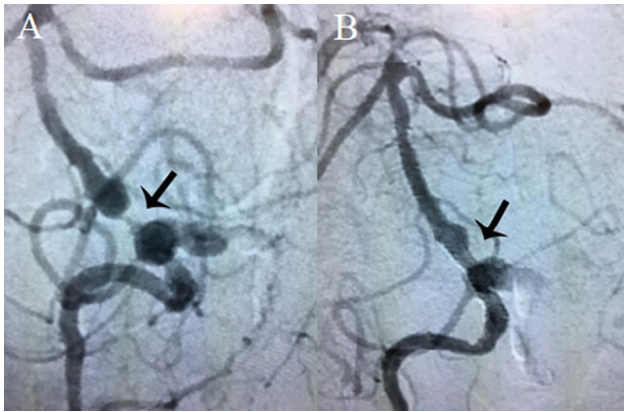


**Figure 1** Transcranial Doppler show signs of segmental increase in flow velocity in the proximal basilar artery, compatible with basilar artery stenosis.

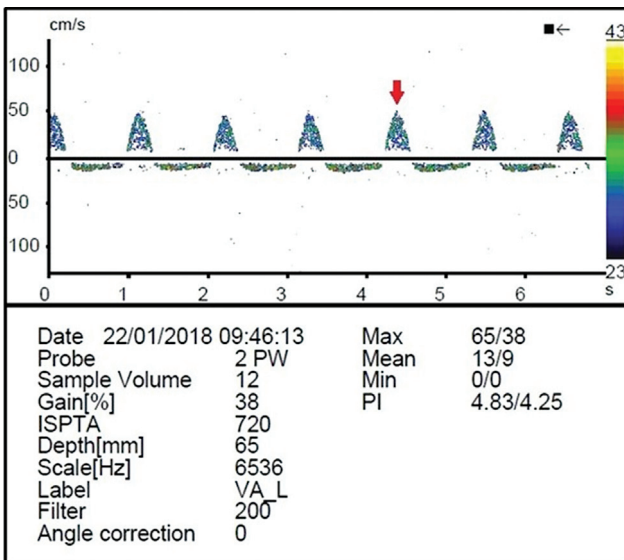
received  
 May 8, 2022  
 accepted  
 June 15, 2022

DOI <https://doi.org/10.1055/s-0042-1758395>.  
 ISSN 0004-282X.

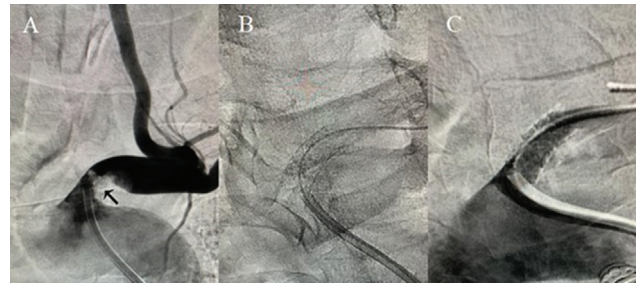
© 2022. Academia Brasileira de Neurologia. All rights reserved.  
 This is an open access article published by Thieme under the terms of the Creative Commons Attribution 4.0 International License, permitting copying and reproduction so long as the original work is given appropriate credit (<https://creativecommons.org/licenses/by/4.0/>).  
 Thieme Revinter Publicações Ltda., Rua do Matoso 170, Rio de Janeiro, RJ, CEP 20270-135, Brazil



**Figure 2** Brain arteriography showing severe stenosis in the proximal basilar artery (A). Postangioplasty control with stent in the proximal basilar artery (B).



**Figure 3** Systolic flow reversal in the left vertebral artery at transcranial doppler ultrasound (arrow), compatible with grade 2 subclavian steal syndrome (intermittent or partial).



**Figure 4** Cervical arteriography demonstrating a critical lesion in the origin of the left subclavian artery, promoting subclavian steal syndrome (A). Cervical arteriography after subclavian artery angioplasty with stent positioning (B) (C).

of the research project, review and critique, writing of the final manuscript.

**Conflict of Interest**

The author have no conflict of interests to declare.

**References**

- 1 Go JA, Al Othman B, Kini A, Beaver HA, Lee AG. Vertebrobasilar ischemia (VBI) related neuro-ophthalmic syndromes after routine activities involving hyperextension or rotation of the neck (hairdresser syndrome). *Eye (Lond)* 2020;34(05):901–905
- 2 Savitz SI, Caplan LR. Vertebrobasilar disease. *N Engl J Med* 2005; 352(25):2618–2626
- 3 Kargiotis O, Siahos S, Safouris A, Feleskouras A, Magoufis G, Tsvigoulis G. Subclavian steal syndrome with or without arterial stenosis: A review. *J Neuroimaging* 2016;26(05):473–480