

The falling teacup: a curious stroke case

A queda de uma chávena: um caso interessante de acidente vascular cerebral

Augusto RACHÃO¹, Tiago GERALDES¹, Cláudia GUARDA¹

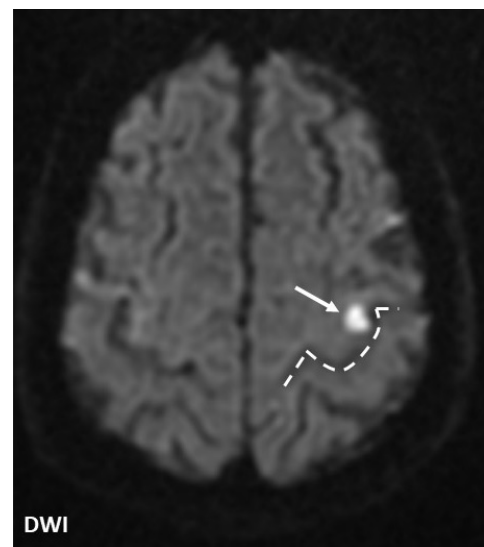
A 63-year-old man presented with sudden-onset right index finger weakness that made him drop his morning teacup. He could not fully extend, adduct, and abduct his finger (Figure 1). A brain magnetic resonance imaging revealed a minor acute ischemic lesion on the left precentral cortex, in the hand knob (HK) area (Figure 2), of undetermined etiology.

HK infarctions are uncommon, often cardioembolic, and can present with different patterns of isolated hand weakness¹. This case illustrates the rare involvement of a single

finger following HK stroke and strengthens the existence of finger somatotopy in human motor cortex^{1,2}. This observation helps clarifying motor cortex anatomy and clinical correlations, further detailing the Penfield's homunculus³, its first proposed somatotopic organization.

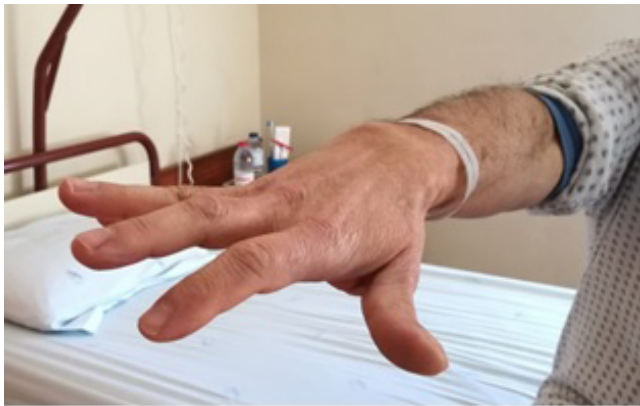

Figure 1. Photograph of the involved hand, evidencing a tendency toward the flexion of the right index finger, since the patient could not fully extend, adduct, and abduct it.



DWI: diffusion weighted imaging.

Figure 2. Brain magnetic resonance imaging (axial section) displaying an acute infarction (white arrow) in the hand knob territory, presenting as an inverted omega (dashed line).

References

1. Finkelsteyn AM, Saucedo MA, Miquelini LA, Chertcoff A, Bando L, Pacha S, et al. Ischemic stroke of the "hand knob area": A case series and literature review. *J Clin Neurosci*. 2019 Mar;65:100-5. <https://doi.org/10.1016/j.jocn.2019.03.025>
2. Beisteiner R, Windischberger C, Lanzenberger R, Edward V, Cunnington R, Erdler M, et al. Finger somatotopy in human motor cortex. *Neuroimage*. 2001 Jun;13(6 Pt 1):1016-26. <https://doi.org/10.1006/nimg.2000.0737>
3. Penfield W, Rasmussen T. The cerebral cortex of man: a clinical study of localization of function. *JAMA*. 1950 Dec;144(16):1412. <https://doi.org/10.1001/jama.1950.02920160086033>

¹Hospital Garcia de Orta, Departamento de Neurologia, Almada, Portugal.

AR <https://orcid.org/0000-0002-1961-8164>; TG <https://orcid.org/0000-0003-0368-8851>; CG <https://orcid.org/0000-0001-7049-557X>

Correspondence: Augusto Rachão; Email: augusto-rachao_3@hotmail.com.

Conflict of interest: There is no conflict of interest to declare.

Authors' contributions: AR: approached the patient, conceptualized the work, wrote the original draft, and revised the final draft; TG: approached the patient and revised the final draft; CG: oversaw the work, approached the patient, and revised the final draft.

Received on April 22, 2021; Received in its final form on July 7, 2021; Accepted on July 24, 2021.