

# PROSPECTIVE AND COMPARATIVE STUDY BETWEEN CONSERVATIVE AND SURGICAL TREATMENT (MEDIAL PATELLOFEMORAL LIGAMENT REPAIR) IN PATELLAR ACUTE DISLOCATIONS

GILBERTO LUIS CAMANHO<sup>1</sup>, ALEXANDRE DE CHRISTO VIEGAS<sup>2</sup>, ALEXANDRE CARNEIRO BITAR<sup>3</sup>, MARCO KAWAMURA DEMANGE<sup>3</sup>, ARNALDO JOSÉ HERNANDEZ<sup>4</sup>

## SUMMARY

Two groups of patients with their first episode of traumatic patellofemoral acute dislocation were studied and prospectively followed up regarding recurrences and predisposing factors to dislocation. In Group I, 17 patients with mean age of 24.6 years old, being 11 females, were submitted to medial patellofemoral ligament repair within less than a month after trauma. The mean follow up time was 40.4 months and the least, 18 months. As a result, there was no recurrence of the dislocation, and two episodes of subdislocation. Nine patients presented predisposing factors to dislocation. In Group II, 15 patients with mean age of 26.8 years old, being eight females, were submitted to conservative treatment

with 18.5 days of immobilization, in average. The mean follow-up time was 35.7 months and the least, 11 months. Eight knees presented recurrence of the dislocation, only two knees were regarded as stable. In this group, 14 patients had predisposing factors. We concluded that the surgical treatment of traumatic patellofemoral acute dislocations presents superior outcomes regarding recurrence when compared to the conservative approach within the period of study. The presence of predisposing factors in our patient series did not influence the recurrences of patellofemoral dislocations.

**Keywords:** Knee; Patellar dislocation; Acute

## INTRODUCTION

Patellofemoral pathology is amongst the most common ones in the general and knee-expert orthopaedic doctors' practice, usually affecting teenagers and young adults<sup>(1)</sup>. Didactically, we divide patellofemoral affections into two large groups: the painful clinical syndrome and the patellar instabilities. Our study targeted patellar acute traumatic dislocations, an infrequent event, but many times underdiagnosed, which occurs due to traumas resulting from a combination of rotational movements in variable degrees of knee flexion.

Clinical history with trauma report, the painful missing step and hemarthrosis is common to most of knee acute injuries, in which clinical examination is difficult due to the presence of pain and to muscles spasms, which preclude an adequate movement of the joint that could enable a precise clinical diagnosis.

Hughston and Walsh<sup>(2)</sup> reported that patellofemoral dislocation is the most frequent cause of diagnostic error when assessing an acute knee. The authors mention the high frequency of patellar acute dislocations that are left undiagnosed in young male athlete patients.

Treatment is still controversial in literature; reconstruction, immediate repair and conservative treatment are approaches discussed. Warren and Marshall<sup>(3)</sup> described the medial patellofemoral ligament (MPFL). Knowledge of the anatomy and the understanding

of the biomechanical importance of this ligament from studies conducted in the 1990's<sup>(4,5,6,7)</sup> have led the authors to propose its repair and/ or reconstruction, achieving better and more uniform outcomes with surgical treatment of the acute patellar dislocation. However, the scarcity of controlled and comparative studies is noted. The objective of this study is to assess outcomes regarding dislocations relapse control, the immediate repair of medial patellofemoral ligament as an isolated procedure in acute patellofemoral dislocations, comparing them to conservative treatment.

## MATERIALS AND METHODS

Two groups of patients were prospectively studied. Inclusion criteria were: a) first episode of patellofemoral dislocation; b) history considered as traumatic; c) requirement of reduction maneuver; d) minimum follow-up time of 18 months from the first dislocation or relapse event during follow-up; e) absence of fracture at X-ray images on knee's frontal and lateral planes and patella's axial plane; f) absence of knee ligament injury; g) any previous surgery in that knee.

Two different groups were followed up from 2000 to May 2005. Group I was surgically treated, while Group II was conservatively treated.

In order to be able to assess the occurrence or not of predisposing factors, two criteria were used:

Gilberto Luis Camanho<sup>1</sup>, Alexandre de Christo Viegas<sup>2</sup>, Alexandre Carneiro Bitar<sup>3</sup>, Marco Kawamura Demange<sup>3</sup>, Arnaldo José Hernandez<sup>4</sup>

Study conducted at the Department and Institute of Orthopaedics and Traumatology of the Hospital das Clínicas, Medical College, University of São Paulo, and at the Camanho Orthopaedic Institute

Correspondences to: Rua Ovídio Pires de Campos, 333 – Chefia do Corpo Clínico do IOT – sala A 327

1. Full Professor of the Department of Orthopaedics and Traumatology, Medical College, University of São Paulo.
2. Master in Orthopaedics and Traumatology, Medical College, University of São Paulo.
3. Post-graduation student of the Department of Orthopaedics and Traumatology- FMUSP
4. Full Professor of the Department of Orthopaedics and Traumatology, Medical College, University of São Paulo

Received in: 07/08/05; approved in: 09/27/05

1-clinical criterion- patients were questioned about the occurrence of symptoms suggesting patellofemoral instability, with missing steps and complaints at deceleration, previously to dislocation episode.

2-X-ray criterion- X-ray criteria were assessed as described in a classical study by Dejour et al.<sup>(6)</sup> through X-ray images of the patella at lateral and axial planes, both at 30 degrees of knee flexion: trochlear dysplasia (cross sign, femoral trochlea depth, and trochlea bump) and high patella, according to the method by Caton and Deschamps.

Patients considered as having predisposing factors were those presenting either the clinical criterion or any of the X-ray criteria above.

Group I comprehended 17 patients, of which 11 were females, who experienced the first acute patellofemoral dislocation episode being treated by immediate repair of the medial patellofemoral ligament. All those patients were submitted to nuclear magnetic resonance (NMR) for diagnosing the extension of injuries caused by dislocation and the study of conditions predisposing dislocation. Once diagnosis was confirmed and the extension of injury was verified through the NMR, the patients were referred for medial patellofemoral ligament (MPFL) repair. All the patients were operated by the same surgeon (1st author) before completing one month of trauma determining dislocation (Table 1).

Mean age of patients on Group I was 24.6 years old, where the age group most affected was that ranging from 10 to 20 years old (9 patients).

Left side was affected in nine patients. Nine patients were considered as having predisposing factors.

The NMR enabled the diagnosis of injury and of the structural changes on the patella and femoral condyles (Figure 1). In five cases, there were sprain fractures of the medial border of the patella and, in nine cases, chondral injury of the lateral femoral condyle.

Nine patients presented with MPFL injury near patella, of which three had a diffuse-featured injury. eight patients had injuries at the femoral insertion of the MPFL, of which three had a diffuse-featured injury. Thus, six patients had a diffuse injury of the MPFL, although clearly located preferentially near patella or near femur.

After ligament repair, the patients were kept in removable immobilizers during three weeks. They were assessed twice a week, and at the moment of evaluation, passive flexion-extension movements were repeatedly performed by the orthopaedic doctor. Rehabilitation program started on the fourth

week and was concluded when patients achieved rehabilitation for the activity preceding patellofemoral dislocation. Mean time for rehabilitation was 104 days.

We had an average of 40.4 months of follow-up in the material studied. During this period, patients were submitted to test at least once at each 6 months, when their knees' status was assessed and we asked about the occurrence of dislocation relapses.

Group II comprehended 15 patients conservatively treated. From 2000 on, 23 patients presented with a patellar acute dislocation diagnosis at the emergence service of this Institution. From these, eight could not be found and/or lost follow-up. The 15 remaining patients, after X-ray evaluation of their predisposing factors, were

followed-up and submitted to inguino-malleolar immobilization (splints) for at least two weeks (mean: 18.5 days; nine for 21 days, four for 14 days, one for 30 days, and one for 35 days). Then, they were also submitted to physical therapy follow-up (Table 2).

Mean age of the patients was 26.8 years old (12- 74), with the age group mostly affected being the one between 10 and 20 years old (10 patients). Left side was mostly affected, in 11 patients (01 bilaterally). Eight were females.

Fourteen knees of 13 patients presented predisposing factors in this group. Regarding outcomes evaluation, we divided the knees as for patellofemoral instability into three types of different situations:

1- Patellofemoral dislocations relapse (total congruence loss between patella and trochlea);

2- Unstable, when the patient presented Apprehension Test + ( 9 ) or reported subdislocation, although without relapse.

3- Stable: knees of patients not presenting a positive Apprehension Test nor reporting subdislocation episodes.

Groups were considered as parametric concerning age and similar concerning gender, side, age at first dislocation episode. We used the chi-square statistical test, being considered as statistically significant if  $p < 0,05$ .

The study was approved by the Scientific Committee of IOT and Ethics Committee and HC-FMUSP.

## RESULTS

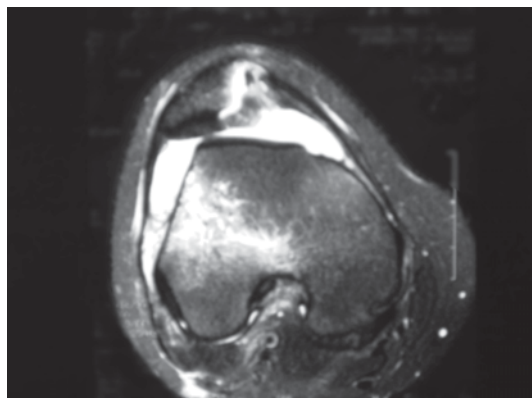
### GROUP I

All patients were submitted to arthroscopy of the knee, which enabled us to verify six cases of patellar osteochondral fracture, which compromised subchondral bone, not clearly visualized at the NMR.

	GENDER	AGE	SIDE	FT(months)
1	F	15	R	18
2	F	14	L	38
3	M	24	L	60
4	F	16	R	60
5	F	9	L	28
6	F	52	L	60
7	F	52	R	38
8	F	14	L	24
9	F	16	R	60
10	M	17	R	32
11	F	36	L	38
12	M	33	L	28
13	M	19	R	26
14	F	17	R	60
15	M	16	L	34
16	F	43	R	60
17	M	26	L	18

FT -Follow-up time ; FP -; M-Male ; F-Female ; R-Right ; L-Left

**Table 1 - Distribution of patients with patellofemoral acute dislocations submitted to MPFL repair (GROUP I), according to name, gender, age, dislocation side, follow-up time (FT).**



**Figure 1 - Magnetic resonance image showing patellar dislocation with signs of lateral femoral condyle contusion and sprain fracture of the medial patellar border.**

Injuries near the patella were sutured via arthroscopy (Figure 2) and femoral injuries were reinserted with anchors fixed at the femoral epicondyle (Figure 3).

Patients were assessed for an average period of 40.4 months, being 18 months the shortest evaluation time, in two cases, and 60 months the longest period.

For the purposes of this study, only the occurrence of relapses was studied.

No patient presented with relapse of the patellofemoral dislocation within the evaluation period; however, two (11.75%) patients reported subdislocation episodes, being considered as unstable.

During the mean time of 104 days, the patients returned to their usual activities. No complications occurred in this series.

## GROUP II

The patients submitted to conservative therapy were clinically followed up and assessed for symptoms that could show instability of the patellofemoral joint. Eight knees presented with patellofemoral dislocation relapse, from the remaining seven, only two were stable, since five demonstrated a positive Apprehension Test and/or clear complaints of subdislocations.

In 14 knees, at least one predisposing factor was identified. From these knees, seven presented with dislocation relapses (50%); but, of the remaining 7 in whom no relapse was evidenced, only one was considered as stable, since five demonstrated apprehension + and subdislocations and one only a + apprehension, although not reporting subdislocations.

Among the two knees not presenting predisposing factors, one patient (one knee) reported multiple relapse episodes (50%).

Regarding contralateral side, ten patients presented with asymptomatic contralateral knees, two with atraumatic instability, two traumatic (although 1 with less than 18 months of follow up and with no new dislocations, despite subdislocations) and only with painful symptoms. (Table 3).

## DISCUSSION

About our case series, we considered 32 patients as a sufficient number to compare with results described in literature, since this is an infrequent pathology, counting on few incidence reports, with patellar dislocations being many times underdiagnosed. Except for larger case series, such as the studies by Mäenpää and Lehto<sup>(10)</sup> and Cash and Hughston<sup>(11)</sup>, both with 100 patients, and the study by Garth et al.<sup>(12)</sup> with 58 patients, most of the studies on patellar acute dislocation present case series of less than 30 patients.

Mean age in our case series (24.6 for Group I, and 26.86 for Group II) was a little higher than the averages found in literature, as shown by the studies by Cash and Hughston<sup>(11)</sup> in 1996, Garth et al.<sup>(12)</sup> and

Atkin et al.<sup>(13)</sup>, both in 2000, with a mean age of 21.7, 15.8 and 19.9, respectively. We attribute this to the fact that, in our study, three patients were reported in our series with ages above 60 years old in Group I and two patients in Group II. The specific analysis of those patients showed that all of them had their patellas dislocated in clearly traumatic episodes during sports practice or in car accidents.

The slight prevalence of females in our series contrasts with some studies such as that by Cash and Hughston<sup>(11)</sup>, Garth et al.<sup>(12)</sup> and Atkin et al.<sup>(13)</sup> which described a higher incidence of this event in males, for being potentially more exposed to trauma. Nevertheless, it agrees with other studies, such as that by Hughston<sup>(1)</sup>, Cofield and Bryan<sup>(14)</sup> Ellera Gomes<sup>(15)</sup> in which the authors report a higher incidence of this kind of injury in women.

When we analyze predisposing and risk factors to dislocations relapse, according to Garth et al.<sup>(12)</sup> women present a higher incidence of bilateral affection and patellar hypermobility, but gender has not influenced their outcomes.

By analyzing our material, we see that relapse occurred in approximately half the number of women (04/08) and half in men (04/07) of Group II; however, when we analyze the patients without relapse, but with patellofemoral instability, the majority were females (4 females and 1 male) and from the knees considered as stable, both were males.

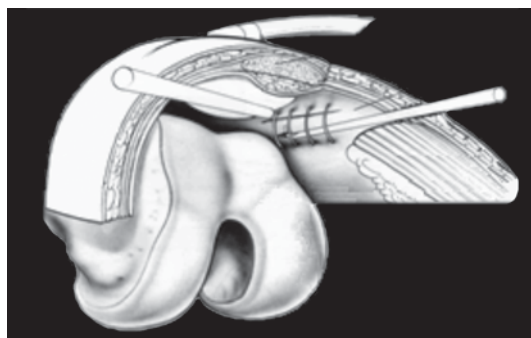
Regarding predisposing factors, the authors believe on the existence of anatomical changes related to relapses after patellar acute dislocation. Those changes may be clinical, as suggested by most of authors, such as Hughston<sup>(1)</sup> and Basset<sup>(16)</sup> or X-ray-related, as suggested some French studies. Hughston indeed considers that there is no dislocation without a predisposing factor. Dejour et al.<sup>(6)</sup> report that predisposing factors such as valgus knee, femoral trochlea dysplasias, extensor apparatus unbalances of multiple etiologies favor the occurrence of acute patellofemoral dislocation.

The authors also describe as radiological and radiographic predisposing factors: TA-TT (Tibial Anterior Tuberosity to trochlear "throat") measurements above 20 mm; the Trochlear Dysplasia, with qualitative parameters (cross sign) and quantitative (Trochlea bump with more than 3 mm and trochlear depth of 4 mm or less); Quadriceps Dysplasia with patellar Tilt in extension higher than 20 degrees at tomography (CT) and, ultimately, high patella by the Caton and Deschamps' index above 1.2. Others such as Cofield and Bryan<sup>(14)</sup> value the presence of patellar or femoral osteochondral fractures if they have never been surgically treated.

	GENDER	AGE	SIDE	FT(months)
1	M	74	L	24
2	F	18	L	24
3	F	12	L	18
4	M	25	R	60
5	F	62	R	58
6	F	18	L / R	30 / 18
7	F	20	L	58
8	M	35	R	27
9	F	18	L	59
10	M	17	L	32
11	M	18	L	36
12	M	20	R	33
13	F	20	L	60
14	M	20	L	24
15	F	26	L	11

FT -Follow-up time ; FP -; M-Male ; F-Female ; R-Right ; L-Left

**Table 2 - Distribution of patients with patellofemoral acute dislocation conservatively treated (GROUP II) according to name, gender, age, dislocation side, follow-up time (FT)**



**Figure 2 - Scheme showing arthroscopic suture of the MPFL**

Ellera Gomes<sup>(15)</sup>, in turn, highlights the importance of the traumatic factor as the major cause of patellar acute dislocation, reporting that, in average, only 10% of the patients with relapsing patellar dislocation mentioned in literature have been bilaterally operated and many of those predisposing factors are present in a single patient. In our series, only one patient had both knees affected by traumatic acute dislocation and with a minimum follow-up time of 18 months; however, two other patients reported history of non-traumatic dislocations on contralateral knee and one patient with traumatic dislocation with insufficient follow-up time.

Lastly, Larsen and Lauridsen<sup>(17)</sup> did not find dysplastic factors responsible for relapses in patellar acute dislocations and concluded that such factors cannot be used to anticipate instability symptoms development. However, they suggest that the age below 20 years old is related to a stronger trend to relapse. Ahmad et al.<sup>(18)</sup> also corroborate that the predisposing factors to dislocation are not important.

More than 50% of the 17 patients in group I and 87.5% (14 of the 16 knees) presented at

least one factor predisposing dislocation. We believe that the presence of valgus knee, trochlear dysplasias described by Dejour et al.<sup>(6)</sup> and the high patella strongly influence the occurrence of patellar acute dislocation; nevertheless, eight of our patients in group I and only two patients in group II had no clinical or radiographic sign that could be considered as a predisposing factor.

The simultaneous repair of predisposing factors combined to MPFL reconstruction has not been performed in any case, as suggested by Arendt et al.<sup>(19)</sup>.

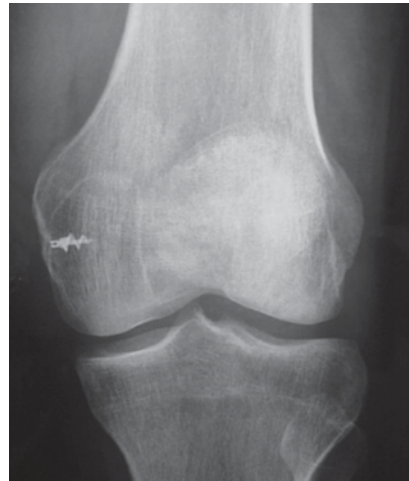The conservative treatment of acute patellofemoral dislocation leads to a high percentage of relapse. Cofield and Bryan<sup>(14)</sup> in 1977 reported that 50% of the patients had dislocation relapses with the conservative treatment.

Cash and Hughston<sup>(11)</sup> are contrary to literature, by prescribing surgery only for the cases of congenital abnormalities, since relapse rates with the conservative treatment was 43% with only 52% of good or excellent outcomes, while the group with no contralateral changes presents a relapse rate of 20% to conservative treatment and 75% of good and excellent outcomes. They report that in the cases where medial capsule was repaired, no relapse occurred. Mäenpää and Lehto<sup>(10)</sup> in a study with 100 patients assessed the conservative treatment of acute dislocations with three different techniques of non-surgical treatment with a relapse rate of approximately 40% and 60% of unsatisfactory outcomes.

So, Atkin et al.<sup>(13)</sup> after a standardized conservative treatment, present as results that 58% of the patients, within 6 months of trauma, demonstrated restraints to the practice of heavy sports.

Although the matter is polemic, there are classic studies in literature evidencing that surgical treatment leads to better outcomes concerning relapse.

The first authors to describe a case series were Boring and O'Donoghue<sup>(20)</sup> reporting their experience with the surgical approach for acute patellofemoral dislocation in 17 patients. In nine patients, they associated the medialization of the patellar tendon to



**Figure 3 - Frontal plane X-ray of the knee showing metallic anchor used for MPFL fixation**

Group	Predisposing Factor	Relapse	Unstable	Stable
Group I	09	0	02	15
Group II	14	08	06	02

**Table 3 - Comparative results between groups regarding Predisposing Factors, relapses, unstable, stable (number of knees)**

medial capsule repair, and in the others, they only performed a medial capsule repair. In all 17 cases there was no dislocation relapse.

With anatomical and biomechanical studies of the MPFL, there was a clear trend from authors to treat acute patellofemoral dislocation by repairing MPFL.

Kaplan<sup>(21)</sup> was the first to describe medial patellofemoral ligament, although he had not named it as such. From the pioneer study by Warren and Marshall<sup>(3)</sup> describing the medial capsuloligamentar anatomy of the knee, dividing it into three layers, more emphasis has been attributed to medial patellofemoral ligament; however, studies on this ligament gained impulse in the 1990's.

Feller et al.<sup>(4)</sup> and Boden et al.<sup>(5)</sup> mention the importance of MPFL on proprioception of surrounding musculature. By biomechanical studies, Conlan et al.<sup>(6)</sup>, Desio et al.<sup>(7)</sup>, Tuxoe et al.<sup>(22)</sup>, Sandmeier et al.<sup>(23)</sup> and Amis et al.<sup>(24)</sup> conclude that the MPFL accounts for approximately 50 to 70% of total lateral restraint, so being the primary patellar medial stabilizer.

Yamamoto<sup>(25)</sup> described the arthroscopic repair of the medial

capsule and retinaculum of the knee associated to the release of the lateral retinaculum in 30 cases of patellar acute dislocation; he reported achieving satisfactory outcomes in all cases, except for one, in which a traumatic dislocation occurred, and he emphasized the safety of the method and the benefit yielded by anatomical repair of defects resulting from patellar dislocation.

Regarding surgical treatment results, we found very few controlled studies in literature. The only prospective and randomized study is the one by Nikku et al.<sup>(26)</sup> reporting that surgical treatment is no better than the conservative one.

Sallay et al.<sup>(27)</sup>, in turn, also described a rate of 58% good and excellent outcomes according to Lysholm score and return to previous sports activities.

Ahmad et al.<sup>(18)</sup> performed the arthroscopic release of knee lateral retinaculum, followed by medial patellofemoral ligament repair and by the advancement of vastus medialis oblique muscle to the region of the adductor magnus tendon, not reporting any relapse case. They use the Kujala's Score and present satisfaction rates and patients' return to sports activities of 96 and 86%, respectively. In our environment, Ellera-Gomes et al.<sup>(15)</sup> published, in 1992, a technique to strengthen this ligament by using artificial ligament combined to arthroscopic technique for treating associate injuries. Aikanen et al.<sup>(28)</sup>, in 1993, propose the reconstruction of the MPFL with the tenodesis of the last eight cm distal to the adductor magnus m. tendon, since they consider that most of injuries occur at the femoral side (epicondyle); They assess 14 knees with 12 good outcomes and two moderate outcomes.

In 2001, Camanho and Viegas<sup>(29)</sup> initiated a research series, in which anatomy and biomechanical aspects of the Medial Patellofemoral Ligament are studied in cadavers.

Arendt et al.<sup>(19)</sup> believe that the ligament is united in elongation and it needs to be re-tensioned, except in cases of multifocal injury.

Lastly, Ellera-Gomes et al.<sup>(30)</sup>, in 2004, concluded that the MPFL reconstruction improves the mechanisms of patellofemoral insta-

bility, prevents insecurity, gradual deterioration of the joint, and pain during dislocation in at least five years of follow-up. Most authors describe the MPFL acute injury at the femoral epicondyle as much more frequent; in our material, injuries occurred 50% at the patella and 50% at the femoral condyle. We believed that the association of the injury assessment through NMR and arthroscopy in our case series enabled a more frequent diagnosis of injuries near patella. The occurrence of diffuse ligament injuries in 1/3 of the cases suggested that we should reconstruct MPFL with some kind of graft, but, in this series, we performed no reconstruction and no relapse occurred in this group of 6 patients, despite of two subdislocations. Dislocation relapse did not occur in any of our patients. The same outcome report is provided by authors of classic studies, such as

Cash and Hughston<sup>(11)</sup> and Boring and O'Donoghue<sup>(20)</sup> when mentioning the cases in which the patellofemoral acute dislocation was treated by employing a surgical approach. Authors such as Ahmad et al.<sup>(18)</sup>, Sallay et al.<sup>(27)</sup>, Boden et al.<sup>(5)</sup> who studied the results of isolated MPFL repair for treating patellofemoral acute dislocations, had no cases of dislocation relapse, as well.

## CONCLUSION

- 1- Surgical treatment of traumatic patellofemoral acute dislocations presents superior outcomes regarding relapse when compared to conservative treatment within the period assessed.
- 2- The presence of predisposing factors did not influence patellofemoral dislocations relapse.

## REFERENCES

1. Hughston JC. Subluxation of the patella. *J Bone Joint Surg Am* 1968; 50:1003-26.
2. Hughston JC, Walsh WM. Proximal and distal reconstruction of the extensor mechanism for patellar subluxation. *Clin Orthop* 1979; 144:36-42.
3. Warren LF, Marshall JL. The supporting structures and layers on the medial side of the knee. An anatomical analysis. *J Bone Joint Surg Am* 1979; 61:56-62.
4. Feller JA, Feagin JA Jr, Garrett WE Jr. The medial patellofemoral ligament revisited: an anatomical study. *Knee Surg Sports Traumatol Arthrosc* 1993; 1:184-6.
5. Boden PB, Pearsall AW, Garrett WE, Feagin JA. Patellofemoral instability: evaluation and management. *J Am. Acad Orthop Surg* 1997; 5:47-57.
6. Conlan T, Garth WP Jr, Lemons JE. Evaluation of the medial soft-tissue restraints of the extensor mechanism of the knee. *J Bone Joint Surg Am* 1993; 75:682-93.
7. Desio SM, Burks RT, Bachus KN. Soft tissue restraints to lateral patellar translation in the human knee. *Am J Sports Med* 1998; 26:59-65.
8. Dejour H, Walsh G, Nove-Josserand L, Guier C. Factors of patellar instability: an anatomical radiographic study. *Knee Surg Sports Traumatol Arthrosc* 1994; 2:19-26.
9. Dimon JH: Apprehension test for subluxation of the patella. *Clin Orthop* 1974; 103:39.
10. Mäenpää H, Lehto MU. Patellar dislocation: the long term results of non operative management in 100 patients. *Am J Sports Med* 1997; 25:213-7.
11. Cash JD, Hughston JC. Treatment of acute patellar dislocation. *Am J Sports Med* 1988; 16:244-9.
12. Garth WP, Pomphrey M, Merril K. Functional treatment of patellar dislocation in an athletic population. *Am J Sports Med* 1996; 24:785-91.
13. Atkin DM, Fithian DC, Marangi KS, Stone ML, Dobson BE, Mendelsohn C. Characteristics of patients with primary acute lateral patellar dislocation and their recovery within the first 6 months of injury. *Am J Sports Med* 2000; 28: 472-9.
14. Cofield RH, Bryan RS. Acute dislocation of the patella: results of conservative treatment. *J Trauma* 1977; 17:526-31.
15. Ellera Gomes JL. Medial patellofemoral ligament reconstruction for recurrent dislocation of the patella: a preliminary study. *Arthroscopy* 1992; 8:335-40.
16. Basset FH. Acute dislocation of the patella, osteochondral fractures, and injuries to the extensor mechanism of the knee. In: Burke E.: *American Academy of Orthopedic Surgeons Instructional Course Lectures*. St. Louis: CV Mosby; 1976; p.40-9.
17. Larsen E, Lauridsen F. Conservative treatment of patellar dislocations: influence of evident factors on the tendency to redislocation and the therapeutic result. *Clin Orthop* 1982; 171:131-6.
18. Ahmad CS, Stein BE, Matuz D, Henry JH. Immediate surgical repair of the medial patellar stabilizers for acute patellar dislocation: a review of eight cases. *Am J Sports Med* 2000; 28:804-10.
19. Arendt EA, Fithian DC, Cohen E. Current concepts of lateral patella dislocation. *Clin Sports Med* 2002; 21:499-519.
20. Boring TH, O'Donoghue MD. Acute patellar dislocation: results of immediate surgical repair. *Clin Orthop* 1978; 136:182-5.
21. Kaplan EB. Factors responsible for the stability of the knee joint. *Bull Hosp Joint Dis* 1957; 18:51-9.
22. Tuxoe JI, Teir M, Winge S, Nilsen PL. The medial patello-femoral ligament: a dissection study. *Knee Surg Sports Traumatol Arthrosc* 2002; 10:138-40.
23. Sandmeier RH, Burks RT, Bachus KN, Billings A. The effect of reconstruction of the medial patellofemoral ligament on patellar tracking. *Am Sports Med* 28: 345-349,2000.
24. Amis AA, Firer P, Mountney J, Senavongse W, Thomas NP. Anatomy and biomechanics of the medial patellofemoralligament. *Knee* 2003; 10:215-20.
25. Yamamoto RK. Arthroscopic repair of the medial retinaculum and capsule in acute patellar dislocations. *Arthroscopy* 1986; 2:125-31.
26. Nikku R, Nietosvaara Y, Kallio PE, Aalto K, Michelsson JE. Operative versus closed treatment of primary dislocation of the patella: similar 2-year results in 125 randomized patients. *Acta Orthop Scand* 1997; 68:419-23.
27. Sallay PI, Poogi J, Speer KP, Garrett WE. Acute dislocation of the patella. A correlative pathoanatomic study. *Am J Sports Med* 1996; 24:52-60.
28. Avikainen VJ, Nikku RK, Seppanen-Lehmonen TK. Adductor magnus tenodesis for patellar dislocations: technique and preliminary results. *Clin Orthop* 1993; 297:12-16.
29. Camanho GL, Viegas AC. Estudo anatômico e artroscópico do ligamento femoropatelar medial. *Acta Ortop Bras* 2003;11:145-9.
30. Ellera-Gomes JL, Marczyk LRS, César de César P, Jungblut CF. Medial Patellofemoral Ligament reconstruction with semitendinous autograft for chronic patellar instability: a follow-up study. *Arthroscopy* 2004; 20:147-51.