

## The effects of Low Level Laser Therapy on Injured Skeletal Muscle

Ana Claudia Muniz Renno<sup>1</sup>, Lívia Assis<sup>1\*</sup>, Beatriz Peres<sup>1</sup>, Natalia Camargo Rodrigues<sup>2</sup>, Roberta de Matos Brunelli<sup>2</sup>, Renata Luri Toma<sup>1</sup>, Carla Christina Medalha<sup>1</sup> and Daniel Araki Ribeiro<sup>1</sup>

<sup>1</sup>Departamento de Biociências; Universidade Federal de São Paulo; Santos - SP - Brasil. <sup>2</sup>Departamento de Fisioterapia; Centro de Ciências Biológicas e da Saúde; Universidade Federal de São Carlos; São Carlos - SP - Brasil

### ABSTRACT

The main purpose of the present study was to investigate the effects of low-level laser therapy (LLLT) used in two different fluencies on injured skeletal muscle after cryolesion by means of histopathological analysis and immunohistochemistry for COX-2. A total of sixty male Wistar rats were randomly distributed into three groups: injured animals without any treatment; 808 nm laser treated group, at 10 J/cm<sup>2</sup> and 808 nm laser treated group, at 50 J/cm<sup>2</sup>. Each group was divided into two different subgroups (n=10) on days 6 and 13 post-injury. The results showed that the animals irradiated with laser at 10 J/cm<sup>2</sup> or 50 J/cm<sup>2</sup> presented the areas with cell infiltrate and pointed out to minor and mild areas with destroyed zones compared with the control group. Also, a COX-2 downregulation was noticed in the groups exposed to laser at two fluences evaluated in this study. Significant statistically differences ( $p < 0.05$ ) were noticed to collagen deposition in the laser treated animals, with the fluence of 50 J/cm<sup>2</sup> when compared to the other groups on day 13 post-surgery. Taken together, these results suggested that laser therapy could have positive effects on muscle repair in the rats after cryolesion.

**Key words:** low level laser therapy, rat, muscle repair, COX-2

### INTRODUCTION

Muscle injuries are one of the most common injuries occurring in the sports, with an incidence varying from 10 to 55% of all the sustained injuries (Piedade et al. 2008). The healing of an injured skeletal muscle follows a fairly constant pattern divided in three phases: destruction phase (characterized by the rupture and ensuing necrosis of the myofibres and formation of a haematoma and an inflammatory cell reaction), repair phase (consisting of the phagocytosis of the necrotised tissue, regeneration of the myofibres and production of a connective tissue scar) and

remodelling phase (a period during which the maturation of the regenerated myofibres, retraction and reorganization of the scar tissue and recovery of the functional capacity of the muscle occurs) (Järvinen et al. 2007) Although muscle tissue is a dynamic tissue with an excellent capacity for repair after the injury, such a process is considered slow and some injuries might even affect muscle functioning, leading to atrophy, contracture, pain and increased likelihood of re-injury (Renno et al. 2007; Baptista et al. 2011). In this context, there is a need to develop the treatments able to accelerate muscle cell proliferation and preventing fibrosis during the healing process, which would decrease

\* Author for correspondence: acmr\_ft@yahoo.com.br

the rehabilitation time and the regenerative processes, producing a return to the previous level of function as quickly and thoroughly as possible (Markert et al. 2005).

Some physical agents have been used to treat the skeletal muscle conditions, including low-laser therapy (LLLT) (Mesquita-Ferrari et al. 2011; Baptista et al. 2011). This therapy is effective in reducing post-injury inflammatory processes, stimulating the formation of new blood vessels and accelerating soft tissue healing (Chung et al. 2010; Marchionni et al. 2011). Some studies have demonstrated that LLLT has stimulatory effects on muscle cells and skeletal muscle regeneration after an injury (Amaral et al. 2001; Baptista et al. 2011). *In-vitro* studies, evaluating the differentiation process in muscle tissues, showed increased myoblast motility resulting from the low-energy laser irradiation (Oliveira et al. 1999). Mesquita-Ferrari et al. (2011) observed that LLLT promoted a decrease in TNF- $\alpha$  mRNA and TGF- $\beta$  mRNA expressions in injured muscle in the rats, suggesting the positive influence of laser therapy on the muscle repair process. Batista et al. (2011) demonstrated that LLLT promoted an increase in collagen IV immunolabeling in skeletal muscle in the early periods of recovery.

Despite the positive effects of LLLT on tissue regeneration, the mechanisms by which such therapies act on muscle tissues is not fully understood and, for many, their use as a treatment modality is still controversial (Coombe et al. 2001). Another crucial point that needs to be clarified is the lack of a consensus in the literature regarding the best laser-irradiation parameters. The aim of this study was to investigate and to compare the effects of two difference doses of lasertherapy (10 and 50 J/cm<sup>2</sup>) on injured skeletal muscle after cryolesion by means of histopathological analysis and immunohistochemistry.

## MATERIAL AND METHODS

### Animals

Sixty Wistar male rats (weighing 300  $\pm$  20 g) were used in the study. They were maintained under controlled temperature (22  $\pm$  2°C), light-dark periods of 12 h, and with free access to water and commercial diet. All the animal handling and surgical procedures were strictly conducted

according the Guiding Principles for the Care and Use of Laboratory Animals. This study was approved by the Committee of the Federal University of São Paulo. The animals were randomly distributed into three groups: control group – injured and untreated animals; 808 nm laser treated group, at fluence of 10 J/cm<sup>2</sup> and 808 nm laser treated group, at fluence of 50 J/cm<sup>2</sup>. Each group was divided into two different subgroups (n=10) and on days 6 and 13 post-injury, the rats were sacrificed with an intraperitoneal injection of general anesthetic. The treatments started 24 h post-surgery and were performed during three and six sessions.

### Experimental design

#### *Surgery*

The animals were subjected to anesthesia with Xilazin (Syntec®, 20 mg/kg, IP) and Ketamin (Agener®, at 40 mg/kg, IP) and exposed to cryolesion of the muscles. The cryolesion consisted of two freeze-thaw cycles of the muscle *in situ*. Freezing was carried out by applying the flat end (0.4×0.4 cm) of a piece of iron, precooled in liquid nitrogen, to the surface of the proximal and distal third parts of the muscle and maintaining it in position for 10s (twice). Once the muscles had thawed, the wounds were closed with polyamide threads (6-0), and thereafter, animals were kept for several hours on a warm plate (37°C) to prevent hypothermia.

### Treatments

Treatments started 24 h post-surgery and were repeated each 48 h. It comprised a low-energy Ga-Al-As laser (Theralaser, DMC®, São Carlos equipment, SP, Brazil), 808 nm continuous wave, 0.028 cm<sup>2</sup> beam diameter, 50 mW/cm<sup>2</sup>, 10 and 50 J/cm<sup>2</sup>, 50 mW, with a irradiation time of 9 and 47s, respectively. The irradiation was performed at one point, above the area of the injury, through the punctual contact technique. On days 6 and 13 post-injury, the animals were sacrificed (with profound sedation and overdose of Ketamin and Xilazin 0.5 mL each) in order to extract their tibialis anterior muscles.

### Histopathological analysis

Muscles obtained from all the experimental and control groups were washed immediately with saline and then fixed in 10% buffered neutral formalin solution. After fixation, the muscle tissue

was processed by embedding it in paraffin. Then, the tissue was sectioned and stained with hematoxylin and eosin (HE). Histopathological evaluation was carried out under a light microscope. The analysis were performed by two independent reviewers (DAR and ACMR), who were blinded to the treatment. The qualitative analysis considered any changes at the injury site, such as presence of inflammatory process, granulation tissue, diffuse or focal myofibrillary degeneration, necrosis area or even tissues undergoing hyperplastic, metaplastic and/or dysplastic transformation (Renno et al. 2011).

### Collagen analysis

The collagen amount at the site of the injury was measured by the picosirius-polarization method (Bossini et al. 2011). The histological sections were stained by the Picosirius-polarization method were viewed under polarized light to assess the structural changes in the neofforming trabecular matrix. This method allowed a qualitative and quantitative evaluation of the stage of bone matrix organization based on the birefringence of the collagen fiber bundles after staining with Picosirius and HE.

### Immunohistochemistry

Serial longitudinal muscle sections of 4  $\mu\text{m}$  were deparaffinated in xylene and rehydrated in graded ethanol, then pretreated by microwave (Brastemp, SP, Brazil) with 10 mM citric acid buffer (pH 6.0) for three cycles of 5 min each at 850 W for antigen retrieval. The material was pre-incubated with 0.3% hydrogen peroxide in PBS for 5 min for inactivation of endogenous peroxidase, and then blocked with 5% normal goat serum in PBS solution for 10 min. The specimens were then incubated with anti-COX-2 antibody (Santa Cruz Biotechnology, USA) at a concentration of 1:400. Incubation was carried out overnight at 4°C, followed by two washes in PBS for 10 min. The sections were then incubated with biotin-conjugated secondary antibody (anti-rabbit IgG) (Vector Laboratories, Burlingame, CA, USA) at a concentration of 1:200 in PBS for 1 h. The sections were washed twice with PBS before the application of preformed avidin biotin complex conjugated to peroxidase (Vector Laboratories, Burlingame, CA, USA) for 45 min. The bound complexes were visualized by the application of a 0.05% solution of 3-3'-diaminobenzidine and

counterstained with Harris hematoxylin. For control studies of antibodies, the serial sections were treated with rabbit IgG (Vector Laboratories, Burlingame, CA, USA) at a concentration of 1:200 in place of the primary antibody. Additionally, internal positive controls were performed with each staining bath. Immunohistochemical data were evaluated by two experienced pathologists (DAR and AR) under subjective morphologic analysis as established in previous studies conducted by our group (Bruttros et al. 2009; Ribeiro et al. 2009).

### Statistical Analysis

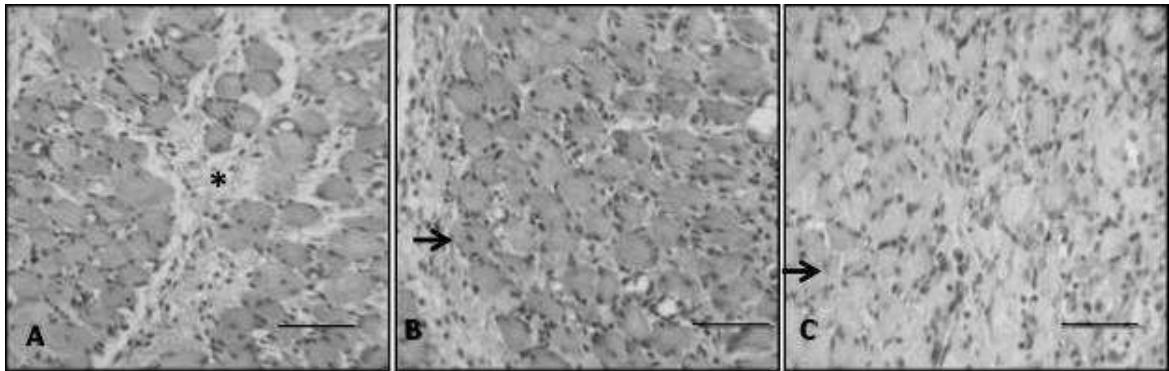
Data from picosirius analysis were evaluated using one-way ANOVA, followed by the post-hoc Student-Newman – Keuls method. Level of statistical significance was defined as  $p < 0.05$ . Statistical evaluation was carried out using GraphPad Prism 4 (GraphPad Software, San Diego CA, USA).

## RESULTS

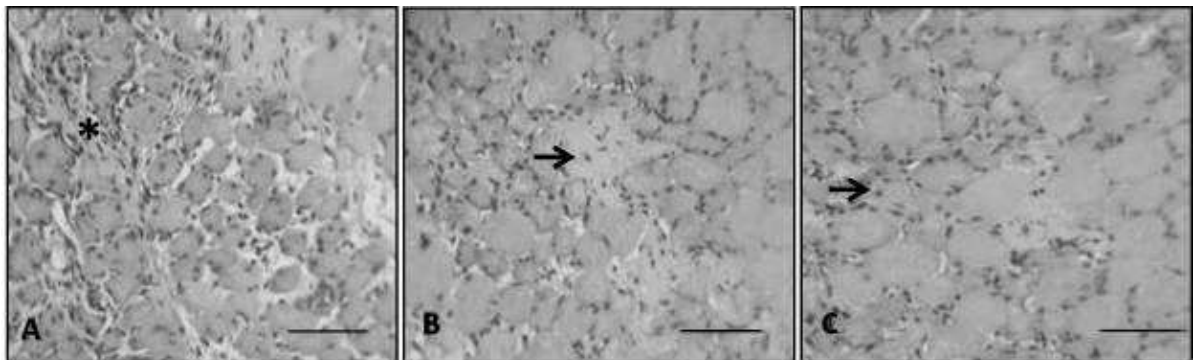
### Histopathological findings

On day 7 post-surgery, injured control rats showed severe modifications characterizing acute extensive myofibrillar degeneration, with destroyed zones, interstitial edema and the presence of important multifocal cell recruitment (Fig. 1A). The injured animals irradiated with 808 nm, at 10 J/cm<sup>2</sup> and 50 J/cm<sup>2</sup> showed similar findings as those of control animals such as the presence of interstitial edema and high cell recruitment mainly at the cryolesion injury site (Fig. 1B and Fig. 1C, respectively).

On day 13 post-surgery, samples from the injured control group showed areas with destroyed zones and presence of cell recruitment but less intense and more focal compared to the injured control rats of the day 6 post-surgery (Fig. 2A). It was also be observed that the animals irradiated with 808 nm laser at 10 J/cm<sup>2</sup> presented focal areas with cell infiltrate and pointed out mild areas with destroyed zones when compared with the control group. The animals irradiated with 808 nm at 50 J/cm<sup>2</sup> showed minor areas of destroyed zones, a lower concentration of inflammatory cell infiltrate and a better tissue organization located in the area corresponding to the cryolesion site, showing an advanced stage of healing (Fig. 2B and Fig. 2C, respectively).



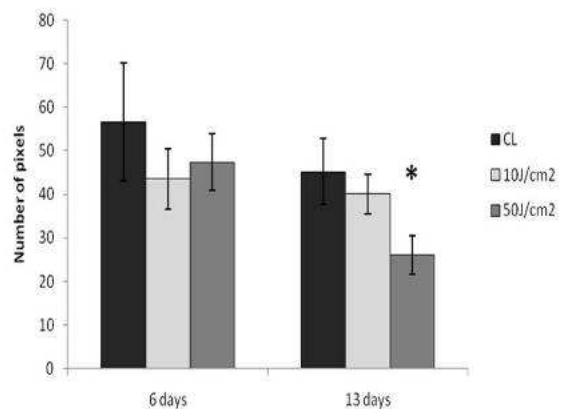
**Figure 1** - Photomicrographies in rat muscle after 6 days post-injury: (a) control group; (b) laser at 10 J/cm<sup>2</sup> (c) laser at 50 J/cm<sup>2</sup>.H.E. stain, bar = 26um. Asterisks indicate inflammatory infiltrate and granulation tissue. Arrows indicate new fiber muscle.



**Figure 2** - Photomicrographies in rat muscle after 13 days post-injury: (a) control group; (b) laser at 10 J/cm<sup>2</sup> (c) laser at 50 J/cm<sup>2</sup>. H.E.stain, bar = 26 um.

**Picrosirius analysis**

Figure 3 represents the values found in the collagen analysis. Evidently the first period evaluated had no statistical difference among the control and treated groups. Thirteen days after the surgery, the picrosirius analysis revealed that there was a statistically significant decrease in the amount of collagen in the laser treated animals, with the fluence of 50 J/cm<sup>2</sup> when compared to the other groups. No difference was found between the control group and laser treated with 10 J/cm<sup>2</sup> at this period of time.

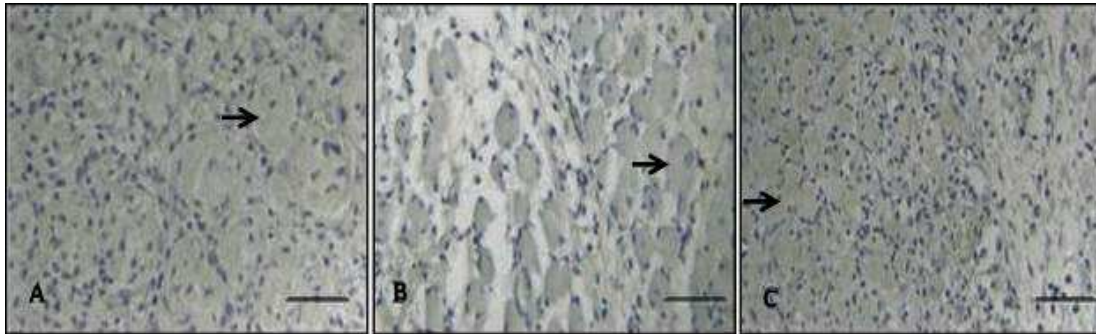


**Figure 3** - Collagen fibers expressed by number of pixels in rats suffering muscle injury and treated with laser. CL: control group. \*p<0.05 when compared to control group.

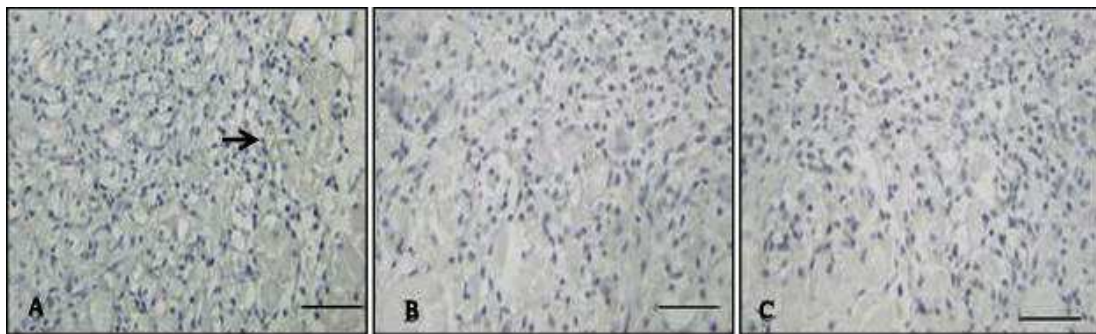
### Immunohistochemistry

COX-2 expression was detected in the cytoplasm of the inflammatory and muscular cells. Six days post-surgery, the control animals showed moderate COX-2 immunoexpression (Fig. 4A). In the laser treated animals, at both the fluencies (10 and 50 J/cm<sup>2</sup>) the same pattern of COX-2 expression was

found (Fig. 4B and 4C). At day 13 post-surgery, a less intense COX-2 expression was observed in the control group when compared to the pattern found in the control group at the first period evaluated. Nevertheless, a COX-2 downregulation was noticed to the groups exposed to laser at two fluencies evaluated in this study (Fig. 5).



**Figure 4** - Immunohistochemistry for COX-2 after 6 days post-injury: (a) control group; (b) laser at 10 J/cm<sup>2</sup> (c) laser at 50 J/cm<sup>2</sup>. Immunohistochemistry stain, bar = 26  $\mu$ m. Arrows indicate COX-2 immunoexpression.



**Figure 5** - Immunohistochemistry for COX-2 after 13 days post-injury: (a) control group; (b) laser at 10 J/cm<sup>2</sup> (c) laser at 50 J/cm<sup>2</sup>. Immunohistochemistry stain, bar = 26  $\mu$ m. Arrows indicate COX-2 immunoexpression.

## DISCUSSION

This study investigated and compared the effects of two different fluencies of 808 nm laser on muscle healing after cryolesion by means of the histopathological changes, picrossirius analysis and immunohistochemistry. Studies carried out on the histopathological examination showed that the rats submitted to cryolesion revealed acute extensive myofibrillar degeneration and an extense necrosis area. Laser therapy, mainly at the higher fluency, attenuated the pathological features induced by cryolesion in the late period evaluated in this setting. This was in agreement with Melo et al. (2011), who reported that laser therapy

decreased the extent of edema and the number of inflammatory cells and increased the amount of elastic fibers in wound healing process, which could explain the positive effect of laser on accelerating the tissue repair. Earlier study on comparing the effects of 830 nm lasertherapy and low intensity pulsed ultrasound (US) on muscle healing reported that the laser irradiated animals presented minor degenerative changes of muscle tissue when compared to control and US treated animals (Renno et al. 2007). The results demonstrated that laser irradiation did not affect collagen deposition at the earlier period evaluated. However, there was a decrease in the collagen concentration at day 13 post-surgery after

50 J/cm<sup>2</sup> laser irradiation. The effects of LLLT on collagen metabolism are still unclear (Baptista et al. 2011). Some authors have suggested that lasertherapy increases collagen synthesis (Yeh et al. 1989; Reddy et al. 1989) whereas other authors have demonstrated a decrease in collagen synthesis (Pereira et al. 2002; Marques et al. 2004). Batista et al. (2011), using the imunohistochemistry analysis, observed an increase in collagen IV labeling in the muscle cells, especially at 7 days after cryoinjury. The laser-treated group exhibited collagen IV distribution at 7 days after the injury, similar to that achieved in the nontreated animals at 14 days. The authors suggested that laser therapy could help the mechanical stability of skeletal muscle in the first days after injury. However, they found that on days 14 and 21 post-surgery, the collagen immunolabeling was similar between the groups. From the histological results it could be hypothesized that the animals treated with 808 nm laser at 50 J/cm<sup>2</sup> regained the collagen deposit at the site of the injury due to new muscle fibers.

Taking into consideration that some inflammatory mediators, such as prostaglandin and arachidonic acid products play an important role during tissue repair, it is essential to evaluate the effects of lasertherapy on cyclooxygenase-2 expression during the process of muscle repair. Cyclooxygenase is a key enzyme in the conversion of arachidonic acid to prostanoids. The expression of isoform cyclo-oxygenase-2 is relevant to many pathological processes, including inflammation, tissue repair and, ultimately, to carcinogenesis (Shibata et al. 2005). Some studies have shown that laser therapy is able to modulate the inflammatory response and to optimize tissue repair in the rats (Gál et al. 2006; Demidova-Rice et al. 2007). The imunohistochemistry findings in the present study showed no remarkable differences on COX-2 expression at the first period evaluated at two fluences analyzed. However, a COX-2 down-regulation was detected after 13 days following laser therapy, regardless fluency adopted. An earlier study conducted has revealed that COX-2 immunoexpression in muscle cells after cryolesion was lower in the rats exposed to laser therapy when compared to control group (Renno et al. 2011). Albertini et al. (2007) postulated that the expression of COX-2 mRNA decreased in the animals receiving low level laser therapy 1h after the administration of carrageenan, an inflammatory inducer. The present results were

also in agreement with those obtained by Herman and Khosla (1989), who analyzed the therapeutic effect of GaAlAs on inflammation by using 2.3 J/cm<sup>2</sup> in three sessions. Others have also demonstrated that LLLT using GaAlAs radiation exerted a time-dependent anti-inflammatory effect at an energy density of 2.5 J/cm<sup>2</sup> (Aimbire et al. 2008). Taken together, these results supported the notion that laser therapy improved muscle repair as a result of down-regulation of COX-2 after inducing muscle injury in the rats.

The methodology used in this study was highly adequate to investigate the effects of LLLT on injured muscle. The cryolesion is a common experimental model to produce injuries in muscle tissue (Baptista et al. 2011). Also, the laser wavelength and both doses used were efficient to produce stimulatory effects on muscle tissue. However, the higher fluence (50 J/cm<sup>2</sup>) seemed to produce more stimulatory effects, especially 13 days post-surgery. The GaAl-As laser used in this work was chosen based on a previous study, which found positive effects on muscle healing after this laser irradiation. It could also be possible to find a wide range of fluencies of laser irradiation used by different authors on injured muscles, making it impossible to determine an ideal protocol of treatment. Therefore, studies comparing different dosages at the same experimental model would be very important to determine the most efficient parameter to be used on the acceleration of muscle healing. It has been demonstrated that the dose of 50 J/cm<sup>2</sup> improved muscle healing (Rennó et al. 2011). Based on the need of comparing the effects of different fluencies, a lower dose (10 J/cm<sup>2</sup>) was used to verify if it could be more efficient to stimulate muscle tissue.

## CONCLUSIONS

This study revealed that LLLT had positive effects on muscle repair in the rats, mainly at the fluence of 50 J/cm<sup>2</sup>. Although further long-term studies and clinical trials would be required, the findings of this study pointed to a promising use of these therapeutic modalities for tissue repair.

## ACKNOWLEDGMENTS

We acknowledge CAPES, CNPQ and FAPESP for financial support.

## REFERENCES

- Aimbire F, Ligeiro de Oliveira AP, Albertini R, Corrêa JC, Ladeira de Campos CB, Lyon JP, et al. Low level laser therapy (LLLT) decreases pulmonary microvascular leakage, neutrophil influx and IL-1 $\beta$  levels in airway and lung from rat subjected to LPS-induced inflammation. *Inflammation*. 2008; 31 (4), 189-197.
- Albertini R, Aimbire F, Villaverde AB, Silva JA Jr, Costa MS. COX-2 mRNA expression decreases in the subplantar muscle of rat paw subjected to carrageenan-induced inflammation after low level laser therapy. *Inflamm Res*. 2007; 56(6):228-229.
- Amaral CA, Parizzotto NA. Dose-dependency of low energy HeNe Laser effect in regeneration of skeletal muscle in mice. *Lasers Med Sci*. 2001; 16: 44-51.
- Baptista J, Martins MD, Pavesi VC, Bussadori SK, Fernandes KP, Pinto Júnior Ddos S, et al. Influence of laser photobiomodulation on collagen IV during skeletal muscle tissue remodeling after injury in rats. *Photomed Laser Surg*. 2011; 29(1): 11-17.
- Bossini PS, Rennó AC, Ribeiro DA, Fangel R, Peitl O, Zanotto ED, et al. Biosilicate® and low-level laser therapy improve bone repair in osteoporotic rats. *J Tissue Eng Regen Med*. 2011; 5(3): 229-237.
- Buttros JB, Bergamaschi CT, Ribeiro DA, Fracalossi AC, Campos RR. Cardioprotective actions of ascorbic acid during isoproterenol-induced acute myocardial infarction in rats. *Pharmacology*. 2009; 84: 29-37.
- Chung TY, Peplow PV, Baxter GD. Laser photobiomodulation of wound healing in diabetic and non-diabetic mice: effects in splinted and unsplinted wounds. *Photomed Laser Surg*. 2010; 28(2): 251-261.
- Coombe AR, Ho CT, Darendeliler MA, Hunter N, Philips JR, Chapple CC, et al. The effects of low level laser irradiation on osteoblastic cells. *Clin Orthod Res*. 2001; 4: 3-14.
- Demidova-Rice TN, Salomatina EV, Yaroslavsky AN, Herman IM, Hamblin MR. Low-level light stimulates excisional wound healing in mice. *Lasers Surg Med*. 2007; 39(9):706-715.
- Gál P, Vidinský B, Toporcer T, Mokry M, Mozes S, Longauer F, Sabo J. Histological assessment of the effect of laser irradiation on skin wound healing in rats. *Photomed Laser Surg*. 2006; 24(4):480-488.
- Herman JH, Khosla RC. Nd:YAG laser modulation of synovial tissue metabolism. *Clin Exp Rheumatol*. 1989; 7(5): 505-512.
- Järvinen TA, Järvinen TL, Kääriäinen M, Aärimaa V, Vaitinen S, Kalimo H, et al. Muscle injuries: optimising recovery. *Best Pract Res Clin Rheumatol*. 2007; 21(2): 317-331.
- Marchionni AM, Medrado AP, Silva TM, Fracassi LD, Pinheiro AL, Reis SR. Influence of laser ( $\lambda$ 670 nm) and dexamethasone on the chronology of cutaneous repair. *Photomed Laser Surg*. 2011; 28(5):639-646.
- Markert CD, Merrick MA, Kirby TE, Devor ST. Nonthermal ultrasound and exercise in skeletal muscle regeneration. *Arch Phys Med Rehabil*. 2005; 86(7): 1304-1310.
- Marques MM, Pereira AN, Fujihara NA, Nogueira FN, Eduardo CP. Effect of low-power laser irradiation on protein synthesis and ultrastructure of human gingival fibroblasts. *Lasers Surg Med*. 2004; 34(3): 260-265.
- Melo VA, Anjos DC, Albuquerque Júnior R, Melo DB, Carvalho FU. Effect of low level laser on sutured wound healing in rats. *Acta Cir Bras*. 2011; 26(2): 129-134.
- Mesquita-Ferrari RA, Martins MD, Silva JA Jr, da Silva TD, Piovesan RF, Pavesi VC, et al. Effects of low-level laser therapy on expression of TNF- $\alpha$  and TGF- $\beta$  in skeletal muscle during the repair process. *Lasers Med Sci*. 2011; 26(3): 335-340.
- Oliveira NM, Parizzotto NA, Salvini TF. GaAs (904 nm) laser radiation does not affect muscle regeneration in mouse skeletal muscle. *Lasers Surg Med*. 1999; 25: 13-21.
- Pereira AN, Eduardo Cde P, Matson E, Marques MM. Effect of low-power laser irradiation on cell growth and procollagen synthesis of cultured fibroblasts. *Lasers Surg Med*. 2002; 31(4): 263-267.
- Piedade MC, Galhardo MS, Battlehner CN, Ferreira MA, Caldini EG, de Toledo OM. Effect of ultrasound therapy on the repair of gastrocnemius muscle injury in rats. *Ultrasonics*. 2008; 48(5): 403-411.
- Reddy GK, Stehno-Bittel L, Enwemeka CS. Laser photostimulation of collagen production in healing rabbit achilles tendons. *Lasers Surg Med*. 1998; 22(5): 281-287.
- Renno AC, McDonnell A, Laakso L, Parizoto NA. The effects of laser irradiation on osteoblast and osteosarcoma cell proliferation and differentiation in vitro. *Photomed Laser Surg*. 2007; 25, 275-280.
- Rennó AC, Toma RL, Feitosa SM, Fernandes K, Bossini PS, de Oliveira P, et al. Comparative effects of low-intensity pulsed ultrasound and low-level laser therapy on injured skeletal muscle. *Photomed Laser Surg*. 2011; 29(1):5-10.
- Ribeiro DA, Buttros JB, Oshima CT, Bergamaschi CT, Campos RR. Ascorbic acid prevents acute myocardial infarction induced by isoproterenol in rats: role of inducible nitric oxide synthase production. *J Mol Histol*. 2009; 40: 99-105.
- Shibata R, Sato K, Pimentel DR, Takemura Y, Kihara S, Ohashi K, et al. Adiponectin protects against myocardial ischemia-reperfusion injury through AMPK- and COX-2-dependent mechanisms. *Nat Med*. 2005; 11(10):1096-1103.
- Yeh KY, Yeh M, Holt PR. Induction of rat jejunal epithelial cell expression of sucrase-isomaltase by glucocorticoids in primary cell culture and in vivo. *Biol Cell*. 1989; 65(2):1391-50.

Received: October 05, 2012;  
Accepted: August 12, 2013.