

Retrospective review and systematic study of mammary tumors in dogs and characteristics of the extracellular matrix

Estudo retrospectivo-sistemático da matriz extracelular de tumores mamários caninos

Ana Maria Cristina Rabello Pinto da Fonseca MARTINS¹; Elia TAMASO²;
José Luiz GUERRA²

CORRESPONDENCE TO:
ANA MARIA CRISTINA RABELLO PINTO DA
FONSECA MARTINS
Laboratório de Anatomia Patológica do Instituto
Biológico
Avenida Conselheiro Rodrigues Alves, 1252
04014-002 – São Paulo – SP
e-mail: crisfm@biologico.br

1- Laboratório de Anatomia Patológica do
Instituto Biológico – SP

2- Departamento de Patologia da Faculdade
de Medicina Veterinária e Zootecnia da
Universidade de São Paulo – SP

SUMMARY

The aim of the present study was to perform a retrospective review, from 1932 to 1999, in order to establish the number of cases of mammary tumors in dogs in the records at the Pathology Department of Faculdade de Medicina Veterinária – USP, as well as the presence of desmoplasia and cartilaginous and bone metaplasia in 578 of these tumors. Among the 537 malignant tumors, 13.05% were simple tubular adenocarcinomas, 3.91% were complex tubular adenocarcinomas, 7.26% simple papillary adenocarcinomas, 4.28% complex papillary adenocarcinomas, 23.27% simple papillary cystadenocarcinomas, 8.37% complex papillary cystadenocarcinomas, 16.38% simple solid adenocarcinomas, 6.70% complex solid adenocarcinomas, 2.04% simple spindle cell carcinomas, 1.11% simple spindle cell carcinomas, 2.79% mucinous carcinomas, 8.19% anaplastic carcinomas, 0.93% squamous carcinomas, 1.30% fibrosarcomas, 0.18% chondrosarcoma, 0.18% osteosarcoma and among the 41 benign tumors, 51.21% were adenoma, 12.19% papillary cystadenoma, 7.31% papilloma, 4.87% cystic fibroadenoma and 24.39% were fibroadenoma. Both desmoplasia and metaplasia were frequent findings in benign and malignant neoplasms, but they were more frequent among complex tubular adenocarcinomas: 38% presented desmoplasia, 57% cartilaginous metaplasia and 28% bone metaplasia. Among the benign neoplasms, adenoma presented the more frequency: 14% presented desmoplasia, 29% cartilaginous metaplasia and 24% bone metaplasia. Results of this study emphasize the complexity of the inter-relationship between the macromolecules in the extracellular matrix and tumoral cells.

KEY-WORDS: Mammary neoplasms. Dogs. Pathology. Extracellular matrix. Frequency.

INTRODUCTION

Mammary tumors are frequent in dogs, and they correspond to 25% of the neoplasms in this species⁸. The variety of histological types has produced conflicting concepts related to classification and histogenesis, what resulted in a variety of taxonomic systems.

Mammary neoplasms in dogs that are similar to those in humans^{16,20,22} are of special concern to the oncology researchers because they may be used as biological models in the search for more precocious diagnoses, more exact prognoses and a more efficient therapeutic procedures.

In the present trial, 1,371 cases of alterations in the mammary glands of dogs were analyzed and 578 specimens were studied. These cases are part of the records in FMVZ / USP from 1936, when the school was founded, to 1999. Classification used was that of the World Health Organization (WHO), adapted by Hampe and Misdorp⁷, which is based on descriptive morphology and histogenesis. Neoplasms were

described as complex when secretory and myoepithelial cells were altered. They were described as simple when only one of the cell types was modified. Both simple and complex carcinomas were classified according to the level of differentiation of the tubules. Tubular adenocarcinomas are placed at one of the extremes, and anaplastic carcinomas, at the other.

Mammary neoplasms frequently present abundant extracellular matrix (ECM), called desmoplasia⁸. In dogs, it is common to observe cartilaginous and bone metaplasia⁸.

The objective of the present trial was to reclassify benign and malignant neoplasms in dogs, according to the WHO guidelines, in order to determine the number of cases as well as the frequency of desmoplasia and cartilaginous and bone metaplasia in the specimens analyzed.

MATERIAL AND METHOD

Blocks and slides with benign and malignant tumors of dogs were used in this trial. A total of 578 cases from the

records in the Animal Pathology Sector at the Pathology Department in Faculdade de Medicina Veterinária e Zootecnia / USP, from 1936 to 1999 were analyzed. Cuts were obtained from the blocks and were 5 mm thick. They were stained by hematoxylin and eosin for the identification of the histological types.

Table 1

Number of cases of the several types of mammary gland malignant neoplasms in dogs studied in the records of the Pathology Department at FMVZ-USP from March, 1936 to October, 1999, according to WHO classification.

No. of cases	Type	%
70	Simple tubular adenocarcinomas	13.05
21	Complex tubular adenocarcinomas	3.91
39	Simple papillary adenocarcinomas	7.26
23	Complex papillary adenocarcinomas	4.28
125	Simple papillary cystadenocarcinomas	23.27
45	Complex papillary cystadenocarcinomas	8.37
88	Simple solid adenocarcinomas	16.38
36	Complex solid adenocarcinomas	6.70
11	Simple spindle cell carcinomas	2.04
6	Complex spindle cell carcinomas	1.11
15	Mucinous carcinomas	2.79
44	Anaplastic carcinomas	8.19
5	Squamous carcinomas	0.93
7	Fibrosarcomas	1.30
1	Chondrosarcoma	0.18
1	Osteosarcoma	0.18

Total: 537 92.90 % were malignant

RESULTS

From de microscopic analysis of 1,371 cases of alterations in the mammary gland, according to the morphological characteristics of benign and malignant tumors, from the records in the Animal Pathology Sector at the Pathology Department in Faculdade de Medicina Veterinária e Zootecnia / USP, from 1936 to 1999, the following number of cases was found: 1,249 cases malignant neoplasms, 111 benign neoplasms and 11 cases of mammary duct hyperplasia. In the analysis of the malignant neoplasms, according to their histogenesis, 1,227 carcinoma cases and 22 sarcoma cases were found.

For the reclassification of each case, according to WHO, 578 specimens were used, for many slides were deteriorated and / or the material in the blocks was not representative.

The results of the study are presented in tab. 1, 2, 3 and 4 and fig., as follows:

Table 2

Histological types of benign neoplasms in the mammary gland of dogs in the records of the Pathology Department at FMVZ-USP from March, 1936 to October, 1999, according to WHO classification.

No. of cases	Types	%
21	Adenoma	51.21
5	Papillary cystadenoma	12.19
3	Papilloma	7.31
2	Cystic fibroadenoma	4.87
10	Fibroadenoma	24.39

Total: 41 7.09% were benign

Table 3

Percentile analysis of desmoplasias, cartilaginous and bone metaplasias observed in mammary carcinomas in dogs, found in the Pathology Department at FMVZ-USP from March, 1936 to October, 1999.

Type	Desmoplasia	Cartilaginous Metaplasia	Bone Metaplasia
Tubular adenocarcinoma S	32 %	22 %	9 %
Tubular adenocarcinoma C	38 %	57 %	28 %
Papillary adenocarcinoma S	23 %	33 %	10 %
Papillary adenocarcinoma C	22 %	26 %	9 %
Papillary cystadenocarcinoma S	25 %	33 %	19 %
Papillary cystadenocarcinoma C	19 %	36 %	7 %
Solid adenocarcinoma S	16 %	14 %	4 %
Solid adenocarcinoma C	17 %	28 %	3 %
Spindle cells S	27 %	36 %	18 %
Spindle cells C	17 %	17 %	0 %
Mucinous carcinoma	18 %	9 %	0 %
Anaplastic carcinoma	14 %	23 %	15 %
Squamous carcinoma	25 %	25 %	25 %

S= simple C= complex

Table 4

Percentile analysis of desmoplasias, cartilaginous and bone metaplasias observed in mammary benign neoplasms in dogs, found in the Pathology Department at FMVZ-USP from March, 1936 to October, 1999.

Types	Desmoplasia	Cartilaginous metaplasia	Bone Metaplasia
Cistadenoma	0 %	20 %	20 %
Adenoma	14 %	29 %	24 %
Papillary adenoma	0 %	33 %	0 %
Fibroadenoma	10 %	20 %	10 %
Cystic papillary fibroadenoma	0 %	50 %	0 %

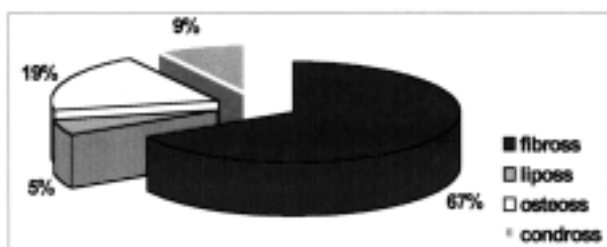


Figure 1

Percentile distribution of the different types of mammary sarcoma in dogs found in the records of the Pathology Department at FMVZ-USP from March, 1936 to October, 1999.

DISCUSSION AND CONCLUSIONS

Based on the results, it is observed that the frequency of these kind of tumors in dogs in the records of the Pathology Department in the Faculdade de Medicina Veterinária e Zootecnia - USP, from 1936 to 1999 is variable, as well as the expression of the extracellular matrix in 578 these different histological types of carcinomas and benign neoplasms. The percentile of benign tumors (7.09 %) is novel information, for it was not found in the specialized literature studied^{11,12}. The justification may be attributed to the fact that the authors, in general, have used a small universe for the determination of the number of cases. Non-neoplastic proliferative lesions have been observed in only 1 % of the 1,371 cases studied, information that was not found in the literature. In relation to histogenesis, 98% of 1,249 malignant tumors were carcinomas. The other 2 % were mesenchymal tumors in the tissue of the mammary gland: osteosarcomas (19%), chondrosarcomas (9%), fibrosarcomas (67%) and liposarcoma (5%). Among the 537 different histological types of malign neoplasms reclassified, however, 7 cases were fibrosarcoma (1.30%), 1 chondrosarcoma (0.18%) and 1 osteosarcoma (0.18%) In relation to this, it may be inferred that myoepithelial cells are responsible for chondroblast and osteoblast tumors, and may also be transformed in chondrosarcomas and osteosarcomas. Fibroblasts and lipoblasts, on the other hand, when undergoing malignant transformation would generate, respectively, fibrosarcomas

and liposarcomas. In the series of observations performed in the present trial, carcinosarcomas were not considered, for the origin of the altered cells is myoepithelial and not fibroblastic^{5,17}. Simple and complex mammary carcinomas were present in 65% and 35 % of the cases, respectively.

Mammary neoplasms frequently present an abundant amount of extracellular matrix, which is called desmoplasia. It could be noted, from the analysis of carcinomas and benign neoplasms in relation to the presence of desmoplasia, that complex tubular adenocarcinoma presented it more frequently (38%). The lower frequency was found in anaplastic carcinoma (14%). Desmoplasia is increased in mammary carcinomas probably as a result of the secretion, by the tumoral cells, of factors known as mesenchymal cell biosynthetic activity modulators, such as TGF β , TGF α , PDGF, FGF^{23,18,10}; due to the secretion of a 68 kDa polypeptide which increases collagen synthesis in other cells, including fibroblasts⁴ and other biosynthesis products from tumoral cells which modulate the renewal of ECM macromolecules responsible for the regulation of the synthesis or degradation, or both. This altered matrix, in its turn, may influence several tumoral functions such as morphology^{13,14,15} differentiation, binding, metastasis potential and biosynthesis activity⁹. This altered matrix would act on myoepithelial cells, which, in their turn, would have a paracrinous effect on glandular epithelium, regulating tumor progression and accumulating, more than degrading, the ECM (they present low expression of proteinases and high expression of proteinase inhibitors). These cells also contribute for the synthesis of basal membrane, inhibit angiogenesis and express a great amount of maspim, a tumor suppresser²¹. In mammary neoplasms, desmoplasia may occur due to the action of tumoral and myoepithelial cells. According to²¹, myoepithelial cells, besides their contractile function and their role in the synthesis and remodeling of basal membrane, may also regulate growth, differentiation and morphogenesis of neighboring, epithelial and mesenchymal cells, for they secrete growth factors and cytokines such as TGF β , TGF α and interleukin⁶. With the increase of gene instability, from tubular adenocarcinoma to anaplastic carcinoma, epithelial cells would secrete a larger quantity of these modulators for

matricial cells, which may cross the physical barrier presented by basal membrane, leading to the loss in myoepithelial cells suppressing characteristics or even to their transformation. In anaplastic carcinomas, where there is a low frequency of desmoplasia, these two cell types are so phenotypically altered that the paracrine effect of myoepithelial cells over the other cells would not restrain proliferation, invasion and metastatization of the transformed epithelial cells any longer.

In relation to the presence of cartilaginous and bone metaplasia, it was noted that tubular adenocarcinoma was the type of tumor that presented them most frequently: 57 % of cartilaginous metaplasia and 28 % of bone metaplasia.

Among benign tumors, cystic papillary fibroadenoma presented the major frequency of cartilaginous metaplasia (50%). No bone metaplasia was observed in this kind of tumor. The higher frequency of bone metaplasia among benign tumors was found in the adenomas (13.05%). In 1974, Bomhard and Sanderselben⁶, in a ultrastructural study, demonstrated the presence of chondroitin sulfate in myoepithelial cells and Araújo et al.^{1,2,3}, demonstrated that the distribution of collagen type II and type IX in the ECM with cartilaginous metaplasia was similar to that of normal hyaline cartilage and to collagen type IX, detected in mammary myoepithelial cells when they begin to proliferate near the basal membrane. In these initial

stages, myoepithelial cells do not present characteristics of chondrocytes or expressed collagen type II and XI. According to Araújo et al.¹, collagen type IX precociously detected only in the cytoplasm of myoepithelial cells and not in the extracellular matrix, may have an important role in the initial stages of chondrometaplasia as a proliferation promoter. It may be, thus, used as an excellent cell marker for progenitor cells in myoepithelial cells related to chondrometaplasia. The expression of collagen XI enables the expression of collagen II and IX. Besides, in order to clarify the suppressing action of myoepithelial cells, it is known that the phenotypic expression of tumor suppresser genes may be due to the high homology between complementary DNA and aminoacid sequence of the suppresser gene and that of collagen type II and IX specific of chondrocytes. Myoepithelial cells express TGF β and other members of the TGF β family such as bone morphogenetic proteins, including osteogenin and osteogenic proteins know as bone / cartilage inducing factors¹⁹.

It may be inferred from information found in the specialized literature, that the expected higher frequency of chondro and osteometaplasia is related to complex type tumors, benign and more differentiated, for the increase in gene instability in neoplastic cells during the progression of tumors and their influence on myoepithelial cells would make them lose their suppressing activity.

RESUMO

A finalidade do presente trabalho foi efetuar um estudo retrospectivo, de 1932 à 1999, afim de se estabelecer a casuística desses tumores nos arquivos do Departamento de Patologia da Faculdade de Medicina Veterinária – USP, bem como a frequência de desmoplasia, metaplasia cartilaginosa e óssea em 578 desses tumores. Entre os 537 tumores malignos, 13.05% foram adenocarcinomas tubulares simples, 3.91% foram adenocarcinomas tubulares compostos, 7.26% adenocarcinomas papilíferos simples, 4.28% adenocarcinomas papilíferos compostos, 23.27% cistoadenocarcinomas papilíferos simples, 8.37% cistoadenocarcinomas papilíferos compostos, 16.38% adenocarcinomas sólidos simples, 6.70% adenocarcinomas sólidos compostos, 2.04% carcinomas de células espinhosas simples, 1.11% carcinomas de células espinhosas compostos, 2.79% carcinomas mucinosos, 8.19% carcinomas anaplásicos, 0.93% carcinomas escamosos, 1.30% fibrossarcomas, 0.18% condrossarcoma, 0.18% osteossarcoma e entre os 41 tumores benignos, 51.21% foram adenomas, 12.19% cistadenomas papilíferos, 7.31% papilomas, 4.87% fibroadenomas e 24.39% foram fibroadenomas. Tanto a desmoplasia como a metaplasia foi um achado freqüente nas neoplasias benignas e malignas, mas foram mais freqüentes entre os adenocarcinomas tubulares compostos: 38% apresentaram desmoplasia, 57% metaplasia cartilaginosa e 28% metaplasia óssea. Entre as neoplasias benignas, adenoma apresentou a maior frequência: 14% com desmoplasia, 29% com metaplasia cartilaginosa e 24% com metaplasia óssea. Os resultados deste estudo enfatizam a complexidade da inter-relação entre as macromoléculas da matriz extracelular e as células tumorais.

PALAVRAS-CHAVE: Neoplasias mamárias. Cães. Patologia. Matriz extracelular. Frequência.

REFERENCES

1. ARAI, K.; UEHARA, K.; NAGAI, Y. Expression of type II and XI collagens in canine mammary complex tumors and demonstration of collagen production of tumor cells in collagen gel culture. **Japanese Journal of Cancer Research**, v. 80, n.9, p. 840–847, 1989.
2. ARAI, K.; UEHARA, K.; NAGAI, Y. Cartilaginous types of collagen expression in complex tumour (pleomorphic adenoma); in vivo and in vitro studies. **Annals of the New York Academy of Sciences**, v. 580, p. 586-588, 1990.
3. ARAI, K.; UEHARA, K.; NAGAI, Y. Simultaneous expression of type IX collagen and inhibit – related antigen in proliferative myoepithelial cells with pleomorphic adenoma of canine mammary glands. **Japanese Journal of Cancer Research**, v. 86, n.6, p. 577–584, 1995.
4. BANO, M.; SALOMON, D. S.; KIDWELL, W. R. Purification of a mammary derived growth factor from human milk and human mammary tumors. **Biological Chemistry**, v. 260, n.9, p. 5745-5752, 1985.

MARTINS, A.M.C.R.P.F.; TAMASO, E.; GUERRA, J.L. Retrospective review and systematic study of mammary tumors in dogs and characteristics of the extracellular matrix **Braz. J. vet. Res. anim. Sci.**, São Paulo, v.39, n.1, p. 38-42, 2002.

5. BOMHARD, D. E.; SANDERSL, J. V. Ultrastructure of mixed mammary-gland tumors in bitches. I. Incidence of myoepithelial cells in myxoid areas. **Virchows Archiv A. Pathological Anatomy and Histology**, v. 359, n. 1, p. 87-96, 1973.
6. BOMHARD, D. E.; SANDERSL, J. V. Ultrastructure of mixed mammary-gland tumours in bitches. II. Incidence of myoepithelial cells in chondroid areas. **Virchows Archiv A. Pathological Anatomy and Histology**, v. 362, n. 2, p. 157-167, 1974.
7. HAMPE, J. F.; MISDORP, W. Tumors and dysplasias of the mammary gland. **Bulletin of the World Health Organization**, v. 50, n. 1-2, p. 111-133, 1974.
8. JONES, T. C.; HUNT, R.D. ; KING, N.W.- **Veterinary pathology**. 6. ed. Philadelphia:Lippincott Williams & Wilkins, 1997, pg 89, 1192-1996
9. KLEINMAN, H. K.; CANNON, F. B.; LAURIE, G. W.; HASSELL, J. R.; AUMAILLEY, M.; TERRANOVA, V. P.; MARTIN, G. R.; DUBOIS-DALCQ. Biological activities of laminin. **Journal of Cellular Biochemistry**, v. 27, n.4, p. 317-325, 1985.
10. MARTINEZ-HERNANDEZ, A. The extracellular matrix and neoplasia. **Laboratory Investigation**, v. 58, n. 6, p. 609-612, 1988.
11. MOULTON, J. E.; ROSENBLATT, L. S.; GOLDMAN, M. Mammary tumours in a colony of beagle dogs. **Veterinary Pathology**, v. 23, n. 6, p. 741-749, 1986.
12. NERURKAR, V. R.; CHITALE, A. R.; JANAPURKAR, B. V.; NAIK, S. N.; LALITHA, V. S. Comparative pathology of canine mammary tumors. **Journal of Comparative Pathology**, v. 101, n. 4, p. 389-397, 1989.
13. NÖEL, A.; CALLÉ, A.; EMONARD, H.; NUSGEN, B.; FOIDART, J. M.; LAPIERE, C. M. Antagonist effects of laminine and fibronectin in cell – to – cell and cell – to –matrix in MCF – 7 cultures. **In Vitro Cellular and Developmental Biology**, v. 25, n. 5, p. 373-379, 1988.
14. NÖEL, A.; MUNAUT, C.; NUSGENS, B.; FOIDART, J. M.; LAPIERE, C. M. Different mechanisms of extracellular matrix remodeling by fibroblasts in response to human mammary neoplastic-cells. **Invasion & Metastasis**, v. 13, n. 2, p.72-81, 1993.
15. NÖEL, A.; MUNAUT, C.; NUSGENS, B.; FOIDART, J. M.; LAPIERE, C. M. The stimulation of fibroblasts collagen-synthesis by neoplastic cells is modulated by the extracellular-matrix. **Matrix**, v.12, n. 3, p. 213-220, 1992.
16. PIERREPOINT, C. G. Possible benefits to veterinary medicine of considering the dog as a model for human cancer. **Journal of Small Animal Practice** , v. 26, n.1, p. 43-47, 1985.
17. PULLEY , L. T. Ultrastructural and histochemical demonstration of myoepithelium in complex tumor of the canine mammary gland. **American Journal of Veterinary Research**, v. 34, n. 12, p.1513-1522, 1973.
18. ROSS, R. ; RAINES, E. W.; BOWEN–POPE, D. F. The biology of platlets - derived growth factor. **Cell** , v. 46, n. 2, p 155–169, 1986.
19. SAMPATH, T. H.; COUGHLIN, J. E.; WHETSONE, R. M.; BANACH, D.; CORBETT, C.; RIDGE, R. J.; OEZAYNAK, E.; OPPERMANN, H; RUEGER, D. C. Bovine osteogenic proteins is composed of dimers of OP- 1 and BMP –2A , two members of the transforming growth factor –beta super-family. **Journal of Biological Biochemistry**, v. 265, n. 22, p. 1198-1205, 1990.
20. SCHNEIDER, R.. Comparison of age, sex and incidence rater in human and canine breast cancer. **Cancer**, v. 26, n. 2, p. 419-426, 1970.
21. STERNLICH, M. D.; BARSKY, S. H. The myoepithelial defense: a host defense against cancer. **Medical Hypotheses**, v. 48, n.1, p. 37–46, 1997.
22. STRANDBERG, J. D.; GOODMAN, D. G. Animal mode of human disease. Breast cancer. **American Journal of Pathology**, v .75, n. 1, p. 225-28, 1974.
23. VARGA, J.; ROSENBLOOM, J.; JIMENEZ, S. A. Transforming growth factor b (TGFb) causes a persistent increase in steady state amounts of type I and type III collagen and fibronectin mRNAs in normal human dermal fibroblasts. **Biochemistry Journal**, v. 247, p. 597-604, 1987.

Received: 13/08/2001
Accepted: 31/01/2002