

# Early transconjunctival needling revision with 5-fluorouracil *versus* medical treatment in encapsulated blebs: a 12-month prospective study

Ricardo Suzuki, Remo Susanna-Jr

Faculdade de Medicina da Universidade de São Paulo, São Paulo/SP, Brazil.

**OBJECTIVE:** To compare the efficacy of transconjunctival needling revision with 5-fluorouracil versus medical treatment in glaucomatous eyes with uncontrolled intraocular pressure due to encapsulated bleb after trabeculectomy.

**METHODS:** Prospective, randomized, interventional study. A total of 40 eyes in 39 patients with elevated intraocular pressure and encapsulated blebs diagnosed at a maximum five months after primary trabeculectomy with mitomycin C were included. The eyes were randomized to either transconjunctival needling revision with 5-fluorouracil or medical treatment (hypotensive eyedrops). A maximum of two transconjunctival needling revisions per patient was allowed in the needling arm. All patients underwent follow-up for 12 months. Successful treatment was defined as an intraocular pressure  $\leq$  18 mmHg and a 20% reduction from baseline at the final follow-up. Clinicaltrials.gov: NCT01887223.

**RESULTS:** Mean intraocular pressure at the final 12-month follow-up was lower in the transconjunctival needling revision group compared to the medical treatment group. Similar numbers of eyes reached the criteria for treatment success in both the transconjunctival needling revision group and the medical treatment group.

**CONCLUSIONS:** Despite similar success rates in eyes randomized to transconjunctival needling revision with 5-fluorouracil compared to eyes receiving medical treatment, there was a significantly lower mean intraocular pressure at 12 months after transconjunctival needling revision.

**KEYWORDS:** Needling; Medical Treatment; Glaucoma; Encapsulated bleb; Revision; 5-Fluorouracil.

Suzuki R, Susanna-Jr R. Early transconjunctival needling revision with 5-fluorouracil *versus* medical treatment in encapsulated blebs: a 12-month prospective study. Clinics. 2013;68(10):1376-1379.

Received for publication on April 26, 2013; First review completed on April 26, 2013; Accepted for publication on July 10, 2013

E-mail: risuzukioft@hotmail.com

Tel.: 55 11 5181-1730

## INTRODUCTION

To avoid the initiation or progression of visual field defects, the reduction of intraocular pressure (IOP) is the aim of treatment for all glaucoma patients. Surgical treatment is the next step after initial medical treatment (MT) failure. Trabeculectomy is still the gold standard surgery for many specialists (1-5), and proper post-operative management is essential for the achievement of success during the follow-up period. The identification and prompt management of the early aspects of bleb failure are paramount for reducing the rate of ultimate failure of the filtering procedure (6).

Scarring under or over the scleral flap in the subconjunctival space appears to be the most common event leading to filtering failure (7,8). Scar tissue formation over the scleral flap in the subconjunctival space or encapsulated bleb (Tenon's capsule cyst) formation may occur at any point after the initial surgery. Some authors have suggested encapsulation rates ranging from 13.7% to 29% after trabeculectomy (9-11). Transconjunctival needling revision (TNR), which removes part of the fibroses with a minimally invasive technique and restores filtration, is one treatment option (6,12). The use of antifibrotic agents, such as 5-fluorouracil (5-FU) (1,5,6,12) or mitomycin C (MMC) (5), as adjunctives is suggested to increase the procedural success rate. Conversely, several authors have proposed MT with topical hypotensive medication as a successful treatment in patients with encapsulated blebs (13-15).

Several studies (1,5,12,16-18) have reported different success rates and some mixed criteria regarding successful target pressure, bleb morphological features, time of needling procedure, whether single or multiple procedures were performed and whether antifibrotic agents were used.

**Copyright** © 2013 CLINICS – This is an Open Access article distributed under the terms of the Creative Commons Attribution Non-Commercial License (<http://creativecommons.org/licenses/by-nc/3.0/>) which permits unrestricted non-commercial use, distribution, and reproduction in any medium, provided the original work is properly cited.

No potential conflict of interest was reported.

**DOI:** 10.6061/clinics/2013(10)14



The purpose of this study was to evaluate the short-term efficacy of early TNR with 5-FU and to compare its outcomes to MT in eyes with encapsulated blebs and uncontrolled IOP after trabeculectomy.

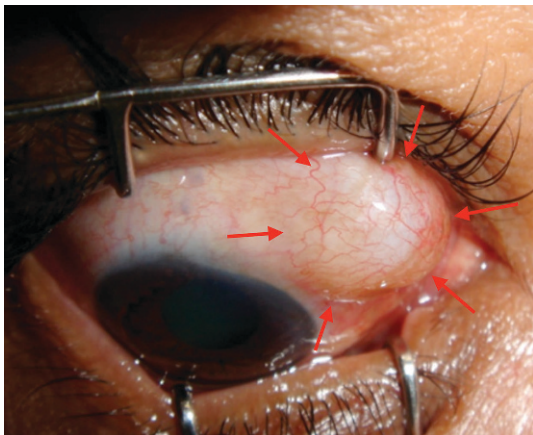
## MATERIALS AND METHODS

We conducted a prospective, randomized interventional study on 40 eyes in 39 patients with encapsulated blebs developed within five months or less after primary trabeculectomy with MMC and IOP  $\geq 20$  mmHg at the Hospital das Clínicas of the University of São Paulo, Brazil. Data were collected from May 2010 to June 2011. None of the eyes examined in this study received ocular hypotensive agents after the first surgery. An encapsulated bleb was defined as a localized, dome-shaped bleb surrounded by a fibrous tissue called the “ring of steel” (figure 1). Patients were randomized in two groups: TNR with 5-FU and MT. Only one surgeon (RS) performed TNRs. A maximum of two TNRs were allowed.

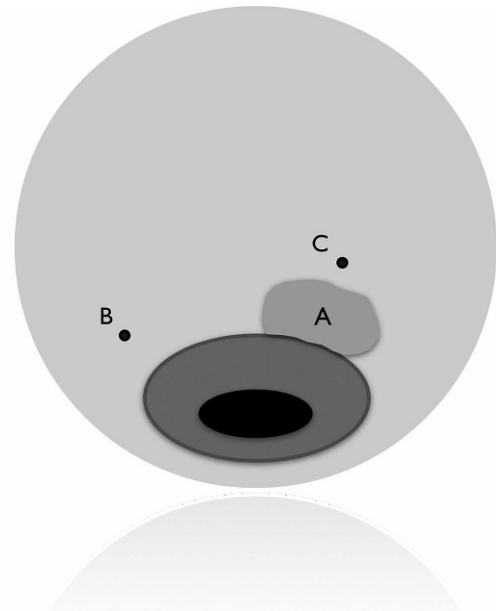
The study protocol was approved by the Ethics Committee of the Hospital das Clínicas of the University of São Paulo, Brazil. After written informed consent was given and signed, the TNR was performed. Topical anesthetic (tetracaine 0.5%), antibiotic (Ofloxacin 2%) and 5% povidone-iodine solutions were instilled into the eye. A lid speculum was inserted. At the slit lamp, a 27-gauge needle attached to a 1-ml syringe was passed into the subconjunctival space on the opposite site of the scleral flap (figure 2). After that, 0.1 ml of 2% lidocaine with epinephrine was injected. The needle was advanced into a long track towards the cyst to minimize the chance of leakage. Using up-and-down and back-and-forth sweeping movements, the scar tissue was ruptured underneath the conjunctiva, always taking care not to perforate the bleb wall. Then, aqueous flow was reestablished, increasing the bleb size. The needle was removed, and, with a 25-gauge needle attached to an insulin syringe, 5 mg (0.2 ml of 25 mg/ml solution) of 5-FU was subconjunctivally injected superior to the bleb (figure 2).

A topical antibiotic (ofloxacin 2%) was given four times a day for two weeks, and a steroid (prednisolone 1%) was given four times a day and was tapered as clinically indicated.

The intraocular pressure was measured immediately after; one day after; and one, three, six, and twelve months after the



**Figure 1** - Encapsulated bleb – localized, dome-shaped bleb (arrows).



**Figure 2** - A) Encapsulated bleb. B) Needle insertion site. C) Subconjunctival 5-FU injection site.

procedure. Only the twelve-month IOP was analyzed in this study. All patients were evaluated at the same time (10 am  $\pm$  one hour) to minimize fluctuation issues.

According to Shin et al. (16), the target intraocular pressure was set for each patient based on the disease progression severity and clinical history. Success was considered as achieving the target pressure,  $\leq 18$  mmHg, and a 20% reduction from baseline at last follow-up (without any hypotensive agents in the TNR group). The exclusion criterion was the requirement of any further treatments, including medical or surgical procedures. In the MT group, topical hypotensive treatment was initialized with a nonspecific beta-blocker and/or prostaglandin, followed by carbonic anhydrase inhibitors and/or selective alpha agonists, as necessary. Systemic medication was not used. The exclusion criterion was the requirement of any further surgical procedures.

The demographic data and characteristics of the study population were collected.

Statistical analyses between variables were performed using the Student's *t*-test for parametric data and chi-square and Mann-Whitney U tests for non-parametric data. Two tailed *p* values  $<0.05$  were taken to indicate significance. The SPSS software version 15.0 (SPSS Inc., Chicago, IL) was used for statistical analyses.

## RESULTS

Among the 40 eyes analyzed during a 12-month time period, 20 were randomized to TNR, and 20 were randomized to MT. In the TNR group, the mean age was  $57.30 \pm 15.21$  years (range 27-83 years). Fifty-five percent of the subjects were female, and 65% were white. In the MT group, the mean age was  $63.30 \pm 12.01$  years (range 27-79 years), 60% were female, and 30% were white (Table 1). The types of glaucoma are also shown in Table 1.

The mean times between the filtering surgery and initial treatment after randomization were  $43.15 \pm 28.71$  days



**Table 1 - Demographic data and characteristics of the study population.**

	Transconjunctival needling revision (TNR)	Medical treatment (MT)	p value
Age (mean ± SD – range)	57.30 ± 15.21 (27-83)	63.30 ± 12.01 (27-79)	0.17
<b>Gender</b>			
Female	11 (55%)	12 (60%)	0.75
Male	9 (45%)	8 (40%)	
<b>Race</b>			
White	13 (65%)	6 (30%)	0.07
Black	7 (35%)	13 (65%)	
Asian	-	1 (5%)	
<b>Glaucoma Type</b>			
Primary open angle	17 (85%)	18 (90%)	0.55
Congenital	1 (5%)	1 (5%)	
Inflammatory	1 (5%)	-	
Pseudoexfoliative	-	1 (5%)	
Neovascular	1 (5%)	-	0.55
<b>Time from last surgery to treatment (days) – range</b>	43.15 ± 28.71 (17-153)	51.60 ± 30.61 (23-139)	0.34

(range 17-153 days) in the TNR group and 51.60 ± 30.61 days (range 23-139 days) in the MT group ( $p=0.34$ ).

The mean IOPs before the initial treatment were 25.15 ± 5.25 mmHg in the TNR group and 25.10 ± 4.36 mmHg in the MT group ( $p=0.58$ ). The mean IOPs at the 12 month follow-up were 12.14 ± 2.80 mmHg in the TNR group and 15.13 ± 2.07 mmHg in the MT group ( $p=0.004$ ) (Table 2). Fourteen eyes (70%) in the TNR group and 15 eyes (75%) in the MT group were considered successes ( $p=0.89$ ). Six eyes (30%) were excluded in the TNR group (five required MT and one further surgery), and five eyes (25%) were excluded in the MT group (four required further filtering surgery and one was submitted to the needling procedure) ( $p=0.79$ ).

The comparison of the IOP distribution before and after the treatment in both groups is shown in Figure 3 (boxplot).

The mean number of needling procedures in the TNR group was 1.35 ± 0.49, and the mean number of medications in the MT group was 2.15 ± 0.74 at the last follow-up.

Complications after the needling procedure were observed in three eyes (15%). One eye had a flat anterior chamber and hyphema, and one eye had a small choroidal effusion. Both were resolved with conservative treatment. One eye had a flat anterior chamber and a choroidal effusion that required surgical treatment.

**DISCUSSION**

Several studies have demonstrated the efficacy of needling revision in failing filtering blebs after filtration surgery (1-4,6,12,13,16-21). However, as bleb morphology, time of needling, follow-up period and successful criteria are different in each study, comparisons of these studies would not be meaningful.

Multiple bleb morphologies have been present in the majority of studies; encapsulated blebs appear to have better results in comparison to flat blebs (22). Rotchford & King (12) suggested that high blebs were more likely to survive

than flat blebs if needling was performed within three months after trabeculectomy. Iwach et al. (20) reported a lower failure rate after the needling procedure in encapsulated blebs (19%) in comparison to diffuse blebs (53%). Interestingly, Broadway et al. (1) reported success rates of 47% for encapsulated blebs and 55% for flat blebs when considering an IOP reduction to less than 22 mmHg as success. To minimize the influence of bleb morphology, we have only considered encapsulated blebs in this study.

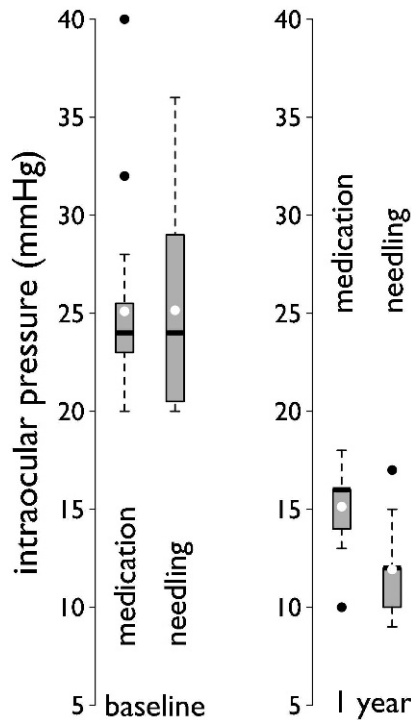
The success rate of MT in eyes with encapsulated blebs has been reported to range from 71 to 100% (23-25). Comparisons between MT and surgical revision have been previously reported. Costa et al. (13) compared eyes with encapsulated blebs that were randomized to MT or the needling procedure; at the last follow-up, they reported a mean IOP of 16.09 ± 6.92 mmHg in the eyes receiving MT in comparison to a mean IOP of 18.92 ± 6.39 mmHg in the eyes submitted to the needling procedure in addition to MT. In our study, we reported significantly better results after TNR alone (without medication) in comparison to MT (12.14 ± 2.80 mmHg and 15.13 ± 2.07 mmHg, respectively). The use of adjunctive 5-FU may explain our better results in eyes submitted to TNR. Several studies have shown that the use of adjunctive antifibrotic agents seems to increase the success rates of both MMC and 5-FU (1,3,17,20,26).

Although the time between the trabeculectomy and the needling procedure does not seem to be a determinant of success, (1) Rotchford & King (12) reported better results when performing needling revisions within a three-month period after trabeculectomy in elevated blebs. We also performed revisions in elevated blebs (encapsulated) a short period of time after trabeculectomy (51.60 ± 30.61 days).

Complications of the needling procedure after trabeculectomy have been previously reported, but most were considered minor and were resolved spontaneously (18,27). Temporary conjunctival leakage, small hyphemas and temporary shallowing of the anterior chamber have been

**Table 2 - Average intraocular pressure before and after randomization (at the 12-month follow-up) in the TNR and MT groups.**

	Transconjunctival needling revision (TNR)	Medical Treatment (MT)	P value
IOP pre-treatment (mmHg)	25.15 ± 5.25	25.10 ± 4.36	0.58
IOP post-treatment at 12-months follow up (mmHg)	12.14 ± 2.80	15.13 ± 2.07	0.004



**Figure 3** - Boxplot showing a comparison of IOP profiles before and after randomization at the 12-month follow-up.

reported (18,27). However, some reports have suggested more severe complications when performing needling in flat and scarred blebs (28,29). In our study, we observed complications in three eyes (15%); only one eye required further surgical treatment.

In this study, we achieved similar success rates in eyes randomized to MT in comparison to TNR with 5-FU (75% versus 70%, respectively). However, a significantly lower mean IOP after TNR was observed. By including only encapsulated blebs in this study, the accuracy of measuring successful treatment was increased through the elimination of variations in morphological characteristics. We suggest that TNR with adjunctive 5-FU without further medical therapy is very effective at maintaining a successful IOP for 12 months. The limitations of this prospective study include the small sample size and the short follow-up period.

In conclusion, over a 12-month follow-up, this study showed that TNR with adjunctive 5-FU is as effective as MT. However, TNR has the advantage of being compliance-free and of recovering previously failed trabeculectomies in eyes with encapsulated blebs.

**AUTHOR CONTRIBUTIONS**

All authors have contributed to the data collection and analysis and to the writing of this paper.

**REFERENCES**

1. Broadway DC, Bloom PA, Bunce C, Thiagarajan M, Khaw PT. Needle revision of failing and failed trabeculectomy blebs with adjunctive 5-fluorouracil: survival analysis. *Ophthalmology*. 2004;111(4):665-73.

2. Maestrini HA, Cronemberger S, Matoso HD, Reis JR, Merula RV, Filho AD, et al. Late needling of flat filtering blebs with adjunctive mitomycin C: efficacy and safety for the corneal endothelium. *Ophthalmology*. 2011;118(4):755-62.

3. Kapasi MS, Birt CM. The efficacy of 5-fluorouracil bleb needling performed 1 year or more posttrabeculectomy: a retrospective study. *J Glaucoma*. 2009;18(2):144-8.

4. Paris G, Zhao M, Sponsel WE. Operative revision of non-functioning filtering blebs with 5-fluorouracil to regain intraocular pressure control. *Clin Experiment Ophthalmol*. 2004;32(4):378-82.

5. Fagerli M, Lofors KT, Elsas T. Needling revision of failed filtering blebs after trabeculectomy: a retrospective study. *Acta Ophthalmol Scand*. 2003;81(6):577-82.

6. King AJ, Rotchford AP, Alwitary A, Moodie J. Frequency of bleb manipulations after trabeculectomy surgery. *Br J Ophthalmol*. 2007;91(7):873-7.

7. Skuta GL, Parrish RK, 2nd. Wound healing in glaucoma filtering surgery. *Surv Ophthalmol*. 1987;32(3):149-70.

8. Addicks EM, Quigley HA, Green WR, Robin AL. Histologic characteristics of filtering blebs in glaucomatous eyes. *Arch Ophthalmol*. 1983;101(5):795-8.

9. Schwartz AL, Van Veldhuisen PC, Gaasterland DE, Ederer F, Sullivan EK, Cyrlin MN. The Advanced Glaucoma Intervention Study (AGIS): 5. Encapsulated bleb after initial trabeculectomy. *Am J Ophthalmol*. 1999;127(1):8-19.

10. Richter CU, Shingleton BJ, Bellows AR, Hutchinson BT, O'Connor T, Brill I. The development of encapsulated filtering blebs. *Ophthalmology*. 1988;95(9):1163-8.

11. Campagna JA, Munden PM, Alward WL. Tenon's cyst formation after trabeculectomy with mitomycin C. *Ophthalmic Surg*. 1995;26(1):57-60.

12. Rotchford AP, King AJ. Needling revision of trabeculectomies bleb morphology and long-term survival. *Ophthalmology*. 2008;115(7):1148-53 e4.

13. Costa VP, Correa MM, Kara-Jose N. Needling versus medical treatment in encapsulated blebs. A randomized, prospective study. *Ophthalmology*. 1997;104(8):1215-20.

14. Pederson JE, Smith SG. Surgical management of encapsulated filtering blebs. *Ophthalmology*. 1985;92(7):955-8.

15. Hodge W, Saheb N, Balazsi G, Kasner O. Treatment of encapsulated blebs with 30-gauge needling and injection of low-dose 5-fluorouracil. *Can J Ophthalmol*. 1992;27(5):233-6.

16. Shin DH, Kim YY, Ginde SY, Kim PH, Eliassi-Rad B, Khatana AK, et al. Risk factors for failure of 5-fluorouracil needling revision for failed conjunctival filtration blebs. *Am J Ophthalmol*. 2001;132(6):875-80.

17. Gutierrez-Ortiz C, Cabarga C, Teus MA. Prospective evaluation of preoperative factors associated with successful mitomycin C needling of failed filtration blebs. *J Glaucoma*. 2006;15(2):98-102.

18. Allen LE, Manuchehri K, Corridan PG. The treatment of encapsulated trabeculectomy blebs in an out-patient setting using a needling technique and subconjunctival 5-fluorouracil injection. *Eye (Lond)*. 1998;12(Pt 1):119-23.

19. Shetty RK, Wartluft L, Moster MR. Slit-lamp needle revision of failed filtering blebs using high-dose mitomycin C. *J Glaucoma*. 2005;14(1):52-6.

20. Iwach AG, Delgado MF, Novack GD, Nguyen N, Wong PC. Transconjunctival mitomycin-C in needle revisions of failing filtering blebs. *Ophthalmology*. 2003;110(4):734-42.

21. Perucho-Martinez S, Gutierrez-Diaz E, Montero-Rodriguez M, Mencia-Gutierrez E, Lago-Llinas MD. [Needle revision of late failing filtering blebs after glaucoma surgery]. *Arch Soc Esp Oftalmol*. 2006;81(9):517-22.

22. Kapetansky FM, Kapetansky SD. Antimetabolite use in revising failing filtering blebs. *Semin Ophthalmol*. 1999;14(3):144-51.

23. Scott DR, Quigley HA. Medical management of a high bleb phase after trabeculectomies. *Ophthalmology*. 1988;95(9):1169-73.

24. Sherwood MB, Spaeth GL, Simmons ST, Nichols DA, Walsh AM, Steinmann WC, et al. Cysts of Tenon's capsule following filtration surgery. Medical management. *Arch Ophthalmol*. 1987;105(11):1517-21.

25. Shingleton BJ, Richter CU, Bellows AR, Hutchinson BT. Management of encapsulated filtration blebs. *Ophthalmology*. 1990;97(1):63-8.

26. Anand N, Khan A. Long-term outcomes of needle revision of trabeculectomy blebs with mitomycin C and 5-fluorouracil: a comparative safety and efficacy report. *J Glaucoma*. 2009;18(7):513-20.

27. Greenfield DS, Miller MP, Suner IJ, Palmberg PF. Needle elevation of the scleral flap for failing filtration blebs after trabeculectomy with mitomycin C. *Am J Ophthalmol*. 1996;122(2):195-204.

28. Mathur R, Gazzard G, Oen F. Malignant glaucoma following needling of a trabeculectomy bleb. *Eye (Lond)*. 2002;16(5):667-8.

29. Maestrini HA, Fernandes TA, Matoso HD, Amaral WO, Maestrini AA. [Scleral injure caused by needling revision with adjunctive mytomycin-C: case report]. *Arq Bras Oftalmol*. 2011;74(2):134-5.