

Diego Rodrigues Pessoa^{1,2}

Davidson Ribeiro Costa¹

Bruno de Moraes Prianti³

David Ribeiro Costa¹

Carolina Alves Delpasso¹

Emília Ângela Lo Schiavo Arisawa³

Renata Amadei Nicolau^{3,4}

Association of facial massage, dry needling, and laser therapy in Temporomandibular Disorder: case report

Associação entre massagem facial, agulhamento a seco e laserterapia no tratamento da Disfunção Temporomandibular: relato de caso

Keywords

Temporomandibular Joint Dysfunction Syndrome
Low-level Light Therapy
Phototherapy
Massage
Electromyography

Descritores

Síndrome da Disfunção da Articulação Temporomandibular
Terapia com Luz de Baixa Intensidade
Fototerapia
Massagem
Eletromiografia

Correspondence address:

Davidson Ribeiro Costa
Centro de Pesquisas Avançadas em Fototerapia – CPAF
Rua Santa Cecília, 80, Centro, Jacareí (SP), Brasil, CEP: 12300-000.
E-mail: dnribcosta@hotmail.com

Received: December 20, 2017

Accepted: May 09, 2018

ABSTRACT

This case report aims to evaluate the treatment of Temporomandibular Disorder (TMD) of muscular origin by associating facial massage (FM), dry needling (DN), and low-level laser therapy (LLLT). The pre- and post-treatment evaluations consisted of clinical examinations based on the Research Diagnostic Criteria (RDC) for TMD, pain intensity quantification by means of the Visual Analog Scale (VAS), mandibular movement measurement, and electromyographic (EMG) analysis of the masseter and temporal muscles. Post-therapy assessment indicated a decrease in pain sites of 58%, in pain intensity mean (1.3), and an increase in the maximum aperture of 10 mm, in addition to normalization of EMG signals. We conclude that, after application of the treatment protocol, there was a decrease in painful sites, gain in amplitude of mandibular movements, and normalization of EMG activity.

RESUMO

O objetivo do presente relato de caso é avaliar a associação entre a Massagem Facial (MF), Agulhamento a Seco (AS) e Terapia a Laser de Baixa Intensidade (TLBI) no tratamento da Disfunção Temporomandibular (DTM) de origem muscular. Paciente com DTM crônica foi submetida a 4 sessões de associação entre a MF, AS e TLBI. A avaliação inicial e final foi composta por exame clínico baseado nos Critérios diagnósticos de pesquisa para DTM (RDC - *Research Diagnostic Criteria*), quantificação da intensidade da dor por meio da Escala visual analógica de dor, mensuração dos movimentos mandibulares e análise eletromiográfica (EMG) dos músculos masseter e temporal. Na pós-terapia, foi observada a redução de 58% dos sítios dolorosos, da média (1,3) da intensidade de dor e aumento de 10 mm na abertura máxima, além da normalização dos sinais EMG. Conclui-se que, após a aplicação de protocolo de tratamento, houve a redução dos sítios dolorosos, ganho de amplitude dos movimentos mandibulares e normalização da atividade EMG.

Study conducted at Instituto de Pesquisa e Desenvolvimento – IP&D, Universidade do Vale do Paraíba – UNIVAP - São José dos Campos (SP), Brasil.

¹ Centro de Pesquisas Avançadas em Fototerapia – CPAF - Jacareí (SP), Brasil.

² Associação de Ensino Superior do Piauí – AESPI - Teresina (PI), Brasil.

³ Universidade do Vale do Paraíba – UNIVAP - São José dos Campos (SP), Brasil.

⁴ Curso de Formação de Alta Performance em Laserterapia – Habillaser - São José dos Campos (SP), Brasil.

Financial support: nothing to declare.

Conflict of interests: nothing to declare.



This is an Open Access article distributed under the terms of the Creative Commons Attribution License, which permits unrestricted use, distribution, and reproduction in any medium, provided the original work is properly cited.

INTRODUCTION

Temporomandibular disorders (TMD) are defined as heterogeneous musculoskeletal and neuromuscular diseases that affect the stomatognathic system, and are characterized by intermittent pain or discomfort in the temporomandibular joint (TMJ), masticatory muscles, and adjacent tissues. It may also impair the most important orofacial functions: mastication, speech, and yawning^(1,2).

In this respect, a myriad of complex factors may contribute to TMD development and perpetuation. Masticatory muscle pain, joint noise, limited motion range, mandibular deviations, muscular hypertonicity, headache, tinnitus, and vertigo⁽³⁾ are observed among the signs and symptoms presented by TMD patients.

Costa et al.⁽¹⁾ point out that myogenic TMD is the most frequent condition among these patients. Myofascial pain is characterized by muscular hyperactivation and reduction in the normal blood flow of the muscle tissues, which leads to the accumulation of metabolism by products in this tissue, causing pain, inflammation, and fatigue⁽²⁾. Moreover, hypertonicity and hypersensitivity areas can be observed in a particular muscle zone, which allows identification of the so-called trigger points in a single muscle or in several muscle groups⁽⁴⁾. Furthermore, painful processes cause an intense release of angiogenic chemical mediators—such as phospholipids, which activate nociceptive receptors. With respect to inflammation, a local edema is formed and leukotriene and serotonin are released by virtue of the destruction of platelets⁽¹⁾. Finally, in fatigue, the lactic acid accumulation that can compromise the musculature relaxation cycle is observed⁽⁵⁾.

Currently, several conservative treatment methods are used to treat TMD. They may include use of an occlusal plate, drug routines, physiotherapy, and psychological care, among others.

Low-level laser therapy (LLLT) has been widely studied and employed in the scientific and clinical settings with positive results⁽³⁾ for TMD treatment. The practice of LLLT in TMD cases also favors vascularization, nutrient support, and lymphatic flow increase. As a consequence, it helps to reduce edema and pain and to expand mandibular amplitude, among other benefits⁽¹⁾.

Dry needling (DN) has been used by several healthcare professionals in clinical practice for the treatment of TMD^(4,6). It is defined as a method where small-gauge filiform needles are used to stimulate myofascial trigger points (TrP), connective and muscular tissues in order to treat neuromusculoskeletal pain and movement disorders^(4,6).

Facial massage (FM), in turn, has been employed as a non-invasive method for treatment of TMD. Holey et al.⁽⁷⁾ show that the massage stimulates the parasympathetic center, promoting response in terms of muscle relaxation, where the analgesic effect is associated with activation of the pain gate mechanism^(5,7). Notwithstanding such interventions in TMD treatment, studies associating LLLT, DN, and FM have not been carried out for this purpose yet. Therefore, this research aims to evaluate the efficacy of associating LLLT, DN, and FM for the treatment of TMD of muscular origin.

CLINICAL CASE PRESENTATION

A 29-year-old woman attended the Laser and Photobiology Center of Universidade do Vale do Paraíba (UNIVAP) presenting intense orofacial pain, trismus, and limited mouth movement. The patient reported having presented these symptoms for approximately six months or more. Following examination by a dentist, the patient was diagnosed with TMD of muscular origin.

This clinical case was submitted to, and approved by, the UNIVAP Human Research Ethics Committee (CEP/UNIVAP—number 2037323/2017), given that it abides by all of the ethical guidelines established by the National Health Council Resolution 466/2012. The research volunteer signed the free and informed consent form, and all of her rights were protected.

The patient was submitted to four sessions of FM, DN, and LLLT association therapy with a seven-day interval between each session. During the treatment, the patient was instructed not to use analgesic and/or anti-inflammatory drugs, nor any other alternative treatment for TMD.

Initially, the Research Diagnostic Criteria (RDC) were used for the clinical examination and patient diagnosis⁽¹⁾. In this respect, it is important to clarify that the RDC is divided into two axes: Axis II comprises a questionnaire with the purpose of quantifying the chronic pain, as well as signs of anxiety, stress, depression, and physical symptoms; then, Axis I, consisting of the clinical examination, is performed. This axis addresses the signs, symptoms, and mandibular movement limitations related to TMD. Both axes of evaluation were performed before and after the treatment (21 days after the first session). Furthermore, pre- and post-treatment evaluations were performed by a dentist with over seven years' experience and previously trained in this field.

As regards the measurement of mandibular movement amplitude (MMMA), a 30 cm long transparent plastic ruler (Acrilex[®]) was used for evaluation of the following parameters: maximum aperture, maximum aided aperture, right and left laterality, and protrusion. Upon assessment of the maximum aided aperture, the examiner positioned her thumb on the upper central incisors and her index finger towards the patient's lower central incisors, slightly forcing opening and ceasing movement upon the patient's first sign of painful discomfort. MMMA measurement was performed by reference to the upper central incisors and lower incisors incisal edge, in accordance with the RDC guidelines.

The clinical muscle/articular palpation examination was performed bilaterally, aiming to investigate the sensitivity aspects and pain presence, also in accordance with the RDC recommendations. Muscle/articular palpation was performed in the following anatomic structures of the orofacial region: temporal muscle; posterior fibers (behind and above the ears), medium fibers (3 cm in front of the anterior point and 4-5 cm from the eyebrow lateral border), and anterior fibers (infratemporal fossa, immediately above the zygomatic process); upper portion of the masseter muscle (below the zygomatic arch and anteriorly to the muscular border), middle portion of the masseter muscle (below the zygomatic process on the anterior muscle border), and its lower portion (anterior to the mandible angle); mandible

posterior region (between the sternocleidomastoid muscle and the mandible posterior border insertion); submandibular region (below the mandible, 2 cm anterior to its angle); lateral pole (ear tragus); and TMJ posterior ligament (left external meatus). The intraoral evaluation consisted in palpation of the lateral pterygoid muscle, while the patient was asked to open the mouth and then perform the lateral excursion movement for examination, while the examiner placed the indicator on the lateral alveolar ridge portion, near the upper molars. Finally, temporal tendon palpation was performed near the coronoid process.

The pain Visual Analog Scale (VAS) was employed in order to record the intensity of discomfort. It is widely used and recommended by the American Dental Association as a criterion to verify pain concentration and consists of a 10 cm horizontal numerical scale, printed on A4 paper. The patient is asked to enter their pain intensity by marking the corresponding value with a pencil upon clinical examination (muscle and joint palpation) based on the RDC/TMD. The VAS classification ranges from 0-10, where 0 means “no pain at all”, and 10, “the worst pain imaginable”.

The electrical activity of temporal and masseter muscles was recorded (bilaterally) by an electromyograph (EMG System do Brasil, Brazil) before and after the end of treatment. Thus, the resting and isometric movement protocols were performed for 10 seconds. With respect to the resting protocol, the patient was asked to keep her upper and lower lip in contact, without occlusal connection of the teeth. As to the isometric movement protocol, the volunteer was asked, through electrical signals, verbal stimulus, and visual feedback, to perform teeth occlusion with an isometric contraction. In order to avoid direct occlusal contact between the teeth, a dental cotton roll (Cremer, Santa Catarina, Brazil), was positioned bilaterally in the molar region⁽⁵⁾. For the signals analysis, we used software EMGworks Analysis® 4.1, whereas the data obtained was treated with 20 to 450Hz Butterworth type band pass filter. For the analysis of signals by the Wavelet Transform continuous (TW), the Matlab 7.01® 4.1 software was used in the Morlet function, where the first and last second of each signal were discarded.

The facial massage (FM) was performed for twenty minutes by a trained physiotherapist. The patient was placed in dorsal decubitus to promote maximum relaxation. Prior to the intervention, the patient’s skin antiseptics was made with alcohol 70% (Santa Cruz®, São Paulo, Brazil) in order to reduce skin oiliness. The protocol comprised synchronized kneading and sliding maneuvers, with a medium pressure degree on the temporal and masseter muscles, bilaterally, over a period of four weeks. During the massage, a liquid glycerine cream (São Paulo, Brazil, Rioquímica) was applied to reduce friction between the participant’s skin and the therapist’s hands. The procedure was carried out in two stages: The first step consisted in a clockwise sliding maneuver performed in the anterior temporal muscle fibers, while the second step involved kneading movements in the craniocaudal direction on the masseter muscle.

The DN sessions were used bilaterally in the muscles studied, followed by the therapeutic massage and skin cleanliness with alcohol 70%. The needles were inserted perpendicularly to the skin, with the patient positioned in the dorsal decubitus. Then, lateral

flexion was realized with cervical rotation. Subsequently, the regions with trigger point zones were marked where sterile, filiform, stainless steel needles (DUX Acupuncture, Masterminds Ltda, Porto Alegre, Brazil) were inserted. The technique was used for two minutes. At that moment, the needle was rotated in a bidirectional manner and remained inserted until all of the trigger points had been fully deactivated.

For LLLT, a laser (Clean Line, Brite Laser, São Paulo, Brazil - ANVISA register 80210180007) was used with the parameters presented in Table 1.

The considerations taken into account in the present case report were based on previous studies^(1,3). LLLT was performed in a dedicated manner: bilaterally, in contact, and perpendicularly to the skin surface. Four points were shaped like a cross in the pre-auricular region, one point was placed near the external acoustic meatus, two points on the temporal muscle, and six points on the masseter muscle⁽¹⁾. The treatments were conducted by a single physiotherapist, who did not have access to the evaluations.

The volunteer was classified, as per the RDC, with TMD of muscular origin with severe limitation of mandibular movements. After treatment, the diagnosis was changed to TMD of muscular origin with moderate limitation of mandibular movements. The initial ROM examination observed a 30 mm maximum mouth opening, 40 mm maximum aided opening, 03 mm protrusion, 03 mm right lateral excursion, and 04 mm left lateral excursion. After four weeks of treatment, the patient was re-evaluated and the following values were obtained: increase of 10 mm (33%) in maximum aperture; increase of 12 mm (40%) in maximum

Table 1. Parameters used in low-level laser therapy

Parameters	Laser
λ (nm)	780
A (cm ²)	0.5
\varnothing (cm)	0.8
P (W)	0.1
t (s)	60
E (J)	6
ED (J/cm ²)	12

Caption: λ = Wave-length; A = Area; \varnothing = Diameter; P = Power; t = time; E = Energy; ED = Energy Density

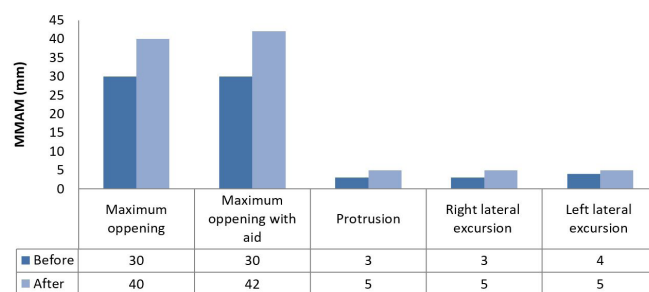
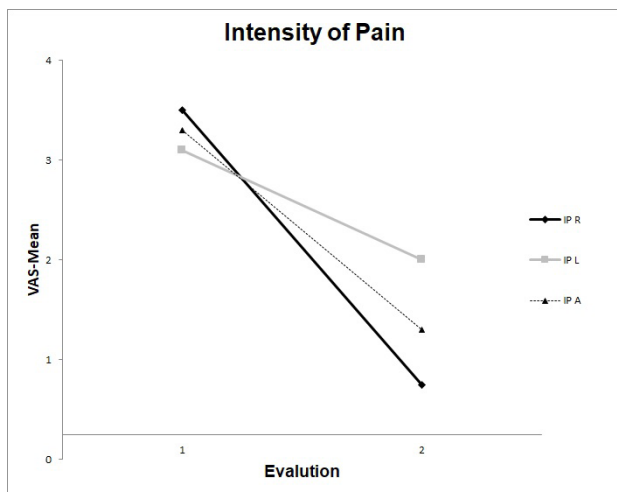


Figure 1. Pre and post-treatment evaluation of TMD with association therapy of FM + DN + LLLT in relation to the mandibular movement amplitude measurement (MMAM)

aided opening; 02 mm (66%) gain in protrusion; and 01 mm (25%) advantage in the right and left lateral excursion, between the first and last evaluation, respectively, as shown in Figure 1.

With regard to the muscle/joint palpation examination, 24 sites were evaluated. The patient reported pain in the following anatomical structures: temporal muscle (posterior, medium, and previous fibers), masseter muscle (upper, medium, and lower fibers), intrabucal region (lateral pterygoid and temporalis muscle tendon), submandibular region and lateral pole, from both sides,



Caption: IP R = mean pain intensity on the right side sites; IP L = mean pain intensity on the left side sites; IP A = mean pain intensity in all painful sites; 1 = evaluation before treatment; 2 = evaluation after the end of treatment

Figure 2. Evaluation of pain intensity in patients with TMD by means of the VAS pre- and post-treatment during four weekly sessions

totaling 12 sites. According to the data obtained by the VAS in the pre-treatment examination, the mean pain on the right side was 3.5, and 3.1 on the left side, resulting in an average pain intensity of 3.3. After application of the combination therapy protocol for 21 days, a decrease of 78.5% in painful sites was observed on the right side, considering that the pain level decreased from 3.5 to 0.75. On the left side, the intervention allowed for a decrease of 36.8%, where the pain level dropped from 3.1 to 2. Overall, a decrease of 58% of pain sites was observed with a mean reduction from 3.3 to 1.3 (Figure 2).

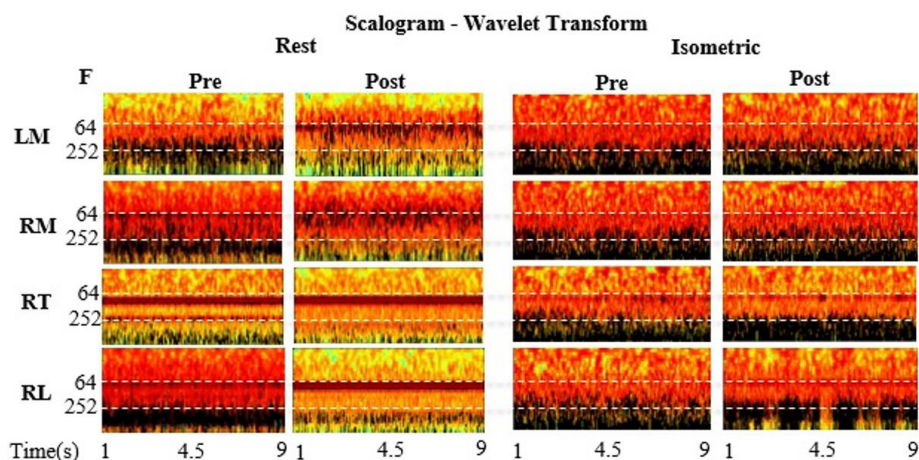
As mentioned throughout this analysis, 24 sites were evaluated upon muscle examination and joint palpation. In the pre-treatment evaluation, the volunteer reported pain on 10 sites. After four weeks of treatment, it was possible to verify a decrease in only five painful sites.

Table 2 shows the RMS values obtained for the left masseter muscles (LM), right masseter (RM), left temporalis (LT) and right temporalis (RT) in pre- and post-treatment resting positions. In the pre-treatment resting protocol, the muscles' mean values LM (3.59E+06), RM (2.89E+06), LT (8.46E+06) and RT (3.30E+06) were detected. Nevertheless, a mean decrease was observed after the treatment in muscles LM (2.63E+06), LT (5.35E+06), and RT (1.29E+06), while the muscle RM presented a mean increase (4.31E+06). With regard to the isometric procedure before the therapies, the muscles' means found were as follows: LM (3.22E+07), RM (5.76E+07), LT (3.39E+07), and TD (3.91E+06). After application of the combined therapy, we observed a considerable increase of muscles' mean values in LM (7.90E+07), RM (7.13E+07), and RT (4.56E+06), as well as a discrete reduction in muscle TE (3.37E+07).

Table 2. Values of Root Mean Square (RMS) from surface electromyography in the pre- (I) and post-treatment (II) evaluations

Evaluation	Rest				Isometric			
	LM	RM	LT	RT	LM	RM	LT	RT
I	3.59E+06	2.89E+06	8.46E+06	3.30E+06	3.22E+07	5.76E+07	3.39E+07	3.91E+06
II	2.63E+06	4.31E+06	5.35E+06	1.29E+06	7.90E+07	7.13E+07	3.37E+07	4.56E+06
D	9.60E+05	1.2E+06	-3.11E+06	-2.01E+06	4.68E+07	1.37E+07	-2.00E+05	6.50E+05

Caption: LM = left masseter; RM = right masseter; LT = left temporalis; RT = right temporalis; D = difference between evaluations (I - II)



Caption: F = Frequency; LM = left masseter; RM = right masseter; RL = left temporalis; RT = right temporalis

Figure 3. Periodograms (Scalogram) of the Masseter and Temporalis muscles in the protocol of rest and isometric movement before and after treatment

The observations in Figure 3 present the periodograms for the TW, where the black color represents the high intensity energy zones (ZHIE), i.e. higher motor unit recruitment in a given frequency band in relation to time. In the resting protocol, we observed a decrease in the high frequencies (< 256 Hz) and a slight increase in the low frequencies post-therapy. With regard to the isometric motion procedure, we observed an increase of the ZHIE density at high frequencies (>256 Hz).

DISCUSSION

There are currently several therapeutic modalities for the treatment of TMD. The multifactor etiology of TMD (muscular origin) suggests that it may be advantageous to investigate the effects of different resources used in combination^(2,5). In the present case study, association of the FM, DN, and LLLT techniques was chosen for a patient with TMD of muscular origin, and promising results were obtained. The association technique employed in the TMD allowed for pain reduction, MMMA gain, and electromyographic activity modulation after four weeks of treatment.

It should be noted that, in the current analysis, the FM protocol was utilized in accordance with recommendations from previous studies^(4,8). According to Ariji et al.⁽⁸⁾, when FM is appropriately used, it promotes the reduction of mechanoreceptor sensitization through afferent fibers, causing sensorial pain blockage by diminishing impulses from the peripheral nervous system (PNS) to the central nervous system (CNS). The FM also aims to stimulate local blood circulation, promote the restoration of local osmotic pressure, with the effective edema diminution, contributing to the pain reduction and MMMA gain for the patient.

Gonzalez-Pérez et al.⁽⁹⁾ carried out a study with 48 patients with myofascial pain in the lateral pterygoid muscle. Their results showed that DN promoted local pain reduction and MMMA gain (maximum opening, lateralization, and protrusion) in patients presenting these symptoms. Santos et al.⁽¹⁰⁾ have stated that DN is an effective treatment method for MMAM gain and pain relief. Although this action mechanism has not been fully demonstrated yet, it is believed that the effects of DN may be associated with either the local contraction response (twitch) following needle insertion into the trigger point or the diffuse nociceptive inhibitory control theory, starting from the endogenous opioid neuropeptides and/or monoaminergic neurotransmitters release, which leads to diffuse local pain reduction from TrP⁽¹¹⁾.

The expressive results found in this case report are also attributed to the use of LLLT, which had already been evidenced in several studies^(1,3,12) due to its photobiomodulatory effects, which play an important role in TMD treatment symptomatology. In this regard, the LLLT effects occur through metabolic activation after electromagnetic light absorption to stimulate the mitochondria respiratory chain (Cytochrome C oxidase), increasing the local peripheral vascularization and taking oxygen to the hypoxic cells in the painful regions^(1,3,12). Studies have also used orofacial myofunctional therapy alone or in combination with LLLT, as a complementary intervention modality for the improvement of TMD frames and stability of the results obtained over time.

Felicio et al.⁽¹³⁾ evaluated 40 volunteers with TMD and observed that the group that received myofunctional therapy showed a significant reduction in pain sensitivity and MMAM increase. On the other hand, Machado et al.⁽¹⁴⁾ verified the efficacy of therapies associated with myofunctional therapy, whose results for the volunteers who received the latter associated with LLLT were found to be more effective compared to the treatment in isolation.

It is also worth noting that LLLT promotes pain reduction due to changes in cell membrane permeability, vasodilation, and edema reduction, blocking the nerve fibers in response to the release of endogenous opioids (endorphins and enkephalin). Accordingly, it promotes a decrease of the histamine and acetylcholine release, as well as of bradykinin synthesis⁽¹²⁾. Another factor of LLLT results is that it helps to reduce production of cyclooxygenase 2 (COX-2), prostaglandins, and histamine secretion, cytokines and kinins, such as tumor necrosis factor-alpha (TNF- α), transforming growth factor-beta (TGF- β) and interleukins IL-1 β e IL-6⁽¹²⁾.

In order to reproduce the EMG technique on the different days of the experiment, the sites of electrode fixation were measured, as electrodes fixed at different locations on different days may cause significant changes in the electromyographic signal⁽¹⁵⁾. In view of the present case study character, the periodograms were used from TW qualitative analysis, which has been presented as a mathematical tool for the analysis of non-stationary signals⁽¹⁵⁾. Accordingly, the periodograms allow the examination in two dimensions of the frequency, time, and energy intensity of the signals⁽¹⁵⁾. In short, this information can be considered advantageous to evaluate efficacy of TMD treatments.

As to the resting protocol, a decrease in ZHIE was observed, which in turn suggests a decrease in the activation of motor units. The results are in line with those observed by the RMS, which presented a reduction of 75% in activity of the studied muscles. In the isometric motion protocol, the increased density of RMS and ZHIE, observed after the combination therapy, indicates an increase in the motor units recruitment.

Correlating the RMS data to those of the ZHIE, an improvement is observed in the patient's muscular situation, as individuals with TMD present muscle hyperactivity at rest and, thus, mechanical force decrease during chewing⁽³⁾. Nonetheless, after the proposed treatment protocol, muscle activity reduction during rest and muscle activity increase during isometric movement were observed, which suggests a decrease in hyperactivation and muscle fatigue.

Among the limitations of the study, we may point out the absence of measurement of the strength of masticatory muscles and groups of separate treatments, as well as the relationship of biochemical parameters such as salivary cortisol to investigate possible levels of stress. The evaluation of these methods in future studies is of paramount importance to clarify the effect of each treatment and the influence of a potential placebo effect—since it refers to a set of inert actions that generate physiological responses based on the patient's belief.

Promising results were observed in this case report. However, complete remission of TMD signs and symptoms was not

observed. This suggests that the treatments employed had no effect on the etiology or cause of the disorder; hence, this protocol may be considered as a support for the control of signs and symptoms. According to Costa et al. (1), the identification and elimination of etiological factors and treatment performed for a longer period are extremely important for the success of TMD treatment.

FINAL COMMENTS

This study aimed to show the application of the treatment protocol for association of FM, DN, and LLLT therapies in a patient diagnosed with TMD myofascial origin. The results observed include reduction in pain sites, gain in mandibular movement amplitude, and electromyographic activity biomodulation. These results clearly represent great clinical relevance. On this basis, we suggest new clinical studies to further explore association of these techniques.

REFERENCES

1. Costa DR, Ribeiro-Costa D, Pessoa DR, Masulo LJ, Arisawa E, Nicolau RA. Effect of LED therapy on temporomandibular disorder: a case study. *Sci Med*. 2017;27(2):258-72. <http://dx.doi.org/10.15448/1980-6108.2017.2.25872>.
2. Okeson JP. *Dores bucofaciais de Bell*. 6th ed. Carol Stream: Quintessence; 2012.
3. Rodrigues JH, Marques MM, Biasotto-Gonzalez DA, Moreira MS, Bussadori SK, Mesquita-Ferrari RA, et al. Evaluation of pain, jaw movements, and psychosocial factors in elderly individuals with temporomandibular disorder under laser phototherapy. *Lasers Med Sci*. 2015;30(3):953-9. <http://dx.doi.org/10.1007/s10103-013-1514-z>. PMID:24366293.
4. El Hage Y, Politti F, Sousa DF, Herpich CM, Gloria IP, Gomes CA, et al. Effect of mandibular mobilization on electromyographic signals in muscles of mastication and static balance in individuals with temporomandibular disorder: study protocol for a randomized controlled trial. *Trials*. 2013;14(1):316. <http://dx.doi.org/10.1186/1745-6215-14-316>. PMID:24083628.
5. Gomes CA, El Hage Y, Amaral AP, Politti F, Biasotto-Gonzalez DA. Effects of massage therapy and occlusal splint therapy on electromyographic activity and the intensity of signs and symptoms in individuals with temporomandibular disorder and sleep bruxism: a randomized clinical trial. *Chiropr Man Therap*. 2014;22(1):11-7. <http://dx.doi.org/10.1111/j.1365-2842.2008.01898.x>. PMID:25512839.
6. Cross KM, McMurray M. Dry needling increases muscle thickness in a subject with persistent muscle dysfunction: a case report. *Int J Sports Phys Ther*. 2017;12(3):468-75. PMID:28593101.
7. Holey LA, Dixon J, Selfe J. An exploratory themographic investigation of the effects of connective tissue massage on autonomic function. *J Manipulative Physiol Ther*. 2011;34(7):457-62. <http://dx.doi.org/10.1016/j.jmpt.2011.05.012>. PMID:21875520.
8. Arijji Y, Nakayama M, Nishiyama W, Ogi N, Sakuma S, Katsumata A, et al. Potential clinical application of masseter and temporal muscle massage treatment using an oral rehabilitation robot in temporomandibular disorder patients with myofascial pain. *Cranio*. 2015;33(4):256-62. <http://dx.doi.org/10.1179/2151090314Y.0000000030>. PMID:26714800.
9. Gonzalez-Pérez LM, Infante-Cossio P, Granados-Nunez M, Urresti-Lopez FJ, Lopez-Martos R, Ruiz-Canela-Mendez P. Deep dry needling of trigger points located in the lateral pterygoid muscle: efficacy and safety of treatment for management of myofascial pain and temporomandibular dysfunction. *Med Oral Patol Oral Cir Bucal*. 2015;20(3):e326-33. <http://dx.doi.org/10.4317/medoral.20384>. PMID:25662558.
10. Santos RBC, Carneiro MS, Oliveira DM, Maciel AR, Monte-Silva KK, Araújo MGR. Impact of dry needling and ischemic pressure in the myofascial syndrome: controlled clinical trial. *Fisioter Mov*. 2014;27(4):515-22. <http://dx.doi.org/10.1590/0103-5150.027.004.AO03>.
11. Kim W, Kim S, Min B. Mechanisms of electroacupuncture-induced analgesia on neuropathic pain in animal model. *Evid Based Complement Alternat Med*. 2013;2013:1-11. <http://dx.doi.org/10.1155/2013/436913>. PMID:23983779.
12. Garcez Silva A, Simões Ribeiro M, Núñez SC. *Laser de baixa potência: princípios básicos e aplicações clínicas na odontologia*. Rio de Janeiro: Elsevier; 2012.
13. Felício CM, Melchior M, Silva MAMR. Effects of orofacial myofunctional therapy on temporomandibular disorders. *J Craniomandibular Pract*. 2010;28(4):249-59. PMID:21032979.
14. Machado BC, Mazzetto MO, Silva MA, Felício CM. Effects of oral motor exercises and laser therapy on chronic temporomandibular disorders: a randomized study with follow-up. *Lasers Med Sci*. 2016;31(5):945-54. <http://dx.doi.org/10.1007/s10103-016-1935-6>. PMID:27085322.
15. Muñoz ISS, Motta AJ, Nicolau RA, Kelencz CA, Paula C Jr. Analysis of the temporal muscle electromyographic signals using wavelets. *Revista Univap*. 2012;18(32):5-14.

Author contributions

DRP and Davidson RC collaborated on the study design, data collection, analysis, and interpretation, as well as writing of the manuscript; BMP collaborated on data treatment and collection, and writing of the manuscript; David RC and CAD collaborated on data collection and writing of the manuscript; EALSA and RAN collaborated as advisors on the study design and writing of the manuscript.