

# SURGICAL TREATMENT OF FRACTURES DISLOCATION OF LOWER SPINE BY OPEN REDUCTION WITHOUT SKELETAL TRACTION

TRATAMENTO CIRÚRGICO DAS FRATURAS LUXAÇÕES DA COLUNA CERVICAL BAIXA POR REDUÇÃO ABERTA E SEM USO DE TRAÇÃO CRANIANA

TRATAMIENTO QUIRÚRGICO DE LAS FRACTURAS POR LUXACIONES DE LA COLUMNA CERVICAL BAJA, POR REDUCCIÓN ABIERTA Y SIN USO DE TRACCIÓN CRANEANA

MILTON CÉZAR CORREIA<sup>1</sup>, JEFERSON SOARES LEAL<sup>1</sup>, ROGÉRIO LÚCIO CHAVES DE RESENDE<sup>1</sup>, DANIEL FERREIRA GHEDINI<sup>1</sup>

## ABSTRACT

**Objective:** This study aims to demonstrate the results of surgical treatment of lower cervical spine in 34 patients with traumatic fracture-dislocation treated by surgical technique for arthrodesis with fixation without the aid of cranial traction. **Methods:** Patients were evaluated by clinical and radiological assessment. Patients were followed-up for a period of 1-4 years. **Results:** Clinical and radiological fusion was observed in all 34 patients, among them four developed surgical site infection. **Conclusion:** The performance of reduction of fracture dislocation of the lower cervical spine without the use of cranial traction together with surgical anterior approach showed good results with radiological and clinical improvements, as well as low rate of neurological complications.

**Keywords:** Neck pain; Traction; Orthopedics; Spine; Spinal fractures.

## RESUMO

**Objetivo:** Demonstrar os resultados do tratamento cirúrgico na coluna cervical baixa em 34 pacientes portadores de fratura-luxação traumática tratada através de técnica cirúrgica de artrodese com fixação sem o auxílio de tração craniana. **Métodos:** Os pacientes foram avaliados clínica e radiologicamente e acompanhados por um período de um a quatro anos. **Resultados:** A consolidação clínica e radiológica da artrodese foi observada em todos os 34 pacientes, sendo que quatro evoluíram com infecção do sítio cirúrgico posterior quando houve necessidade desse acesso complementar. **Resultados:** A realização de redução da fratura luxação da coluna cervical baixa sem o uso de tração craniana juntamente com acesso cirúrgico por via anterior mostrou bons resultados com melhora clínica e radiológica, além de baixo índice de complicações neurológicas.

**Descritores:** Cervicalgia; Tração; Ortopedia; Coluna vertebral; Fraturas da coluna vertebral.

## RESUMEN

**Objetivo:** Demostrar los resultados del tratamiento quirúrgico de la columna cervical inferior en 34 pacientes con fractura por luxación traumática, tratados mediante la técnica quirúrgica de artrodesis con fijación sin la ayuda de la tracción craneal. **Métodos:** Los pacientes fueron evaluados clínica y radiológicamente, y acompañados durante un período de uno a cuatro años. **Resultados:** La consolidación clínica y radiológica de la artrodesis se observó en todos los 34 pacientes, cuatro progresaron con infección del sitio quirúrgico posterior, cuando hubo necesidad de ese acceso complementario. **Conclusión:** El logro de la reducción de la fractura por luxación de columna cervical baja, sin el uso de la tracción craneana, juntamente con acceso quirúrgico para abordaje anterior, mostró buenos resultados con mejoría clínica y radiológica, así como baja tasa de complicaciones neurológicas.

**Descritores:** Dolor de cuello; Tracción; Ortopedia; Columna vertebral; Fracturas de la columna vertebral.

## INTRODUCTION

The spinal segment located between the third cervical vertebra (C3) and the cervicothoracic junction has been called the lower cervical or sub-axial spine.<sup>1,2</sup> Traumatic injuries of the lower cervical spine between the third and seventh cervical vertebrae (C3-C7) include light stretches of soft tissues to severe fractures with neurological impairment.<sup>1,3-5</sup> Traumatic cervical injuries show a great variety of changes and, according to the AO-ASIF group (Association for Osteosynthesis/Association for the Study of Internal Fixation) are classified based on morphopathological changes provided by imaging exams.<sup>2-5</sup> Thus they have been classified into three types and 15 subtypes. The type A fractures (A1, A2, A3) are caused by a compression mechanism, the type B (B1.1, B1.2,

B1.3, B2.1, B2.2, B2.3, B3.1, B3.2, B3.3) are caused by distraction, and type C (C.1, C.2, C.3) are combinations of type A or B with a rotational component.<sup>1,2</sup>

According to Vaccaro et al.<sup>5</sup> and other authors,<sup>6,7</sup> the treatment of these fractures differ based on the form of dislocation reduction, which may be open or closed; the method of fixation, which can be via an anterior, posterior or double track (anterior and posterior) approach; and the use of magnetic resonance imaging in closed reduction, open reduction and fixation, due to the possibility of a neurological deficit appearing during the medical act.<sup>3-5,8</sup>

There are various techniques and options for treating fracture dislocations of the lower cervical spine, such as closed reduction with progressive traction with the patient awake, which

1. Department of Orthopedics and Traumatology, Hospital das Clínicas, Universidade Federal de Minas Gerais (UFMG), Belo Horizonte, MG, Brazil.

Study conducted by the Spine Surgery Team of the Hospital das Clínicas, UFMG, and at the Hospital Universitário Risoleta Tolentino Neves, Belo Horizonte, MG, Brazil.

Correspondence: Rua Hum, 115, Montes Claros, MG, Brasil. 39400-516. miltonmoc@yahoo.com.br

is technically easier to perform, but presents risks related to the worsening of neurological deficits due to migration of the disc into the canal.<sup>3,5</sup> Some authors have reported up to 80% increase of the disc injury, especially a herniated disc.<sup>3,5</sup> There is also the technique using closed reduction in the operating room with traction and the patient anesthetized.<sup>5,6</sup> Open reduction by a posterior approach is easier, but it may be related to neurological worsening due to the migration of the disc into the spinal canal.<sup>4,6-8</sup> In reduction by an anterior approach, the surgeon may have greater technical difficulty and a greater risk of not obtaining the desired reduction.<sup>9</sup>

The aim of this study is to demonstrate the results of surgical treatment of lower cervical fracture by open reduction using an anterior approach, and without the use of cervical traction on one or more approaches in 34 high-energy trauma patients.

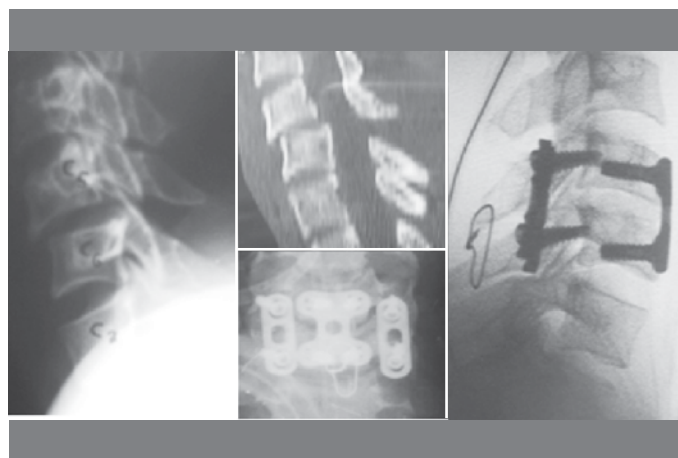## METHODS

Retrospective analysis was performed of patients with unstable lower cervical fracture, referred for surgical treatment treated at the Risoleta Tolentino Neves University Hospital during the period from January 2008 to December 2011. All patients were victims of high-energy trauma, including 21 victims of car or motorcycle accidents, seven victims were run over, and six victims fell from a height. All were approached by the same team and using the same technique, which consisted of open reduction, the initial or only approach was anterior and without the use of cranial traction.

We evaluated 34 patients with 38 fractures. Six women and 28 men with a mean age of 36 years, ranging from 20 to 78 years. Of these, 10 had neurological deficits, three of whom had complete spinal cord injury, 10 different types of fractures according to the AO-ASIF rating, with the most common being types C1 and C3 (nine fractures each) and B1.2 and B3.2 (six fractures each).

## RESULTS

Patients were followed up for a period of one to four years. Complete reduction of the fracture dislocation of the lower cervical spine was observed in 28 patients (82.35%) using only the anterior approach and open reduction. (Figure 1) Closed reduction with cervical traction was not used in any patient. A triple approach (anterior-posterior-anterior) was required in order to reduce the fracture dislocation in six patients (17.65%) (Figure 2), six of which were fractures classified as type B1.2. Complementary fixation was necessary through a posterior approach in seven patients (20.58%). Six corpectomies were performed. No patient developed a neurological deficit. The late complication that occurred postoperatively in four patients (11.76%) evolved with a superficial surgical site infection (all via a posterior surgical approach) and in two patients (5.88%) hematoma of the surgical site occurred in the immediate postoperative period.



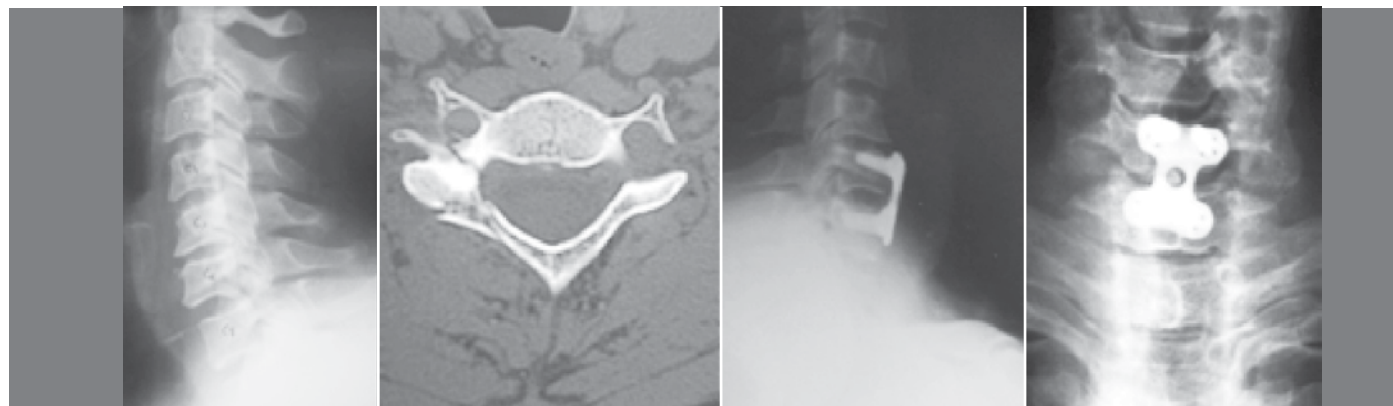
**Figure 2.** Thirty-one-year-old patient with AO-ASIF fracture type B1.2 at C5-C6 level.

## DISCUSSION

According to Grant et al.,<sup>7</sup> in addition to bringing risks, cervical traction for the reduction of fracture dislocation of the lower cervical spine is not mandatory. In fractures type B and C of the AO-ASIF in which uni- or bifacet dislocation occurs, it is possible to achieve reduction through a anterior surgical approach with discectomy and distraction of the vertebral bodies through the Caspar distractor or laminar distractor.<sup>6,10</sup>

Taking into consideration that it takes a high-energy trauma that usually causes serious consequences to the patient in these cases, cases in which there are severe unilateral or bilateral dislocations of facets, or that appear in the form of intervertebral distraction, require careful analysis of the examiner in both the clinical and radiological evaluation, and in the indication for surgical treatment. The cervical traction in these cases is potentially dangerous as it can cause neurological damage, because all of the ligaments are ruptured and show deficits, concentrating the force on the already bruised muscles and cervical neural elements that are barely resistant to strain; besides, it presents risks related to neurological worsening due to the migration of the intervertebral disc into the spinal canal.<sup>3,6</sup> Usually the patients treated at the Risoleta Tolentino Neves University Hospital with suspected cervical fracture dislocation, confirmed by clinical and radiographic evaluation, are not routinely subjected to the installation of a cranial halo. Cranial traction, even with light load, has been demonstrated to lead to deficits in the majority of patients with certain injuries, as evidenced by the study of Grant et al.<sup>7</sup>

The results of this study are consistent with the literature, similar to those reported by Wiseman et al.<sup>6</sup> and Lambiris et al.<sup>10</sup> Good clinical/functional results were achieved in 28 patients (82.35% of good results with open reduction and only an anterior approach) and in six patients (reduction was not achieved in 17.65%, necessitating



**Figure 1.** Forty-four-year-old patient with AO-ASIF fracture type C3 of C6-C7 level.

anterior and posterior approaches). No iatrogenic lesions were identified (0% of neurological damage) that could have occurred with the use of cervical traction. All 34 patients (100%) underwent radiological evaluation in the anteroposterior and lateral views during immediate and late postoperative periods.

## CONCLUSIONS

The surgical technique that consisted of open reduction initiated using an anterior approach is effective, in addition to being safe. It avoids complications caused by the use of cranial traction

and does not subject the patient to the risk of neurological deterioration caused by disc herniation, after closed reduction or open reduction by a posterior approach.

Fractures type B1.2 of the AO-ASIF (posterior spine injury with vertebral body intact and presenting bilateral dislocation) required surgical reduction by a triple approach.

---

All authors declare no potential conflict of interest concerning this article.

---

## REFERENCES

1. Moore TA, Vaccaro AR, Anderson PA. Classification of lower cervical spine injuries. *Spine (Phila Pa 1976)*. 2006;31(Suppl 11):S37-43.
2. Defino HL. Classificação das fraturas da coluna cervical baixa(c3-c7). *Coluna*. 2003;2(1):53-9.
3. Vaccaro AR, Madigan L, Schweitzer ME, Flanders AE, Hilibrand AS, Albert TJ. Magnetic resonance imaging analysis of soft tissue disruption after flexion-distraction injuries of the subaxial cervical spine. *Spine (Phila Pa 1976)*. 2001;26(17):1866-72.
4. Eismont FJ, Arena MJ, Green BA. Extrusion of an intervertebral disc associated with traumatic subluxation or dislocation of cervical facets. Case report. *J Bone Joint Surg Am*. 1991;73(10):1555-60.
5. Vaccaro AR, Falatyn SP, Flanders AE, Balderston RA, Northrup BE, Cotler JM. Magnetic resonance evaluation of the intervertebral disc, spinal ligaments, and spinal cord before and after closed traction reduction of cervical spine dislocations. *Spine (Phila Pa 1976)*. 1999;24(12):1210-7.
6. Wiseman DB, Bellabarba C, Mirza SK, Chapman JR. Anterior versus posterior surgical treatment for traumatic cervical spine dislocation. *Curr Opin Orthop*. 2003;14:174-81.
7. Grant GA, Mirza SK, Chapman JR, Winn HR, Newell DW, Jones DT, et al. Risk of early closed reduction in cervical spine subluxation injuries. *J Neurosurg*. 1999;90(1 Suppl):13-8.
8. Nassr A, Lee JY, Dvorak MF, Harrop JS, Dailey AT, Shaffrey CI, et al. Variations in surgical treatment of cervical facet dislocations. *Spine (Phila Pa 1976)*. 2008;33(7):E188-93.
9. Grauer JN, Vaccaro AR, Lee JY, Nassr A, Dvorak MF, Harrop JS, et al. The timing and influence of MRI on the management of patients with cervical facet dislocations remains highly variable a survey of members of the spine trauma study group. *J Spinal Disord Tech*. 2009;22(2):96-9.
10. Lambiris E, Kasimatis GB, Tyllianakis M, Zouboulis P, Panagiotopoulos E. Treatment of unstable lower cervical spine injuries by anterior instrumented fusion alone. *J Spinal Disord Tech*. 2008;21(7):500-7.