

REPRODUCIBILITY OF TOMOGRAPHIC EVALUATION OF POSTEROLATERAL LUMBAR ARTHRODESIS CONSOLIDATION

REPRODUTIBILIDADE DA AVALIAÇÃO TOMOGRÁFICA DA CONSOLIDAÇÃO DE ARTRODESES POSTEROLATERAIS LOMBARES

REPRODUCIBILIDAD DE LA EVALUACIÓN TOMOGRÁFICA DE LA CONSOLIDACIÓN DE ARTRODESIS POSTEROLATERALES LUMBARES

MARCELO ITALO RISSO NETO¹, GUILHERME REBECHI ZUJANI¹, ROBERTO ROSSANEZ¹, SYLVIO MISTRO NETO¹, AUGUSTO CELSO SCARPARO AMATO FILHO², PAULO TADEU MAIA CAVALI¹, IVAN GUIDOLIN VEIGA¹, WAGNER PASQUALINI¹, MARCOS ANTÔNIO TEBET¹, ELCIO LANDIM¹

ABSTRACT

Objective: To evaluate interobserver agreement of Glassman classification for posterolateral lumbar spine arthrodesis. **Methods:** One hundred and thirty-four CT scans from patients who underwent posterolateral arthrodesis of the lumbar and lumbosacral spine were evaluated by four observers, namely two orthopedic surgeons experienced in spine surgery and two in training in this area. Using the reconstructed tomographic images at oblique coronal plane, 299 operated levels were systematically analyzed looking for arthrodesis signals. The appearance of bone healing in each operated level was classified in five categories as proposed by Glassman to the posterolateral arthrodesis: 1) bilateral solid arthrodesis; 2) unilateral solid arthrodesis; 3) bilateral partial arthrodesis; 4) unilateral partial arthrodesis; 5) absence of arthrodesis. In a second step, the evaluation of each operated level was divided into two categories: fusion (including type 1, 2, 3, and 4) and non fusion (type 5). Statistical analysis was performed by calculating the Kappa coefficient considering the paired analysis between the two experienced observers and between the two observers in training. **Results:** The interobserver reproducibility by the kappa coefficient for arthrodesis consolidation analysis for the classification proposed, divided into 5 types, was 0.729 for both experienced surgeons and training surgeons. Considering only two categories kappa coefficient was 0.745 between experienced surgeons and 0.795 between training surgeons. In all analyzes, we obtained high concordance power. **Conclusion:** Interobserver reproducibility was observed with high concordance in the classification proposed by Glassman for posterolateral arthrodesis of the lumbar and lumbosacral spine.

Keywords: Spine fusion; Tomography; Classification; Spine; Reproducibility of results.

RESUMO

Objetivo: Avaliar a concordância interobservadores da classificação de Glassman para artrodese posterolateral da coluna lombar. **Métodos:** Cento e trinta e quatro tomografias de pacientes submetidos a artrodese posterolateral da coluna lombar e lombossacra foram avaliadas por quatro observadores, sendo dois ortopedistas experientes em cirurgia da coluna e dois ortopedistas em treinamento na área. Utilizando as imagens tomográficas reconstruídas no plano coronal oblíquo foram analisados, sistematicamente, 299 níveis operados, buscando-se sinais de artrodese. O aspecto da consolidação óssea em cada nível operado foi classificado como proposto por Glassman para artrodese posterolateral em cinco categorias: 1) artrodese sólida bilateral; 2) artrodese sólida unilateral; 3) artrodese parcial bilateral; 4) artrodese parcial unilateral; 5) ausência de artrodese. Em um segundo momento, a avaliação de cada nível operado foi dividida em duas categorias: consolidado (tipos 1, 2, 3, e 4 de Glassman) e não consolidado (tipo 5). A análise estatística foi feita pelo cálculo do coeficiente Kappa considerando-se a análise pareada entre os dois observadores experientes e entre dois observadores em treinamento. **Resultados:** A reprodutibilidade interobservadores pelo coeficiente Kappa para a análise de consolidação da artrodese pela classificação proposta, dividida em 5 tipos, foi de 0,729 tanto para os cirurgiões experientes quanto em treinamento. Considerando apenas as duas categorias, obtivemos coeficiente Kappa de 0,745 entre os cirurgiões e de 0,795 entre os residentes. Em todas as análises obtivemos força de concordância alta. **Conclusão:** Foi observada reprodutibilidade interobservadores com concordância alta na classificação proposta por Glassman para as artrodeses posterolaterais da coluna lombar e lombossacra.

Descritores: Fusão vertebral; Tomografia; Classificação; Coluna vertebral; Reprodutibilidade dos testes.

RESUMEN

Objetivo: Evaluar la concordancia entre observadores de la clasificación de Glassman para artrodosis posterolateral de la columna lumbar. **Métodos:** Ciento treinta y cuatro tomografías de pacientes sometidos a artrodosis posterolateral de la columna lumbar y lumbosacra fueron evaluados por cuatro observadores: dos cirujanos ortopédicos con experiencia en la cirugía de columna y dos cirujanos ortopédicos en formación para cirugía de columna. Por medio de las imágenes de TC reconstruidas en el plano coronal oblicuo se analizaron sistemáticamente 299 niveles operados, buscando señales de artrodosis. La aparición de la cicatrización ósea en cada nivel operado se clasificó como propone Glassman para la artrodosis posterolateral, en cinco categorías: 1) artrodosis sólida bilateral; 2) artrodosis sólida unilateral; 3) artrodosis parcial bilateral; 4) artrodosis parcial unilateral; 5) ausencia de artrodosis. En una segunda etapa, la evaluación de cada nivel operado fue dividida en dos categorías: fusión (tipos 1, 2, 3 y 4) y sin fusión (tipo 5). El análisis estadístico se realizó mediante el cálculo del coeficiente Kappa, teniendo en cuenta el análisis pareado entre los dos observadores experimentados y entre

1. Universidade Estadual de Campinas (UNICAMP), Department of Orthopedics and Traumatology, Campinas, SP, Brazil.
2. Universidade Estadual de Campinas (UNICAMP), Department of Radiology, Campinas, SP, Brazil.

Study conducted in the Spinal Surgery Unit of Universidade Estadual de Campinas (UNICAMP), Campinas, SP, Brazil.

Correspondence: Departamento de Ortopedia e Traumatologia, Área de Cirurgia da Coluna Faculdade de Ciências Médicas, Unicamp. Rua Tessália Vieira de Camargo, 126 Cidade Universitária "Zeferino Vaz" Campinas, SP, Brazil. 13083-887. mrisso@mpc.com.br

los dos observadores en formación. Resultados: La reproducibilidad entre observadores por el coeficiente Kappa para el análisis de la consolidación de la artrodesis en la clasificación propuesta, dividida en 5 categorías, fue 0,729 para ambos cirujanos experimentados y en formación. Considerando solamente las dos categorías, se obtuvo el coeficiente Kappa de 0,745 entre los cirujanos experimentados y 0,795 entre los cirujanos en formación. En todos los análisis se obtuvo un alto poder de concordancia. Conclusión: Se observó reproducibilidad entre observadores con una alta concordancia en la clasificación propuesta por Glassman para artrodesis posterolateral de la columna lumbar y lumbosacra.

Descriptores: Fusión vertebral; Tomografía; Clasificación; Columna vertebral; Reproducibilidad de resultados.

INTRODUCTION

Spinal arthrodesis has been indicated for the treatment of various degenerative pathologies of the lumbar spine, such as scoliosis, spondylolisthesis, and stenosis of the lumbar canal. It is efficient when properly indicated, culminating in improvements in the pain profile and other disabilities that accompany these conditions.¹⁻⁴

These arthrodeses can be performed via anterior, posterior, or combined approaches. The benefits of posterolateral arthrodesis include the familiarity of most surgeons with the technique, its relative ease of execution, the possibility of decompression of the neural elements with resection of the posterior spinal elements, and its high rates of fusion. The association of pedicle instrumentation increases the rigidity of the system and favors consolidation of the arthrodesis.⁵⁻⁷

Although surgical exploration is the gold standard for evaluating the consolidation of arthrodesis, there was a need for reliable, non-invasive methods that could achieve the same objective. Multislice computed tomography with volumetric capture, with its capability for high definition of bone details and its multiplane reconstruction possibilities, has become the method of choice. The systematized analysis of the combination of 6mm tomographic axial cuts and sagittal cuts showed a correlation of 80% with surgical exploration.⁸

Through observations of post-operative computed tomography exams with axial cuts of 1 mm and sagittal and coronal reconstructions, Glassman *et al* established a simple method for the evaluation and quantification of consolidation in posterolateral arthrodesis.⁹

The objective of this study is to evaluate the interobserver agreement in the consolidation of posterolateral arthrodesis of the lumbar spine using the classification proposed by Glassman *et al*,⁹ based on digital tomographic images.

MATERIALS AND METHODS

One hundred and thirty-four computed tomographs of patients in post-operative follow-up for instrumented posterolateral lumbar and lumbosacral arthrodesis for degenerative spine disease at the Spine Surgery Clinic of the Universidade Estadual de Campinas (Unicamp), Campinas, SP, Brazil, were individually analyzed by two spine surgeons, experienced in interpreting post-operative exams using the Glassman classification, and by two surgeons in training, previously trained to perform this same type of analysis.

A total of 134 exams, totaling 299 operated levels, were analyzed using computed tomography images performed on 64-channel equipment, with multislice volumetric capture in the axial plane.

The tomographic images, which included the entire area of the arthrodesis, were reconstructed in a bone window in the sagittal and oblique coronal planes using Arya Píxeon[®] version 1.5.5 software. We defined the oblique coronal plane as the plane perpendicular to the line that passes through the center of the intervertebral disc in the sagittal plane. (Figure 1) The exams were analyzed in systematic form on high resolution monitors with reconstructed images, adjusting the thickness to 3mm in the specific oblique coronal plane of each operated level. (Figure 1) After the evaluation of this reconstructed plane, the analysis was complemented by the reconstruction images in the parasagittal plane, also at a thickness of 3mm. The observation of continuity in the facet joints and/or the formation of a bone bridge were the criteria observed for characterization of the consolidation of the arthrodesis.

Each operated level was classified as a type (numbered from

1 to 5) according to the Glassman classification, as proposed by Laoutiev *et al*:¹⁰ 1) Solid bilateral arthrodesis, 2) Solid unilateral arthrodesis, 3) Partial bilateral arthrodesis, 4) Partial unilateral arthrodesis, and 5) Absence of arthrodesis (Figures 2-7). We considered an image in which we found continuity between the facet joints or posterior elements, with homogeneous texture and without the characterization of joint space between the facet joints, to be solid arthrodesis. We considered an image that showed continuity between the posterior elements persisting, but with an area with less radiopacity in the joint space, to be partial arthrodesis.

The data were analyzed for interobserver agreement by calculating the Kappa coefficient,¹¹ comparing the responses of the two observers experienced in spinal surgery with each other, and the responses of the two observers in training for spinal surgery with each other. Following the evaluation of agreement using the different types proposed by the Glassman classification, the categories of "consolidated" – grouping all the degrees of consolidation, i.e., Glassman types 1, 2, 3, and 4, and "not consolidated", i.e., type 5, were created. The agreement between the two spinal surgeons, and between the two surgeons in training, was checked against this new

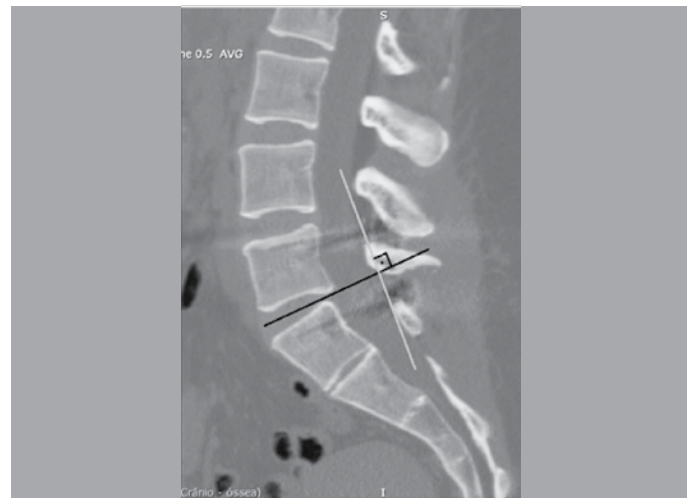

Figure 1. Example of a coronal plane orientation corrected for the evaluation of level L5-S1 (Arya Píxeon[®] version 1.5.5).

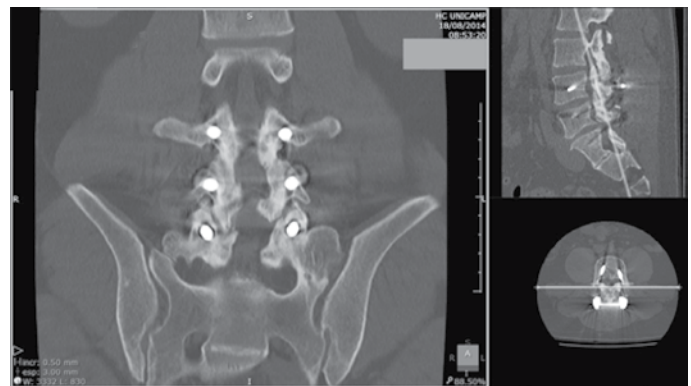


Figure 2. Reconstruction in the frontal plane in the facet joint orientation of level L4-L5 (Arya Píxeon[®] version 1.5.5).

system. The results were interpreted using the criteria established by Landis and Koch.¹²

The study was submitted to and approved by the Research Ethics Committee of the Universidade Estadual de Campinas, SP, Brazil under number 856/2009.

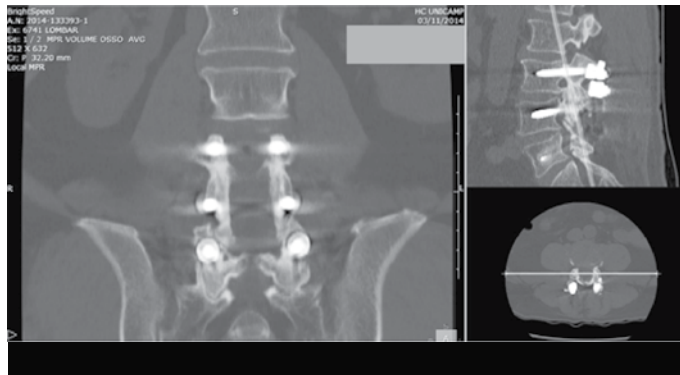


Figure 3. Example classified as consolidation type 1 at level L3-L4 (Arya Pixeon© version 1.5.5).

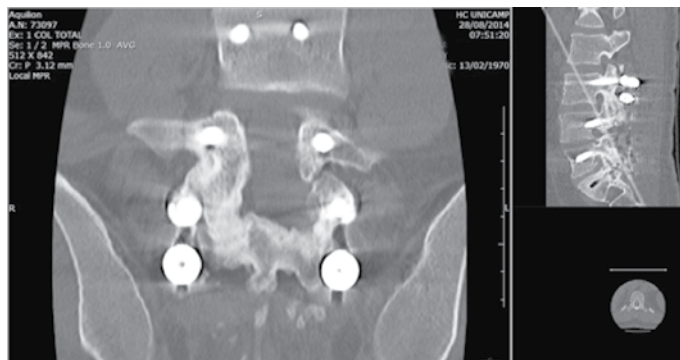

Figure 4. Example of an image classified as consolidation type 2 at level L4-L5 (Arya Pixeon© version 1.5.5).

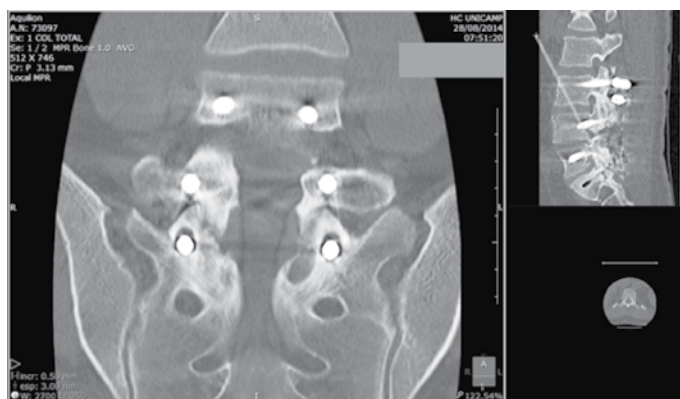

Figure 5. Example of an image classified as consolidation type 3 at level L5-S1 (Arya Pixeon© version 1.5.5).

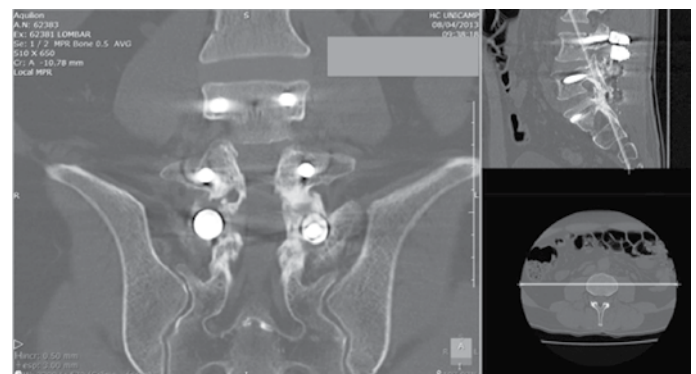


Figure 6. Example of an image classified as consolidation type 4 at level L5-S1 (Arya Pixeon© version 1.5.5).

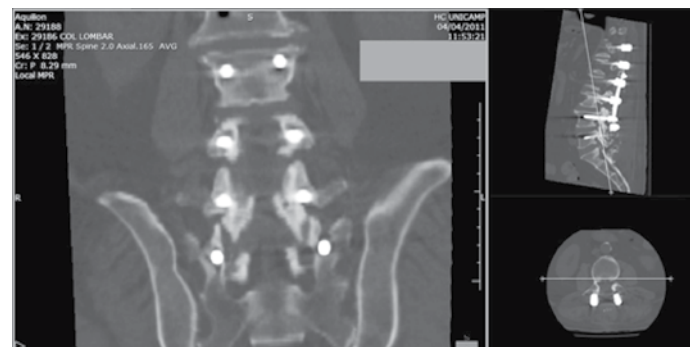

Figure 7. Example of an image classified as type 5 at level L4-L5 (Arya Pixeon© version 1.5.5).

RESULTS

The operated vertebral segments were classified by the four observers, based on the degree of consolidation of the arthrodesis. The agreement between the classifications assigned by the two surgeons and the two surgeons in training was verified using the weighted Kappa coefficient of agreement¹¹ with confidence intervals of 95%.

The agreement was then evaluated taking the “consolidated” and “not consolidated” categories into account. The results of the two spinal surgeons were again compared with each other, as were the results of the two surgeons in training, using the Kappa coefficient with the respective confidence intervals of 95%.

Tables 1 and 2 show that, considering the five types of consolidation classification, the scale showed a similar level of agreement (Weighted Kappa = 0.729) between both the surgeons and the surgeons in training. The value obtained reflects a high level of interobserver agreement, according to the criteria of Landis and Koch.¹²

Tables 3 and 4 show that with the interpretation of the results obtained from the observers by grouping all the different stages of consolidation into one group, and the not consolidated classification into another group, the level of agreement between the surgeons and between the surgeons in training increased slightly (Kappa = 0.745 and Kappa = 0.795, respectively), maintaining a high level of agreement between the pairs of examiners, according to the criteria proposed by Landis and Koch.¹² (Table 5)

Table 1. Description of the types of consolidation between the surgeons and the resulting agreement coefficient.

Surgeon 1	Surgeon 2					Total	Weighted Kappa (CI 95%)
	Solid bilateral arthrodesis	Partial bilateral arthrodesis	Partial unilateral arthrodesis	Artrodesse parcial unilateral	Absence of fusion		
	n (%)	n (%)	n (%)	n (%)	n (%)	n (%)	
Solid bilateral arthrodesis	48 (16.1)	6 (2)	5 (1.7)	0 (0)	0 (0)	59 (19.7)	0.729 (0.674; 0.783)
Solid unilateral arthrodesis	13 (4.3)	38 (12.7)	4 (1.3)	7 (2.3)	10 (3.3)	72 (24.1)	
Partial bilateral arthrodesis	4 (1.3)	2 (0.7)	21 (7)	5 (1.7)	5 (1.7)	37 (12.4)	
Partial unilateral arthrodesis	2 (0.7)	4 (1.3)	6 (2)	24 (8)	12 (4)	48 (16.1)	
Absence of fusion	0 (0)	0 (0)	2 (0.7)	4 (1.3)	77 (25.8)	83 (27.8)	
Total	67 (22.4)	50 (16.7)	38 (12.7)	40 (13.4)	104 (34.8)	299 (100)	

Table 2. Description of the types of consolidation between the interns and the resulting agreement coefficient.

Surgeon in training 1	Surgeon in training 2					Total	Weighted Kappa (CI 95%)
	Solid bilateral arthrodesis	Solid unilateral arthrodesis	Partial bilateral arthrodesis	Partial unilateral arthrodesis	Absence of fusion		
	n (%)	n (%)	n (%)	n (%)	n (%)	n (%)	
Solid bilateral arthrodesis	25 (8.4)	2 (0.7)	0 (0)	0 (0)	0 (0)	27 (9)	0.729 (0.678; 0.781)
Solid unilateral arthrodesis	18 (6)	55 (18.4)	2 (0.7)	3 (1)	0 (0)	78 (26.1)	
Partial bilateral arthrodesis	1 (0.3)	6 (2)	16 (5.4)	2 (0.7)	0 (0)	25 (8.4)	
Partial unilateral arthrodesis	2 (0.7)	27 (9)	7 (2.3)	35 (11.7)	12 (4)	83 (27.8)	
Absence of fusion	0 (0)	0 (0)	1 (0.3)	12 (4)	73 (24.4)	86 (28.8)	
Total	46 (15.4)	90 (30.1)	26 (8.7)	52 (17.4)	85 (28.4)	299 (100)	

Table 3. Description of the re-categorization of the scale between the surgeons and the result of the agreement coefficient.

Surgeon 1	Surgeon 2		Total	Kappa (IC95%)
	Not consolidated	Consolidated		
	n (%)	n (%)	n (%)	
Not consolidated	77 (25.8)	6 (2)	83 (27.8)	0.745
Consolidated	27 (9)	189 (63.2)	216 (72.2)	(0.665; 0.825)
Total	104 (34.8)	195 (65.2)	299 (100)	

Table 4. Description of the re-categorization of the scale between the surgeons and the result of the agreement coefficient.

Surgeon in training 1	Surgeon in training 2		Total	Kappa (IC95%)
	Not consolidated	Consolidated		
	n (%)	n (%)	n (%)	
Not consolidated	73 (24.4)	13 (4.3)	86 (28.8)	0.795
Consolidated	12 (4)	201 (67.2)	213 (71.2)	(0.719; 0.871)
Total	85 (28.4)	214 (71.6)	299 (100)	

Table 5. Classification of the strength of agreement by Kappa coefficient value.

Kappa statistic	Strength of agreement
< 0.20	Slight
0.21 – 0.40	Fair
0.41 – 0.60	Moderate
0.61 - 0.80	Substantial
>0.80	Almost perfect

DISCUSSION

The evaluation of the consolidation of posterolateral arthrodesis of the lumbar spine is of essential importance to clinical practice. The correct interpretation of the clinical findings and complementary exams of patients who have undergone this type of surgery is critical for making therapeutic decisions, such as whether or not to submit the patient to a new procedure.

Although surgical exploration is the method considered to be the gold standard for evaluating the consolidation of posterolateral arthrodesis⁹, non-invasive imaging techniques, such as simple radiography with its different incidences, dynamic radiography, and computed tomography, are used as the basis for evaluation, analysis, and classification of the consolidation of arthrodeses.¹³

Simple radiography, although low cost, is rarely performed alone for the evaluation of consolidation¹³ and its validity for this purpose

has been questioned by various studies.¹⁴⁻¹⁶ Computed tomography is able to provide greater anatomic detail compared to radiography. Visualization of obliteration in the facet joints and bone bridges, for example, is a more suggestive sign that bone fusion has been achieved.¹⁰

In 2005, Glassman *et al*⁹ published a classification system to evaluate the evolution of posterolateral arthrodesis based on 1mm tomographic cuts with sagittal and coronal reconstructions, in order to evaluate consolidation rates in patients submitted to this surgical procedure.

High interobserver agreement is essential for a classification to be disseminated to daily clinical practice. Descriptive classifications with short learning curves are more feasible for this objective.¹⁷⁻¹⁹ Similarly, having a faithful and reproducible classification can be of critical assistance in making decisions about spinal surgery.¹⁸ Classifications that require the evaluation of more exams, more items, and more subjective criteria end up having their applicability compromised.²⁰

Earlier studies, such as that conducted by Rodrigues *et al*¹⁴, obtained disappointing results in their evaluation of the classification proposed by Glassman. That study, performed using tomography with coronal reconstruction and 1 mm cuts, demonstrated low interobserver agreement.^{10,14}

In the present study, the analysis method included prior training and images of tomographic cuts reconstructed at each level in the plane that we call the oblique coronal plane, rather than an analysis of the coronal plane for all levels. We believe that this measure increases the sensitivity of the interpretation of the condition of the fusion, especially at levels with is greater inclination, such as the lumbosacral transition. The analysis was complemented with sagittal cuts to identify the bone bridges and/or obliteration of the facet joints.

We believe that this systematization, coupled with training in the method of analysis and the use of high-resolution digital equipment, allowing perfect windowing and improved reconstruction for each level, are responsible for the high interobserver agreement obtained in our study, contradicting the results of previous studies.

By conducting systematic training, the difference that we had expected to find between the surgeons with several years of experience in this type of analysis, and the surgeons in training with less than six months of contact with the methodology, was eliminated.

Finding a reproducible and systematic method to evaluate the consolidation, or lack thereof, of posterolateral arthrodeses of the lumbosacral spine is important both for clinical practice and for scientific studies seeking to assess the levels of consolidation of arthrodesis. Instrumented posterolateral arthrodesis is still the most popular and the most accessible procedure for the majority of surgeons and spine surgery centers, but one of its main complications is pseudoarthrosis, which is also one of the major motives for arthrodesis revision surgery. Therefore, it is of utmost importance to find a reproducible, reliable, and non-invasive method for diagnosis.

Careful, systematic interpretation of computed tomography, following the guidelines of the Glassman classification, is therefore an important component of the diagnostic arsenal of the spinal

surgeon. This statement is valid both in clinical practice and in the standardization of scientific studies that evaluate the consolidation, or absence of consolidation, of arthrodeses.

CONCLUSION

We observed a high level of interobserver agreement in the classification proposed by Glassman for posterolateral spinal arthrodeses following systematic tomographic interpretation by previously

trained individuals using a digital system. We found no difference in reproducibility between surgeons experienced in the method and recently trained surgeons in training.

All authors declare no potential conflict of interest concerning this article.

REFERENCES

- Phillips FM, Slosar PJ, Youssef JA, Andersson G, Papatheofanis F. Lumbar spine fusion for chronic low back pain due to degenerative disc disease: a systematic review. *Spine (Phila Pa 1976)*. 2013;38(7):E409-22.
- Lykissas MG, Aichmair A. Current concepts on spinal arthrodesis in degenerative disorders of the lumbar spine. *World J Clin Cases*. 2013;1(1):4-12.
- Herkowitz HN, Garfin SR, Eismont FJ, Bell GR, Balderston RA. *Rothman-Simeone: the Spine*. 6th ed. Philadelphia: Saunders; 2011.
- Mirza SK, Deyo RA. Systematic review of randomized trials comparing lumbar fusion surgery to nonoperative care for treatment of chronic back pain. *Spine (Phila Pa 1976)*. 2007;32(7):816-23.
- Kwon BK, Vaccaro AR, Grauer JN, Beiner J. Indications, techniques, and outcomes of posterior surgery for chronic low back pain. *Orthop Clin North Am*. 2003;34(2):297-308.
- Kim HJ, Kim SG, Lee HM, Kim HS, Moon ES, Park JO, et al. Risk factors associated with the halo phenomenon after lumbar fusion surgery and its clinical significance. *Asian Spine J*. 2008;2(1):22-6.
- Tokuhashi Y, Ajiro Y, Umezawa N. Follow-up of patients with delayed union after posterior fusion with pedicle screw fixation. *Spine (Phila Pa 1976)*. 2008;33(7):786-91.
- Carreon LY, Djurasovic M, Glassman SD, Sailer P. Diagnostic accuracy and reliability of fine-cut CT scans with reconstructions to determine the status of an instrumented posterolateral fusion with surgical exploration as reference standard. *Spine (Phila Pa 1976)*. 2007;32(8):892-5.
- Glassman SD, Dimar JR, Carreon LY, Campbell MJ, Puno RM, Johnson JR. Initial fusion rates with recombinant human bone morphogenetic protein-2/compression resistant matrix and a hydroxyapatite and tricalcium phosphate/collagen carrier in posterolateral spinal fusion. *Spine (Phila Pa 1976)*. 2005;30(15):1694-8.
- Laoutliv B, Havsteen I, Bech BH, Narvestad E, Christensen H, Christensen A. Interobserver agreement in fusion status assessment after instrumental desis of the lower lumbar spine using 64-slice multidetector computed tomography: impact of observer experience. *Eur Spine J*. 2012;21(10):2085-90.
- Cohen J. A coefficient of agreement for nominal scales. *Educ Psychol Measur*. 1960;20(1):37-46.
- Landis JR, Koch GG. The measurement of observer agreement for categorical data. *Biometrics*. 1977;33(1):159-74.
- Goldstein C, Drew B. When is a spine fused? *Injury*. 2011;42(3):306-13.
- Rodrigues DG, Coelho JA, Oliveira CEA, Sontoro AG, Trindade RMC, Pereira SAC. Análise da reprodutibilidade intra e inter-observadores das classificações radiográficas para avaliação da artrose da coluna lombar. *Coluna/Columna*. 2008;7(3):257-261.
- Christensen FB, Laursen M, Gelineck J, Eiskjaer SP, Thomsen K, Bünger CE. Interobserver and intraobserver agreement of radiograph interpretation with and without pedicle screw implants: the need for a detailed classification system in posterolateral spinal fusion. *Spine (Phila Pa 1976)*. 2001;26(5):538-43.
- Brodsky AE, Kovalsky ES, Khalil MA. Correlation of radiologic assessment of lumbar spine fusions with surgical exploration. *Spine (Phila Pa 1976)*. 1991;16(Suppl 6):261-5.
- Medeiros RC, Cardoso IM, Jaccard APB, Landim E, Pasqualini W, Veiga IG, et al. Avaliação intra-observador e inter-observadores do Sistema de Classificação de Landim para estenose vertebral lombar. *Coluna/Columna*. 2009;8(1):63-7.
- Risso Neto MI, Jomaa NFA, Landim E, Veiga IG, Cavali PTM, Pasqualini W. Análise da reprodutibilidade intra e interobservadores das classificações de King e Lenke para Escoliose Idiopática do Adolescente. *Coluna/Columna*. 2006;5(2):65-71.
- Godinho RRS, Ueta RHS, Curto DD, Martins DE, Wajchenberg M, Puertas EB. Mensuração da curva escoliótica pela técnica de Cobb intraobservadores e interobservadores e sua importância clínica. *Coluna/Columna*. 2011;10(3):216-20.
- Silva HJS, Risso Neto MI, Pratali RR, Zuiani GR, Cavali PTM, Veiga IG, et al. Avaliação da reprodutibilidade interobservadores de uma nova escala para orientação da conduta terapêutica nas metástases vertebrais: escore SINS (Spine Instability Neoplastic Score). *Coluna/Columna*. 2012;11(4):287-9.