

THE NATURAL HISTORY OF PATIENTS WITH ACUTE DISC HERNIATION: A SERIES OF 150 CASES

A HISTÓRIA NATURAL DE PACIENTES COM HERNIAÇÃO DISCAL AGUDA: UMA SÉRIE DE 150 CASOS

LA HISTORIA NATURAL DE PACIENTES CON HERNIACIÓN DISCAL AGUDA: UNA SERIE DE 150 CASOS

TELMO AUGUSTO BARBA BELSUZARRI,¹ ENRICO AFFONSO BARLETTA,² AUGUSTO RICARDO BARBA URENA,³ DANIEL DE ARAÚJO PAZ,³ FABIO VEIGA DE CASTRO SPARAPANI,³ FRANZ JOOJI ONISHI,³ SERGIO CAVALHEIRO,³ THIAGO SALATI,³ VINICIUS DE MELDAU BENITES,³ ANDREI FERNANDES JOAQUIM,⁴ EDUARDO AUGUSTO IUNES³

1. Pontifícia Universidade Católica de Campinas, Medical School, Neurosurgery Department, Post Graduation Program, Campinas, SP, Brazil.

2. Pontifícia Universidade Católica de Campinas, Medical School, Campinas, SP, Brazil.

3. Universidade Federal de São Paulo, Medical School, Neurosurgery Department, São Paulo, SP, Brazil.

4. Professor of Neurosurgery – Universidade Estadual de Campinas (UNICAMP).

ABSTRACT

Objective: This study aims to analyze the characteristics of patients with acute lumbar/sciatic disc herniation who underwent conservative, pain block procedures and surgical treatment, in order to better understand the natural history of herniations and their surgical indications, as well as the impact of hernia volume. **Methods:** We analyzed 150 patients with a diagnosis of acute lumbar disc herniation. The treatments considered were: conservative, infiltration/pain block procedures and microdiscectomy. For seven patients who were surgically treated, the lumbar sequestrectomy volume was submitted to pathological analysis. **Results:** Of the 150 patients, 80% were treated conservatively; 15.31% were treated with pain block procedures and 4.66% underwent microdiscectomy. The mean age of the surgical group was 42.5 years, and 57.1% of the patients were men. Most of the hernias were at L5-S1 (55.5%), and 77.7% were on the left side. All patients had presented significant lumbar pain or sciatica for a long period prior to the surgery. The Lasègue sign was present in all patients. Of the total number of patients, 85.7% presented hypoesthesia and 42.8% presented focal motor deficits, among other findings. The mean hernia volume was 9.6 cm³. **Conclusions:** Unresponsiveness to conservative treatment is an important indication for surgery. The clinical manifestations in patients with a lumbar/sciatic hernia can be very diverse, as can the disc herniation volume, so these are not good indicators for surgery. **Level of evidence IV; Case series**

Keywords: Intervertebral Disc; Hernia; Natural History; Lumbosacral Region; Epidemiology.

RESUMO

Objetivo: O presente estudo tem como objetivo analisar as características dos pacientes com hérnia de disco lombar/ciática aguda que passaram por procedimentos conservadores, procedimentos de bloqueio de dor e tratamento cirúrgico, a fim de melhor entender a história natural das hérnias e suas indicações cirúrgicas, assim como o impacto do volume da hérnia. **Métodos:** Analisamos 150 pacientes diagnosticados com hérnia de disco lombar aguda. Os tratamentos considerados foram: tratamento conservador, procedimentos para bloqueio da dor/infiltração e microdiscectomia. Para sete pacientes tratados cirurgicamente, o volume de sequestrectomia lombar foi enviado para análise patológica. **Resultados:** Dos 150 pacientes analisados, 80% foram tratados de modo conservador, 15,31% com procedimentos de bloqueio da dor e 4,66% com microdiscectomia. A idade média do grupo submetido à cirurgia foi 42,5 anos, sendo que 57,1% dos pacientes eram homens. A maior parte das hérnias estavam localizadas em L5-S1 (55,5%) e 77,7% das hérnias estavam no lado esquerdo. Todos os pacientes apresentaram significativa dor lombar ou ciática por um longo período antes da cirurgia. O sinal de Lasègue estava presente em todos pacientes. Do número total de pacientes, 85,7% apresentaram hipoestesia e 42,8% apresentaram déficits motores focais, entre outros achados. O volume médio das hérnias foi 9,6 cm³. **Conclusões:** A falta de resposta ao tratamento conservador é uma importante indicação para cirurgia. As manifestações clínicas dos pacientes com hérnia lombar/ciática podem ser muito diversas, assim como o volume da hérnia de disco, portanto, esses não são bons indicadores para cirurgia. **Nível de evidência IV; Série de casos.**

Descritores: Disco Intervertebral; Hérnia; História Natural; Região Lombossacral; Epidemiologia.

RESUMEN

Objetivo: El presente estudio tiene como objetivo analizar las características de los pacientes con hernia de disco lumbar/ciática aguda que pasaron por procedimientos conservadores, procedimientos de bloqueo de dolor y tratamiento quirúrgico, a fin de entender mejor la historia natural de las hernias y sus indicaciones quirúrgicas, así como el impacto del volumen de la hernia. **Métodos:** Análizamos a 150 pacientes diagnosticados con hernia de disco lumbar aguda. Los tratamientos considerados fueron: conservador, procedimientos para bloqueo de dolor/infiltración y microdiscectomía. Para siete pacientes tratados quirúrgicamente, el volumen de sequestrectomía lumbar fue enviado para análisis patológico. **Resultados:** De los 150 pacientes analizados, 80% fue tratado de modo conservador, 15,31% con procedimientos de bloqueo de dolor y 4,66% con microdiscectomía. La edad promedio del grupo sometido a cirugía fue de 42,5 años, siendo

Study conducted at the AACD – São Paulo. Av. Professor Ascendino Reis, 724 - Ibirapuera, São Paulo, SP, Brazil. 04027-000

Correspondence: Telmo Augusto Barba Belsuzarri. Rua Eduardo Lane, 422, Guanabara, Campinas, SP, Brazil. 13073002. telmobeluzarri@hotmail.com



<http://dx.doi.org/10.1590/S1808-185120201902224169>

que 57,1% de los pacientes eran hombres. La mayor parte de las hernias estaban localizadas en L5-S1 (55,5%) y 77,7% de las hernias estaban en el lado izquierdo. Todos los pacientes presentaron dolor lumbar o ciático significativo por un largo período antes de la cirugía. La señal de Lasègue estaba presente en todos los pacientes. Del número total de pacientes, 85,7% de los pacientes presentó hipostesia y 42,8% presentó déficits motores focales, entre otros hallazgos. El volumen promedio de las hernias fue de 9,6 cm³. Conclusiones: La falta de respuesta al tratamiento conservador es una importante indicación para la cirugía. Las manifestaciones clínicas de los pacientes con hernia lumbar/ciática pueden ser muy diversas, así como el volumen de la hernia de disco, por lo tanto, éstos no son buenos indicadores para cirugía. **Nivel de evidencia IV; Serie de casos.**

Descriptores: Disco Intervertebral; Hernia; Historia Natural; Región Lumbosacra; Epidemiología.

INTRODUCTION

Lumbar pain is a prevalent condition and a common cause of work absenteeism. According to Nascimento et al.¹ it affects approximately 11.9% of the world's population. In Brazil, spinal pain is the second most prevalent health condition, affecting 13.5% of the population, and it represents an important economic burden worldwide. Low back pain has various etiologies, and it is common for patients with this condition to continue without any specific diagnosis. There are various risk factors and conditions that can lead to this type of pain, even where there is no anatomical damage. These include: age, sex, income, level of education, health status, smoking, eating habits, sedentary lifestyle, lifting heavy loads, and repetitive movements. Nascimento et al.¹, following a systematic review in which they analyzed 18 articles, reported interesting data resulting from a pairwise comparison of Brazilian regions, in which they demonstrated that lower social class, low level of education, obesity, sedentary lifestyle, high levels of stress, and sustained unhealthy postures could be important risk factors.¹⁻⁶

These varied risk factors influence the generation of certain anatomical modifications that can lead to the onset of low back pain. One such modification is lumbar/sciatic disc herniation which, according to Delgado-López et al.,³ is responsible for 85% of all cases of low back pain, with patients being predominantly aged 40 to 50 years. Disc herniation causes compression of the spine or nerve roots, what usually leads to dermatomal pain radiating to the lower limbs. There are other important symptoms, such as: lameness, paresthesia, positive Lasègue sign, inability to stand up straight or to lift heavy objects, and stooping and walking difficulty (e.g. spinal sagittal imbalance).^{3,4} Together with this compression there are also an inflammatory process that contributes to the onset of neuritis and other symptoms. The vast majority of patients recover without surgical intervention; therefore, conservative treatment is usually indicated. Natural regression of the hernia is more common in extruded hernias than protruding ones. Surgery is elected in patients with severe neurological deficit, or in those who continue to present significant pain despite drugs or physical therapy. Surgical treatment and conservative treatment are both reasonable options for patients. No differences were found between earlier or later surgery. The treatment option depends on the patient's condition (age and comorbidities) and the severity of the symptoms. Cauda equina syndrome is a special condition where surgery is absolutely indicated. Regarding the surgical technique, Delgado-López et al.³ present robust data showing that there is no statistical significance in the outcome of classical discectomy compared to microdiscectomy.³ Huysmans et al.,⁵ in their systematic review, report a slight advantage in relation to return to work rates for the microdiscectomy group when compared to the classical discectomy group.⁵ This finding is supported by Overdeest et al.,¹⁰ who report shorter recovery times for microdiscectomy. However, the important point in the care of patients with hernia is whether to indicate surgery, not the technique itself.³

Liang et al.⁴ analyzed 25 patients with spinal sagittal imbalance. Of these, 4% had a disc herniation located at L1-L2, 24% at L3-L4, 52% at L4-L5 and 20% at L5-S1. All these patients failed to recover with conservative treatment, and all underwent a selective discectomy through the transforaminal percutaneous approach, using direct endoscopic visualization. After surgery, there was a

significant improvement in many of the group's parameters, including: anterior translation of the C7 plumb line, loss of lumbar lordosis, thoracic kyphosis and sacral slope, restoration of sagittal balance, greater recruitment potential of spinal musculature, pain relief, and improvement in quality of life. These results show that the surgery significantly improved the patients' spinal sagittal balance. Therefore, the presence of spinal sagittal imbalance, together with other indicators for this condition (such as back/paraspinal muscles weakness) may be good indicators for surgery in patients with disc herniation.⁴

Camino Willhuber et al.,⁷ report that patients with disc herniation are usually aged between 30 and 50 years, and that the disease is twice as common in men than in women. They also state that the most commonly affected levels are L4-L5 and L5-S1. Surgical treatment is not always successful, as some patients present a recurrence of the hernia. The authors analyzed 177 patients who underwent a microdiscectomy: 62% men and 38% women, with a mean age of 49.5 years. Of those patients, 30 (17%) presented a recurrence of the disc herniation, and of these, 90% were re-operated. The authors found no significant statistical difference in relation to the patients' age, sex, body mass or type of hernia (extrusion, protrusion or sequestration). However, there was a significant difference in relation to rate of occupation of the canal by the disc, facet degeneration, and intervertebral disc height. Wang et al.⁸ report the case of a man who presented two recurrences after a percutaneous discectomy. The patient presented some of the risk factors for recurrence mentioned above, such as: higher intravertebral spaces, spinal canal occupancy and Modic change. Therefore, minimally invasive treatments may be a bad choice for these patients, as non-fusion surgeries can result in recurrence.

METHODS

All patients gave consent to take part in this study. However, given that this study was based solely on data from medical records, our institution did not require an informed consent form to be signed by the patients. They were treated between February 2018 and February 2019, at a tertiary hospital in São Paulo, Brazil, that is a reference in spine surgery and neurosurgery. This was an observational, retrospective cohort study.

A literature review was performed of articles in the PUBMED database published from 2008 to 2018, in English or Spanish. The search terms Disc, Herniation, Natural, History, Lumbar and Epidemiology were used. A total of 39 articles were retrieved, but only 10 contained data of interest for the compilation of our results, as we only used articles that discussed lumbar or sciatic disc herniation. The patient's characteristics were determined; clinical presentation; surgical approach, hernia volume, and location of the hernia.

All the patients treated conservatively received physical therapy, acupuncture and medical treatment. Medical treatment consisted of neuropathic pain modulators, pain modulators and opioids. All the patients treated conservatively did not have any motor deficits. The patients that were refractory to initial treatment underwent pain block procedures with facet joint and foraminal procedures. After 3 months, if still refractory, the patients underwent surgery. If a patient presented neurological deficits, they were considered for surgery.

RESULTS

After checking the medical records of 750 patients, our group identified 150 patients with acute disc herniation. Of these, 120 (80%) were treated conservatively; (15.31%) received combined conservative treatment and facet/foraminal analgesia and seven (4.66%) underwent a microdiscectomy after failure of conservative treatment. Of the latter group, anatomopathological analysis of the removed disc hernia was performed in all seven patients, in order to assess the segment volume. These patients are analyzed and discussed in more depth in this article. The data are shown in Table 1.

The group analyzed here is a good population for analyzing the characteristics of patients with disc herniation who are submitted to surgery. In our study, microdiscectomy was the technique utilized. All our patients presented significant clinical limitations and usually, excruciating pain, having tried conservative treatment without success before the indication for surgery. The mean age of this group was 42.5 years; four (57.1%) patients were men and three (42.9%) were women.

The patients presented a total of 9 hernias that were treated surgically. In regard to vertebral location, there was one (11.1%) L3-L4 hernia, three (33.3%) L4-L5 hernias and five (55.5%) L5-S1 hernias. Seven (77.7%) hernias were at the left side and only two (22.3%) were on the right side. All the patients had presented significant lumbar pain or sciatica, for long periods, prior to the surgery. The mean time of pain after surgery was 6.3 months. The Lasègue sign was present in all patients. Only one patient presented no focal deficits; the others presented hypoesthesia in the nerve root territory. Three (42.8%) patients presented focal motor deficits. One patient presented pain on moving the trunk, and one patient presented neurological lameness. The mean hernia volume was 9.6 cm³ (ranging from 1.05 cm³ to 22.23 cm³).

All seven patients of the surgical group had been considered for initial pain block procedures before being submitted to surgery. Three of the seven patients were considered for surgery due to motor deficits, and four after three months of refractory pain block procedure.

DISCUSSION

Analysis of our cohort shows the diversity of characteristics of patients submitted to surgery for disc herniation. Most of our findings agreed with the literature, i.e. we found that the disease is more prevalent in men, and the mean age of our patients was between 30 and 50 years, corroborating the findings of Delgado-López et al.,³ Camino Willhuber et al.⁷ and Fjeld et al.,⁹ who reported an average age of 45 years and a 1.3-fold greater prevalence of men, after analyzing 35.374 patients who underwent surgical treatment. In terms of location, Liang et al.⁴ and Camino Willhuber et al.⁷ reported a predominance of hernias in L4-L5 and in L5-S1, and this was corroborated by our findings (33.3% in L4-L5 and 55.5% in L5-S1).

Delgado-López et al.³ and Liang et al.⁴ report a diversity of clinical manifestations in patients with lumbar/sciatic hernias. These include dermatomal pain radiating to the lower limbs, lameness, paresthesia, a usually positive Lasègue sign, inability to stand up straight or lift heavy objects, and stooping with walking difficulty. Our findings also agreed with these data; 100% of our patients presented a positive Lasègue sign, 85.7% presented hypoesthesia in the affected nerve territory, 42.8% presented paresis, 14.2% presented pain in axial movements and 14.2% presented lameness. Given that patients may present a range of significant and/or refractory symptoms, the clinical manifestations are probably a poor indicator for surgery.

Our unique data was the measurement of the herniated disc volume. We found a significant variation among patients, with volumes ranging from 1.05 cm³ to 22.23 cm³, as shown in Figure 1. Therefore, disc herniation volume is also a poor indicator for surgery.

Our study presents the main characteristics of patients submitted to surgical treatment, demonstrating that clinical characteristics and disc hernia volume are not ideal factors on which to base the surgical indication. This reminds us of the importance of good surgical indication and the limited usefulness of these characteristics, as shown by Delgado-López et al.³ and corroborated by our data, given that we only operated on 8.8% of our patients with lumbar/sciatic disc herniation.

Table 1. Baseline characteristics and summary of the operative cases.

| Patient | Date of evolution | Age | Hernia level | Symptoms | Levels impaired | Hernia volume |
|----------|-------------------|-----|----------------------------|---|-------------------|-----------------------|
| A.C.L. | 03/27/2019 | 46 | L5-S1 - Left - extrusion | Intense lumbar pain in the last 8 months | S1 - Left | 1.05 cm ³ |
| | | | | Facet Pain | | |
| | | | | Lasègue + | | |
| | | | | No Deficits | | |
| G.S.T.H. | 10/22/2018 | 37 | L4-L5 - Left - Extrusion | Lumbar pain and sciatica in the last 10 months | L5 - Left | 4.6 cm ³ |
| | | | | Hypoesthesia in L5 territory | | |
| | | | | Lasègue + | | |
| | | | | Intense Left Sciatica | | |
| I.P.H. | 03/16/2018 | 50 | L5-S1 - Left - Extrusion | Left Sciatica in the last 4 months | S1 - Left (major) | 6.0 cm ³ |
| | | | | Lasègue + | L5 - Left (minor) | |
| | | | | Hypoesthesia in S1 territory | | |
| | | | | Grade IV Paresis for left plantar flexion | | |
| P.M.T. | 04/30/2019 | 30 | L5-S1 - Left - Extrusion | Lumbar pain and sciatica in the last month | S1 - Left | 7.13 cm ³ |
| | | | | Hypoesthesia in S1 territory | | |
| | | | | Lasègue + | | |
| | | | | Grade III Paresis in S1 territory | | |
| P.A.P. | 09/20/2018 | 45 | L4-L5 - Right - Extrusion | Lumbar pain and sciatica in the last 6 months | L5 - Right | 16.2 cm ³ |
| | | | L5-S1 - Right - Protrusion | Hypoesthesia in L5 territory | | |
| | | | | Lasègue + | | |
| | | | | Neurological Lameness | | |
| R.F.P.B. | 02/12/2019 | 37 | L5-S1 - Left - Extrusion | Lumbar pain and intense sciatica in the last 3 months | S1 - Left | 22.23 cm ³ |
| | | | | Hypoesthesia in S1 territory | | |
| | | | | Paresis in S1 territory | | |
| | | | | Lasègue + | | |
| G.B. | 09/19/2018 | 53 | L3-L4 - Left - Extrusion | Intense lumbar pain in the last year | L3-L4-L5 - Left | 10.36 cm ³ |
| | | | L4-L5 - Left - Extrusion | Lasègue + | | |
| | | | | Hypoesthesia in L3-L4-L5 territory | | |
| | | | | Pain in trunk flexion and extension | | |

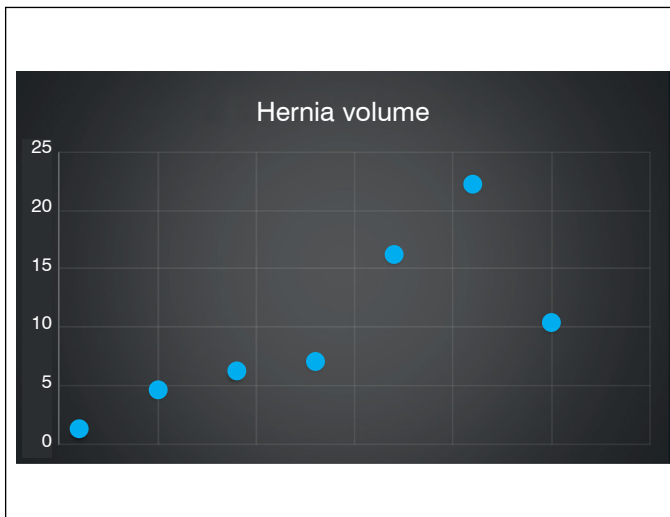


Figure 1. Hernia volume of the operative cases.

CONCLUSION

Patients with lumbar/sciatic disc herniation have some classic characteristics that were corroborated with our findings, such as a mean age of between 40 to 50 years, a greater prevalence of men, and a prevalence of hernias at L4-L5 and L5-S1. The varied clinical presentation is, in itself, an important characteristic, and the decision on whether or not to indicate surgery in these patients is a very important aspect of the patient care. Surgery should only be indicated with caution, and only for a minority of patients. Unresponsiveness to conservative treatment is an important indication for the surgery. Clinical manifestations and disc hernia volume in patients with lumbar/sciatic hernia can be very diverse, and are not, therefore, good indicators for surgery.

Disclosures: None

Limitations: We analyzed a very small group of patients. Due to this small cohort, we were unable to compile statistical data.

All authors declare no potential conflict of interest related to this article.

CONTRIBUTION OF THE AUTHORS: Each author made significant individual contributions to this manuscript. TABB, EAB, ARBU: writing, revision and performing the surgical procedures; FJO, TS, VMB: surgical procedures, data analysis and writing; SC: statistical analysis, surgical procedures and revision; FVCS: analysis of the slides, and revision; DAP: writing, revision and intellectual concept; EAI, TABB: surgical procedures, writing, statistical analysis, intellectual concept and preparation of the whole research project.

REFERENCES

- Nascimento PRC, Costa LOP. Low back pain prevalence in Brazil: a systematic review. *Cad Saúde Pública*. 2015;31(6):1141-56.
- Perolat R, Kastler A, Nicot B, Pellat JM, Tahon F, Attye A, et al. Facet joint syndrome: from diagnosis to interventional management. *Insights Imaging*. 2018;9(5):773-89.
- Delgado-López PD, Rodríguez-Salazar A, Martín-Alonso J. Lumbar disc herniation: Natural history, role of physical examination, timing of surgery, treatment options and conflicts of interests. *Neurocirugía (Astur)*. 2017;28(3):124-34.
- Liang C, Sun J, Cui X, Jiang Z, Zhang W, Li T. Spinal sagittal imbalance in patients with lumbar disc herniation: its spinopelvic characteristics, strength changes of the spinal musculature and natural history after lumbar discectomy. *BMC Musculoskelet Disord*. 2016;17:305.
- Huysmans E, Goudman L, Van Belleghem G, De Jaeger M, Moens M, Nijs J, et al. Return to work following surgery for lumbar radiculopathy: a systematic review. *Spine J*. 2018;18(9):1694-714.
- Dagenais S, Caro J, Haldeman S. A systematic review of low back pain cost of illness studies in the United States and internationally. *Spine J*. 2008;8(1):8-20.
- Camino Willhuber G, Kido G, Mereles M, Bassani J, Petracchi M, Elizondo C, et al. Factors associated with lumbar disc hernia recurrence after microdiscectomy. *Rev Esp Cir Ortop Traumatol*. 2017;61(6):397-403.
- Wang Y, Ning C, Xu F, Xiang Y1, Yao L2, Liu Y1, et al. Recurrent lumbar disc herniation recurrence after percutaneous endoscopic lumbar discectomy: A case report. *Medicine (Baltimore)*. 2018;97(34):e11909.
- Fjeld OR, Grøvre L, Helgeland J, Småstuen MC, Solberg TK, Zwart JA, et al. Complications, reoperations, readmissions, and length of hospital stay in 34 639 surgical cases of lumbar disc herniation. *Bone Joint J*. 2019;101-B(4):470-7.
- Overdeest GM, Peul WC, Brand R, Koes BW, Bartels RH, Tan WF, et al. Tubular discectomy versus conventional microdiscectomy for the treatment of lumbar disc herniation: long-term results of a randomised controlled trial. *J Neurol Neurosurg Psychiatry*. 2017;88(12):1008-16.