

CERVICAL ANTERIOR ARTHRODESIS: AUTOLOGOUS OR SYNTHETIC GRAFT?

ARTRODESE CERVICAL VIA ANTERIOR: ENXERTO AUTÓLOGO OU SINTÉTICO?

ARTRODESIS CERVICAL ANTERIOR: ¿INJERTO AUTOLOGO O SINTÉTICO?

ELEONOR JOSÉ SOLIGO JÚNIOR¹ , ÁLYNSON LAROCCA KULCHESKI² , PEDRO GREIN DEL SANTORO² , MARCEL LUIZ BENATO² , XAVIER SOLER I GRAELLS^{1,2} ,
ANDRÉ LUÍS SEBBEN² , FELIPE DE NEGREIROS NANNI² 

1. Universidade Federal do Paraná (UFPR), Hospital do Trabalhador, Ortopedia y Traumatología, Departamento de Cirugía de Columna, Curitiba, PR, Brazil.
2. Hospital do Trabalhador, Universidade Federal do Paraná (UFPR), Curitiba, PR, Brazil.

ABSTRACT

Objective: To compare patients who underwent anterior cervical arthrodesis with autologous iliac crest graft and those who used synthetic graft. **Methods:** Analysis of 38 patients aged between 18 and 100 years with anterior cervical spondylosis of 1 or 2 levels in a spine surgery service. **Inclusion:** degenerative cervical spine changes associated with cervicgia and cervicobrachialgia. **Excluded:** previous cervical spine surgeries, fractures, or surgery above two levels. Two groups were formed with 19 patients, one using autologous graft and the other using synthetic tricalcium phosphate - a questionnaire assessed satisfaction (Oswestry and VAS) pre- and postoperatively. Bone consolidation was evaluated by tomography at nine months. **Results:** Mean ODI (Group 1) was $68.5\% \pm 4.6\%$ preoperatively and $27.2\% \pm 3.8\%$ postoperatively, being statistically relevant ($p < 0.001$). VAS performed to evaluate the cervical region, Group 1 pre and post-op was considered statistically relevant ($p < 0.001$). No significant difference was observed when comparing the mean values found in the postoperative period between Group 1 and Group 2 ($p = 0.463$). Only two patients complained of chronic pain, representing 10% of the total. In nine-month tomography, 100% of patients in Group 1 and 100% of Group 2 showed bone consolidation, with no statistically relevant difference ($p = 0.676$) between the groups. **Conclusion:** Similar functional and osteointegration outcomes were observed in both types of grafts. Synthetic graft minimizes the risks and complications of using allografts. **Level of Evidence III; Retrospective comparative study.**

Keywords: Spine; Spinal Fusion; Arthrodesis; Chronic Pain.

RESUMO

Objetivo: Comparar os pacientes que realizaram artrodese cervical anterior associada ao uso de enxerto autólogo de crista íliaca e os que utilizaram enxerto sintético. **Métodos:** Análise de 38 pacientes entre 18 e 100 anos com espondilose cervical anterior de nível 1 ou 2 em um serviço de cirurgia da coluna. **Inclusão:** alterações degenerativas da coluna cervical, associado a cervicgia e/ou cervicobraquialgia. **Excluídos:** cirurgias de coluna cervical prévia, fraturas ou cirurgia acima de 2 níveis. Foram formados 2 grupos com 19 pacientes cada, sendo num deles utilizado enxerto autólogo e, no outro, sintético fosfato tricálcico. Foi aplicado o questionário para avaliação de satisfação (Oswestry e EVA) pré e pós-operatória. **Consolidação óssea foi avaliada por tomografia no nono mês. Resultados:** O ODI médio do Grupo 1 apresentou $68,5\% \pm 4,6\%$ na avaliação pré-operatória e $27,2\% \pm 3,8\%$ no pós, sendo estatisticamente relevante ($p < 0,001$). EVA realizada para avaliar a região cervical, o Grupo 1 no pré e pós foi considerada estatisticamente relevante ($p < 0,001$). Não foi observada diferença relevante quando comparando os valores médios encontrados no pós-operatório entre o Grupo 1 e o Grupo 2 ($p = 0,463$). Apenas 2 pacientes com queixa de dor crônica, representando 10% do total. Tomografia de 9 meses, 100% dos pacientes do Grupo 1 e 100% do Grupo 2 apresentaram consolidação óssea, não tendo diferença estatisticamente relevante ($p = 0,676$) entre os grupos. **Conclusão:** Foram observados resultados funcionais e de osteointegração similares em ambos enxertos. O enxerto sintético minimiza riscos e complicações do uso de aloenxertos. **Nível de Evidência III; Estudo Retrospectivo Comparativo**

Descritores: Coluna Vertebral; Fusão Vertebral; Artrodese; Dor Crônica.

RESUMEN

Objetivo: Comparar los pacientes sometidos a artrodosis cervical anterior asociada al uso de un injerto autólogo de cresta íliaca y los que utilizaron un injerto sintético. **Métodos:** Se analizaron 38 pacientes de entre 18 y 100 años con espondilosis cervical anterior de nivel 1 o 2 en un servicio de cirugía de la columna vertebral. **Criterios de inclusión:** cambios degenerativos en la columna cervical, asociados a cervicgia y/o cervicobraquialgia. **Excluidos:** cirugía previa de la columna cervical, fracturas o cirugía por encima de 2 niveles. Se formaron dos grupos de 19 pacientes cada uno, en uno se utilizó un injerto autólogo y en el otro un injerto sintético de fosfato tricálcico. Se utilizó un cuestionario de satisfacción pre y postoperatorio (Oswestry y EVA). La consolidación ósea se evaluó mediante tomografía computarizada al noveno mes. **Resultados:** La media del ODI del Grupo 1 fue del $68,5\% \pm 4,6\%$ en la valoración preoperatoria y del $27,2\% \pm 3,8\%$ en la valoración postoperatoria, siendo estadísticamente relevante ($p < 0,001$). La EVA realizada para valorar la región cervical en el Grupo 1 pre y post se consideró estadísticamente significativa ($p < 0,001$). No se observaron diferencias relevantes al comparar los valores medios

Study conducted by the Hospital do Trabalhador, Universidade Federal do Paraná (UFPR), Curitiba, PR, Brazil.

Correspondence: Eleonor José Soligo Junior. 185, Felipe Schmidt Street, Criciúma, Santa Catarina, Brazil. 88811504. eleonorsoligo@gmail.com



encontrados en el postoperatorio entre el Grupo 1 y el Grupo 2 ($p=0,463$). Sólo 2 pacientes se quejaron de dolor crónico, lo que representa el 10% del total. A los 9 meses, el 100% de los pacientes del Grupo 1 y el 100% del Grupo 2 presentaban cicatrización ósea, sin diferencias estadísticamente significativas ($p=0,676$) entre los grupos. Conclusión: Se observaron resultados funcionales y de osteointegración similares con ambos injertos. El injerto sintético minimiza los riesgos y complicaciones del uso de aloinjertos. **Nivel de Evidencia III; Estudio Retrospectivo Comparativo.**

Descriptor: Columna Vertebral; Fusión Vertebral; Artrodesis; Dolor Crónico.

INTRODUCTION

As the population ages, there is an increase in the occurrence of degenerative diseases in the cervical spine. Advances in medicine have contributed to a greater diagnosis of these pathologies, significantly increasing spinal interventions.¹ In the United States, for example, there was a 150% increase in spinal surgeries between 1990 and 2013.²

The main indications for cervical spine surgery are disc disease, foraminal and spinal canal stenosis, and spondylolisthesis. The most commonly used surgical techniques are arthrodesis with anterior and posterior decompression using implants associated with autologous and synthetic grafting.³

The autologous iliac graft is the gold standard for anterior cervical arthrodesis due to its osseointegration, osteogenesis, and osteoconductivity capacity.^{4,5} The iliac graft removal procedure carries risks of complications such as bleeding, neurological damage, iliac bone fractures, scarring, infection, and chronic pain.^{1,6,7} Pain complaints at the donor site can occur in 37% to 60% of patients and can become chronic.^{8,9}

The desire to reduce these complications has led to the study and development of synthetic grafts. These have a low potential for infection and good immunological acceptance, as well as reducing surgical time and hospitalization.^{10,11} Tricalcium phosphate has been used since 1982, and its composition resembles cancellous bone. Its porosity can increase osteogenesis and capillary pathways for bone remodeling.^{12,13}

This study compares the clinical outcome, complications, and bone healing rate between patients who underwent anterior arthrodesis and discectomy associated with autologous iliac crest grafts versus those who used synthetic tricalcium phosphate grafts.

METHODOLOGY

This is a retrospective, longitudinal, controlled study. It was carried out in a tertiary hospital, a reference in treating spinal pathologies. The Research Ethics Committee approved the work under the number 65254621300005225.

Patients between the ages of 18 and 100 who had refractory cervicobrachialgia for at least six months after conservative treatment and who had been diagnosed with cervical degenerative pathologies confirmed by imaging tests such as X-rays and MRI were included. The patients were indicated for anterior cervical arthrodesis and decompression of one or two levels, depending on their underlying pathology. The patients were divided into two groups with the same number of patients. Those who underwent cervical arthrodesis with an autologous iliac crest graft were considered the control group or Group 1, and those who underwent cervical arthrodesis using a synthetic tricalcium phosphate graft made up Group 2 or the case group.

The exclusion criteria were patients with previous cervical spine surgery, non-degenerative cervical spine diseases such as fractures, infections, or tumors, active smokers, surgery on more than two levels, under 18 years of age or over 100 years of age, and those who did not agree to take part in the study.

The surgical procedure was carried out using the anterior cervical approach described by Smith & Robinson, using self-locking polyether ether ketone (PEEK) cages with three screws. In Group 1, a graft was taken from the patient's left iliac crest as the graft donor area. A synthetic tricalcium phosphate graft (Attrax-NuVasive®) was used to fill the intersomatic spacer in the Group 2.

The Visual Pain Scale (VAS)¹⁴ and Oswestry 2.0¹⁵ questionnaires

were used to assess satisfaction with the surgery in the preoperative, third, and ninth postoperative months. During the patients' outpatient follow-up, anteroposterior and lateral radiographs of the cervical spine were taken preoperatively and repeated at 3, 6, and 9 months postoperatively, using this examination to assess whether subsidence or migration of the implants had occurred. A CT scan with 2 mm slices and coronal, sagittal, and axial views was carried out in the ninth postoperative month to assess whether there had been bone healing, determined as the presence of trabecular bone seen through the intersomatic spacer connecting the upper and lower vertebral plateaus, according to the current protocol used in this service. In the ninth month, dynamic flexion-extension radiographs were taken to assess the distance between the spinous processes, using the midpoint between the spinous processes and the processes of the adjoining vertebrae. A gap >2mm from the spinous processes on dynamic radiography was also considered a criterion for bone non-consolidation. Radiolucency at the implant-bone interface, as seen in CT scans or X-rays, also confirmed the absence of fusion. Two experienced spine surgeons analyzed the imaging exams in a blind, randomized, and individual manner.

Complications related to the donor area in Group 1 were assessed on the patient's first return to the clinic through anamnesis and physical examination. Sensitivity was tested on the lateral aspect of the left thigh (lateral femoral cutaneous nerve), and the presence of deformities, hematomas, suture dehiscence, or phlogistic signs was checked. Chronic pain was considered when it was present for more than three months at the graft donor site. The VAS for iliac pain was assessed in all patients in Group 1 in the third and ninth months after surgery.

The variables evaluated were presented in tables with absolute and relative frequency distribution. The normality of the variables was assessed using the Shapiro-Wilk test, and the associations were assessed using Pearson's chi-square test or Fisher's exact test when necessary. The statistical significance of the differences in means between the quantitative variables was verified using the paired and unpaired Student's t-test. All the analyses were carried out at a significance level of 5%, and the results were considered statistically significant when the *p-value* was less than 0.05.

RESULTS

Initially, 100 patients undergoing anterior cervical arthrodesis were selected. After applying the exclusion criteria, 38 patients were included in the study. They were paired 19 in each group. The patients excluded from the study are listed in the flowchart below. (Figure 1)

Most of the patients assessed were female, both in Group 1 (68.4%) and Group 2 (63.1%), with no significant difference ($p=0.732$). The average age of Group 1 was 54 years (48 to 71 years), while the average age of the second group was 56 years (56 to 75 years).

The control group had an average ODI of 68.5%, while Group 2 had an average of 69.8% preoperatively. There was no statistical difference between the two groups in the preoperative ODI assessment ($p=0.373$). The preoperative VAS scale in Group 1 was 7.8 versus 8.0 in Group 2. There was no statistically significant difference between the groups ($p=0.527$). (Table 1)

In the evaluation nine months after the surgical procedure, the average ODI (Table 2) in Group 1 was 27.2%, a statistically significant decrease compared to the preoperative period ($p<0.001$).

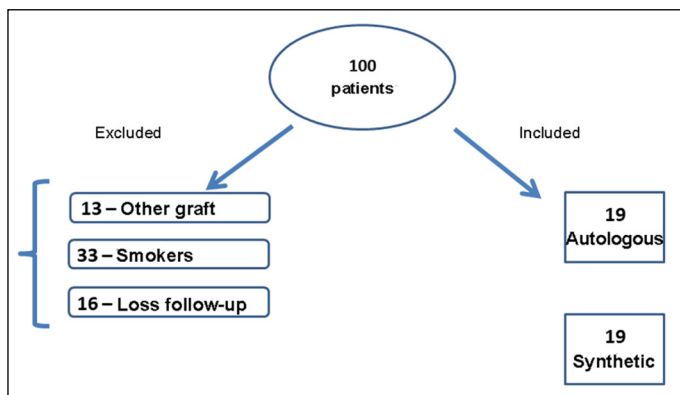


Figure 1. Drawing of the inclusion and exclusion criteria for the selected patients.

Table 1. Distribution of the sample according to preoperative characteristics by group.

Variable	Group 1	Group 2	p
ODI - mean ± SD	68.5% ± 4.6%	69.8% ± 4.0%	0.373
VAS - mean ± SD	7.8 ± 1.0	8.0 ± 1.1	0.527
Gender - n (%)			
Female	13 (68.4)	12 (63.1)	0.732
male	6 (31.6)	7 (36.8)	

SD: standard deviation; p: significance level; n: number of patients.

Table 2. ODI scale, pre-and post-operatively, for the two groups.

Patients	Preoperative mean ± SD	Post-surgery mean ± SD	p ¹	p ²
Group 1	68.5% ± 4.6%	27.2% ± 3.8%	<0.001	0.527
Group 2	69.8% ± 4.0%	19.3% ± 3.0%	<0.001	

SD: standard deviation; p: significance level; p¹: p-values for the difference between the preoperative and postoperative mean for each group; p²: p-values for the difference between the postoperative means of Group 1 versus Group 2.

Group 2 showed 19.3% in the postoperative evaluation, with a significant difference from the preoperative ($p < 0.001$). No statistical difference was observed when comparing the mean values found post-operatively between Group 1 and Group 2 ($p = 0.527$). In the preoperative evaluation, the VAS showed results between 7 and 10, while in the postoperative period, Group 1 varied between 0 and 2. The difference between the preoperative and postoperative evaluations was considered statistically significant ($p < 0.001$). Group 2 showed a variation between 6 and 10 in the preoperative period and between 0 and 2 in the postoperative period, with a statistically significant difference ($p < 0.001$). Comparing the groups, there was no statistical difference in the results of the postoperative VAS ($p = 0.463$).

Regarding the assessment of complications in the iliac region, two patients complained of chronic pain during the third and ninth postoperative months, representing a rate of approximately 10% of the total. No patients were found with fractures, deformities, hematomas, suture dehiscence, neurological lesions, or cases of infection at the site. The postoperative iliac VAS at the end of the third month ranged from 6 to 9, while at the end of the ninth month, it averaged four among patients in Group 1.

The radiographic evaluation in the third month did not find any changes, such as subsidence, loosening, or migration of the implants. In the ninth month, the radiographic evaluation included flexion-extension, in which no patient had an opening of 2mm or more between the spinous processes.

At the ninth-month CT scan, 16 patients (84.2%) in Group 1 and 15 patients (78.9%) in Group 2 showed bone healing (Figure 2), with no statistically significant difference between the groups ($p = 0.676$) (Table 3). No cases of subsidence were found in the patients.

DISCUSSION

Arthrodesis with anterior cervical decompression is one of the most widely used surgical treatments for patients with cervical

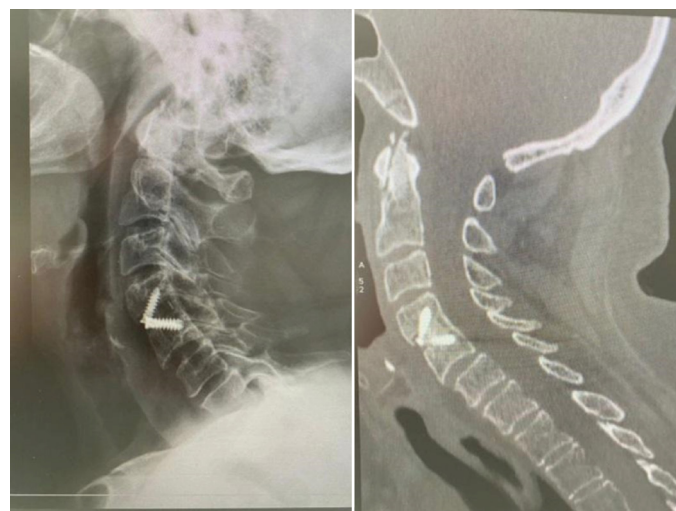

Figure 2. Left lateral radiograph at the ninth postoperative month and sagittal CT scan of the same patient in Group 2 showing bone healing.

Table 3. Postoperative consolidation for both groups.

Variable	Group 1 n (%)	Group 2 n (%)	p	
Immediate X-ray	consolidated	0 (0.0)	0 (0.0)	*
	not consolidated	19 (100.0)	19 (100.0)	
X-ray 3 months	consolidated	0 (0.0)	0 (0.0)	*
	not consolidated	19 (100.0)	19 (100.0)	
RX 9 months	consolidated	16 (84.2)	15 (78.9)	0.676
	not consolidated	3 (15.8)	4 (21.1)	
CT scan nine months	consolidated	16 (84.2)	15 (78.9)	0.676
	not consolidated	3 (15.8)	4 (21.1)	

* impossible to test; n: number of patients; p: level of significance.

spondylosis.¹⁶ The anterior approach improves lordosis and has high rates of intersomatic consolidation.¹⁷

Schroeder et al. showed a significant improvement in VAS in patients who underwent a primary procedure compared to the preoperative period, with a pre- and postoperative variation of 6 and 3, respectively.¹⁸ In their case series, Cerezci et al. described a variation in cervical VAS from 10 preoperatively to 1 postoperatively.¹⁹ In our study, we found a significant variation in the two groups, ranging from 8 preoperatively to 1 postoperatively from the third postoperative month onwards. Cerezci et al., also in their study, described ODI ranging from 86% to 20% in the pre- and post-operative periods, respectively, demonstrating statistical significance in the result.¹⁹ The present study also found statistically significant figures ranging from 80% in the pre-operative period to 18% in the third postoperative month.

The autologous iliac graft is considered the gold standard for anterior interbody fusion.²⁰ In his classic study, Wang found healing rates ranging from 78% to 90% in anterior cervical arthrodesis up to two levels.²¹ The present study showed similar results, with an 84% healing rate using this type of autologous graft.

According to the medical literature on synthetic grafts, hydroxyapatite and tricalcium phosphate are synthetic ceramics based on calcium phosphate.²² The positive characteristics of ceramics include their remarkable biocompatibility, biodegradation capacity, and function as an osteoinductive platform.²³ Yang et al. analyzed self-locking cages for one- to three-level cervical arthrodesis and showed a 73% healing rate when hydroxyapatite graft was used. However, they did not specify whether it was a paste or granules.²⁴ Lehr et al. compared arthrodesis levels using autologous grafts and the Attrax® graft in patients undergoing lumbar arthrodesis and obtained similar arthrodesis levels, demonstrating that the synthetic graft was not inferior to the autologous graft.²⁵ Publications on the use of the Attrax® graft in the cervical spine are rare, and this was a pioneering study evaluating the results between the gold standard

group and the group using Attrax®. Despite the difference in methodology, we also found non-inferiority in cervical arthrodesis, where we obtained a consolidation rate of approximately 80% in Group 2.

Sugawara et al.,²⁶ Coric et al.,²⁷ used lateral radiography combined with computed tomography to diagnose consolidation or pseudarthrosis. In a systematic review, Oshina et al.²⁸ found that the best evidence for diagnosing effective healing is the visualization of trabecular bone between the endplates of the vertebrae and the absence of radiolucency between the graft and the endplate. These criteria were used in this study during the radiographic assessment. It is common to find in the literature that computerized tomography (CT) is used to complement the assessment to reduce the subjectivity of the examiner's observation. As Ploumis²⁹ describes in his study, one of the tomographic criteria is that 50% of the space between the graft and the endplate must be filled to determine the healing success, thus providing the evaluator with a quantitative parameter. This study used axial and sagittal CT scans to measure the same evaluation criteria.

As Arrington et al. described in their paper, although the iliac crest is considered the gold standard for graft harvesting, the considerable and recurrent occurrence of donor site morbidity resulting from bone graft harvesting has significantly restricted its clinical use.³⁰ Banwarte et al. described, in their classic paper, an incidence of morbidity ranging from 10-30% of the patients studied. These complications included hematomas, surgical site infections, iliac crest fractures, or the formation of an incisional hernia.³¹ In the present study, no post-operative alterations such as those described above were found. In his study, Silber reported a variation in postoperative VAS at the donor site between 4 and 10 3 months after the procedure.³² In the present study, this score ranged from 6 to 9 at the end of the first trimester.

As described in the literature, complication rates such as chronic pain can vary from 13 to 20%.⁶ Benato et al.³³ published a study showing a 10% postoperative donor site pain rate after 180 days. Similarly, this study found that 10% of cases had chronic pain. As Thapa et al. describe, most chronic postoperative pain has neuropathic characteristics – allodynia, hyperalgesia, and paresthesia,³⁴ which is again consistent with this study in which patients complained of local allodynia and hyperalgesia.

One bias that needs to be considered is the length of time patients are followed up. Park et al., in their study, evaluated the healing rate of cervical arthrodesis using synthetic grafts with a 13-month follow-up.³⁵ Shriver et al., in their meta-analysis, indicate a mean follow-up time of 12 to 24 months for reliable results on healing rates.³⁶ The follow-up in the present study was nine months so that healing rates may increase over time. Another point to consider is that the current study did not measure operating room time during the procedure, which could have brought advantages to using synthetic grafts.

As Lehr²⁵ described, the quality of grafts has improved steadily since 1970, providing patients with better healing rates associated with a low potential for complications. Technological advances have also allowed us to see better results in inter-somatic consolidation, which is on par with the gold standard in the literature.

Associated with the reduction in complications related to the removal of the autologous graft, there is an increase in indications for the use of synthetic grafts in treating degenerative diseases of the cervical spine. However, it's important to note that this approach may entail additional surgical equipment costs. We project that, with the continuous advances in materials research and development, the ability to adjust the biological characteristics of synthetic grafts precisely will drive remarkable growth in the area of bone grafts.

Synthetic materials, such as ceramics, are effective in various spinal arthrodesis procedures, reducing dependence on autografts. Although many synthetic products have traditionally been used with autografts, recent research suggests that synthetic and biological compounds can facilitate proper bone healing without autografts or high growth factor administration.

This study's results suggest that the synthetic graft and gold standard groups had similar healing rates, with no statistically significant difference. While the group that used an autologous graft recorded a 10% rate of chronic pain after the ninth postoperative month, the synthetic graft proved to be as effective an option as the gold standard, with a lower incidence of morbidity. Despite the possible increase in surgical costs due to the price of the graft, the benefits include reduced surgical time and a lower incidence of complications, making it potentially cost-effective.

Further studies could assess the time taken to return to daily activities and the length of time off work, with the possibility of the overall results being equal to or even better than the gold standard.

CONCLUSION

This study revealed a significant improvement in patients' quality of life who underwent anterior cervical arthrodesis with both autologous and synthetic grafts. The group that received the synthetic graft showed bone healing rates close to 80% with no statistically significant differences compared to the group that received the autologous graft.

The synthetic tricalcium phosphate graft is a safe option. Its healing rates are equivalent to those observed with the autologous graft, making it a viable alternative for anterior cervical arthrodesis of up to two levels.

All authors declare no potential conflict of interest related to this article.

CONTRIBUTIONS OF THE AUTHORS: Each author contributed individually and significantly to the development of the manuscript. EJSJ: conception and design of the work, acquisition, analysis, and interpretation of the data and writing of the manuscript; ALK: interpretation of the results and critical revision of the manuscript's content; performed the surgeries PG Santoro: interpretation of the results and critical revision of the manuscript's content; MLB: interpretation of the results and critical revision of the manuscript's content; XSG: interpretation of the results and critical review of the content of the manuscript; performed the surgeries; ALS: conception and design of the work, interpretation of the results, critical review of the content of the manuscript and final approval of the version of the manuscript to be published; FNN: interpretation of the results and critical review of the content of the manuscript.

REFERENCES

1. Gruskay JA, Basques BA, Bohl DD, Webb ML, Grauer JN. Short-term adverse events, length of stay, and readmission after iliac crest bone graft for spinal fusion. *Spine (Phila Pa 1976)*. 2014;39(20):1718-24.
2. Liu CY, Zygourakis CC, Yoon S, Kliot T, Moriates C, Ratliff J, et al. Trends in Utilization and Cost of Cervical Spine Surgery Using the National Inpatient Sample Database, 2001 to 2013. *Spine (Phila Pa 1976)*. 2017;42(15):E906-13.
3. Kim K, Izu T, Sugawara A, Matsumoto R, Isobe M. Utility of new bioabsorbable screws in cervical anterior fusion. *Surg Neurol*. 2007;68(3):264-8.
4. Myeroff C, Archdeacon M. Autogenous bone graft: donor sites and techniques. *J Bone Joint Surg Am*. 2011;93(23):2227-36. doi:10.2106/JBJS.J.01513.
5. Hung CW, Wu MF, Yu GF, Ko CC, Kao CH. Comparison of sagittal parameters for anterior cervical discectomy and fusion, hybrid surgery, and total disc replacement for three levels of cervical spondylosis. *Clin Neurol Neurosurg*. 2018;168:140-6. doi:10.1016/j.clin-neuro.2018.03.003.
6. Dimitriou R, Mataliotakis GI, Angoules AG, Kanakaris NK, Giannoudis PV. Complications following autologous bone graft harvesting from the iliac crest and using the RIA: a systematic review. *Injury*. 2011;42(Suppl 2):S3-15. doi:10.1016/j.injury.2011.06.015
7. Ahlmann E, Patzakis M, Roidis N, Shepherd L, Holtom P. Comparison of anterior and posterior iliac crest bone grafts in terms of harvest-site morbidity and functional outcomes. *J Bone Joint Surg Am*. 2002;84(5):716-20. doi:10.2106/00004623-200205000-00003.
8. Goulet JA, Senunas LE, De Silva GL, Greenfield ML. Autogenous iliac crest bone graft. Complications and functional assessment. *Clin Orthop Relat Res*. 1997;(339):76-81. doi:10.1097/00003086-199706000-00011
9. Younger EM, Chapman MW. Morbidity at bone graft donor sites. *J Orthop Trauma*.

- 1989;3(3):192-5. doi:10.1097/00005131-198909000-00002.
10. Kwon B, Jenis LG. Carrier materials for spinal fusion. *Spine J*. 2005;5(6 Suppl):224S-30S. doi:10.1016/j.spinee.2005.02.007.
 11. Bauer TW, Muschler GF. Bone graft materials. An overview of the basic science. *Clin Orthop Relat Res*. 2000;(371):10-27.
 12. Erbe EM, Marx JG, Clineff TD, Bellincampi LD. Potential of an ultraporous beta-tricalcium phosphate synthetic cancellous bone void filler and bone marrow aspirate composite graft. *Eur Spine J*. 2001;10(Suppl 2):S141-6. doi:10.1007/s005860100287.
 13. Buser Z, Brodke DS, Youssef JA, Meisel HJ, Myhre SL, Hashimoto R, et al. Synthetic bone graft versus autograft or allograft for spinal fusion: a systematic review. *J Neurosurg Spine*. 2016;25(4):509-16. doi:10.3171/2016.1.SPINE151005.
 14. Jensen MP, Karoly P, Braver S. The measurement of clinical pain intensity: a comparison of six methods. *Pain*. 1986;27(1):117-26.
 15. Vigatto R, Alexandre NM, Correa Filho HR. Development of a Brazilian Portuguese version of the Oswestry Disability Index: cross-cultural adaptation, reliability, and validity. *Spine (Phila Pa 1976)*. 2007;32(4):481-6.
 16. Fountas KN, Kapsalaki EZ, Nikolakakos LG, Smisson HF, Johnston KW, Grigorian AA, et al. Anterior cervical discectomy and fusion associated complications. *Spine (Phila Pa 1976)*. 2007;32(21):2310-7. doi:10.1097/BRS.0b013e318154c57e.
 17. Liu Y, Hou Y, Yang L, Chen H, Wang X, Wu X, et al. Comparison of 3 reconstructive techniques in the surgical management of multilevel cervical spondylotic myelopathy. *Spine (Phila Pa 1976)*. 2012;37(23):E1450-8. doi:10.1097/BRS.0b013e31826c72b4.
 18. Schroeder GD, Boody BS, Kepler CK, Kurd MF, Silva S, Nicholson K, et al. Comparing Health-Related Quality of Life Outcomes in Patients Undergoing Either Primary or Revision Anterior Cervical Discectomy and Fusion. *Spine (Phila Pa 1976)*. 2018;43(13):E752-7. doi:10.1097/BRS.0000000000002511.
 19. Cerezci O, Basak AT. The Effects of Rehabilitation Following Anterior Cervical Microdiscectomy and Fusion Surgery. *Turk Neurosurg*. 2022;32(5):834-40. doi:10.5137/1019-5149.JTN.36243-21.2.
 20. Kim K, Isu T, Sugawara A, Morimoto D, Matsumoto R, Isobe M, et al. Radiological study of the sandwich method in cervical anterior fusion using autologous vertebral bone grafts. *J Clin Neurosci*. 2010;17(4):450-4. doi:10.1016/j.jocn.2009.07.118.
 21. Wang JC, McDonough PW, Endow KK, Delamarter RB. Increased fusion rates with cervical plating for two-level anterior cervical discectomy and fusion. *Spine (Phila Pa 1976)*. 2000;25(1):41-5. doi:10.1097/00007632-200001010-00009.
 22. LeGeros RZ. Calcium phosphate-based osteoinductive materials. *Chem Rev*. 2008;108(11):4742-53. doi:10.1021/cr800427g.
 23. Moore WR, Graves SE, Bain GI. Synthetic bone graft substitutes. *ANZ J Surg*. 2001;71(6):354-61.
 24. Yang C, Zhuo W, Li Q, Huang C, Yan H, Jin D. Preliminary outcomes of allograft and hydroxyapatite as substitutes for autograft in anterior cervical discectomy and fusion with self-locking standalone cages. *J Orthop Surg Res*. 2021;16(1):123. doi:10.1186/s13018-021-02257-0.
 25. Lehr AM, Oner FC, Delawi D, Stellato RK, Hoebink EA, Kempen DHR, et al. Efficacy of a Standalone Microporous Ceramic Versus Autograft in Instrumented Posterolateral Spinal Fusion: A Multicenter, Randomized, Inpatient Controlled, Noninferiority Trial. *Spine (Phila Pa 1976)*. 2020;45(14):944-51. doi:10.1097/BRS.0000000000003440.
 26. Sugawara T, Itoh Y, Hirano Y, Higashiyama N, Mizoi K. β -Tricalcium phosphate promotes bony fusion after anterior cervical discectomy and fusion using titanium cages. *Spine (Phila Pa 1976)*. 2011;36(23):E1509-14. doi:10.1097/BRS.0b013e31820e60d9.
 27. Coric D, Nunley PD, Guyer RD, Musante D, Carmody CN, Gordon CR, et al. Prospective, randomized, multicenter study of cervical arthroplasty: 269 patients from the Kineflex® artificial disc investigational device exemption study with a minimum 2-year follow-up: clinical article. *J Neurosurg Spine*. 2011;15(4):348-58. doi:10.3171/2011.5.SPINE10769. Erratum in: *J Neurosurg Spine*. 2012;16(3):322.
 28. Oshina M, Oshima Y, Tanaka S, Riew KD. Radiological Fusion Criteria of Postoperative Anterior Cervical Discectomy and Fusion: A Systematic Review. *Global Spine J*. 2018;8(7):739-50. doi:10.1177/2192568218755141.
 29. Ploumis A, Mehbood A, Garvey T, Gilbert T, Transfeldt E, Wood K. Prospective assessment cervical fusion status: plain radiographs versus CT-scan. *Acta Orthop Belg*. 2006;72(3):342-6.
 30. Arrington ED, Smith WJ, Chambers HG, Bucknell AL, Davino NA. Complications of iliac crest bone graft harvesting. *Clin Orthop Relat Res*. 1996;329:300-9.
 31. Banwart JC, Asher MA, Hassanein RS. Iliac crest bone graft harvest donor site morbidity. A statistical evaluation. *Spine (Phila Pa 1976)*. 1995;20(9):1055-60. doi:10.1097/00007632-199505000-00012.
 32. Silber JS, Anderson DG, Daffner SD, Brislin BT, Leland JM, Hilibrand AS, et al. Donor site morbidity after anterior iliac crest bone harvest for single-level anterior cervical discectomy and fusion. *Spine (Phila Pa 1976)*. 2003;28(2):134-9. doi:10.1097/00007632-200301150-00008.
 33. Benato ML, Zaninelli EM, Graells XSi, Sonagli UMA. Artrodese cervical anterior em três e quatro níveis com dispositivo intersomático não associado à placa cervical. *Coluna/Columna*. 2009;8(2):143-7. doi:10.1590/S1808-1851200900020000.
 34. Thapa P, Euasobhon P. Chronic postsurgical pain: current evidence for prevention and management. *Korean J Pain*. 2018;31(3):155-73. doi:10.3344/kjp.2018.31.3.155.
 35. Park JS, Park SJ, Lee CS, Chung SS, Park HJ. Is allograft a more reliable treatment option than autograft in 2-level anterior cervical discectomy and fusion with plate fixation? *Medicine (Baltimore)*. 2019;98(32):e16621. doi:10.1097/MD.00000000000016621.
 36. Shriver MF, Lewis DJ, Kshetry VR, Rosenbaum BP, Benzel EC, Mroz TE. Pseudoarthrosis rates in anterior cervical discectomy and fusion: a meta-analysis. *Spine J*. 2015;15(9):2016-27. doi:10.1016/j.spinee.2015.05.010.