

Lissencephaly and cerebellar hypoplasia in a goat

Lisencefalia e hipoplasia cerebelar em caprino

José Rômulo Soares dos Santos¹ Antônio Flavio Medeiros Dantas¹
Clarice Ricardo Macedo Pessoa¹ Tatiane Rodrigues Silva¹ Sara Vilar Dantas Simões¹
Franklin Riet-Correa^{1*} Daniel Pedrosa¹

- NOTE -

ABSTRACT

A case of lissencephaly and cerebellar hypoplasia was observed in a 30-day-old goat. The goat presented with sternal recumbence, absence of a menace response, intention tremors, ataxia, and nystagmus. The goat was euthanized and necropsied after having been hospitalised for eleven days. At necropsy, the surface of the brain was found to be smooth, the cerebral sulci and gyri were absent, and the cerebellum was reduced in size. Histologically, the grey matter and white matter were thicker and thinner than normal in cortices, respectively. The neurons were randomly arranged in the grey matter. In the cerebellum, the layers were disorganised, and cells were heterotopics. The histologic and gross lesions observed in this animal are characteristic of lissencephaly associated with cerebellar hypoplasia. The presence of a single goat affected suggests that the malformation was not of infectious origin and because lissencephaly is a malformation not previously described in goats, it is unlikely this case was inherited.

Key words: agyria, cerebellar hypoplasia, goat, malformations.

RESUMO

Um caso de lisencefalia e hipoplasia cerebelar é descrito em um caprino com 30 dias de idade. No exame físico, apresentava decúbito esternal permanente, ataxia, ausência do reflexo de ameaça, tremores de intenção e nistagmo. Após 11 dias de internamento, o caprino foi eutanasiado e necropsiado. Na necropsia, o cérebro não apresentava giros nem sulcos e o cerebelo estava reduzido de tamanho. Histologicamente, em todo o córtex cerebral, a substância cinzenta estava mais espessa e a substância branca mais fina que o normal. Os neurônios estavam distribuídos de forma aleatória na substância cinzenta. No cerebelo, as camadas estavam desorganizadas, com localização heterotópica das células. Os achados macroscópicos e histológicos são característicos de lisencefalia e hipoplasia cerebelar. A presença de um só animal afetado sugere que a malformação não é de origem infecciosa e o fato da lisencefalia nunca ter sido descrita antes em caprinos sugere que não é uma doença hereditária.

Palavras-chave: agyria, hipoplasia cerebelar, caprinos, malformações.

Lissencephaly is a developmental defect characterised by a smooth cerebral surface lacking gyri and sulci (agyria) and a thickened cortex (pachygyria) due to the abnormal distribution of neuronal cell bodies (De LAHUNTA & GLASS, 2009). This brain malformation is caused by disordered neuroblast migration during embryonic development; neurons are not able to migrate from their origin in the ventricular and subventricular zones to their destined location in the cerebral cortex (AYALA et al., 2007). Lissencephaly is a malformation that occurs relatively often in humans, and mutations in the LIS1, doublecortin (DCX), filamin-1, tubulin A1A (TUBA1A), and reelin (RELN) genes have been linked to the occurrence of this condition. These genes are involved in the migration of neurons that control the spatial location and temporal organisation of interneuronal connections in the cerebral cortex (GUERRINI & PARRINI, 2010). Lissencephaly is a rare disease in veterinary medicine; it has been reported in Lhasa Apso dogs, a breed predisposed to this condition, and in cats (ZAKI, 1976; SAITO et al., 2002; HERMANN et al., 2011). Other brain malformations may occur simultaneously with lissencephaly. In Irish Setters and Wire Fox Terriers dogs, lissencephaly has been reported to occur with cerebellar hypoplasia (GREENE et al., 1976); in cats, this condition has been reported to be accompanied by microencephaly and hypoplasia of the corpus

¹Hospital Veterinário, Centro de Saúde e Tecnologia Rural, Universidade Federal de Campina Grande (UFCG), 58700-000, Patos, PB, Brasil. E-mail: franklin.riet@pq.cnpq.br. *Autor para correspondência.

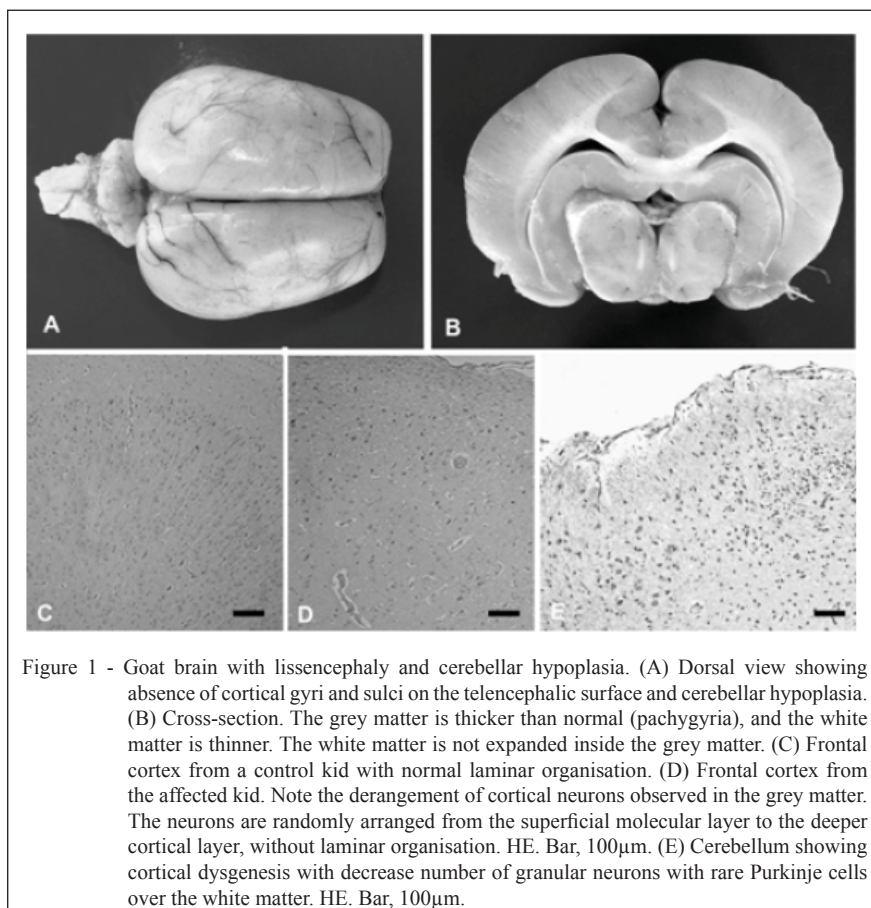
callosum and cerebellum (HERRMANN et al., 2011). Studies reporting congenital nervous system defects in goats are rare (WASHBURN & STREETER, 2004). In this case report, the pathological and clinical findings of lissencephaly accompanied by cerebellar hypoplasia are reported in a kid goat.

A 30-day-old crossbred male goat weighing 8kg was admitted for clinical examination in May 2011 to the Veterinary Hospital of Campina Grande Federal University in the Patos district of Paraíba state in the semiarid region of North-eastern Brazil. According to the owner, the kid had been recumbent since birth. The animal was from a herd of 80 goats and sheep of different ages bred extensively on native pastures; these pastures contained *Aspidosperma pyriformis* and *Mimosa tenuiflora*, which can cause abortions (MEDEIROS et al., 2004) and malformations (PIMENTEL et al., 2007) in sheep and goats. No animals had been recently introduced on the farm. Physical examination revealed a lack of motor coordination, an inability to stand, permanent sternal recumbence, ataxia, absence of a menace response, intention tremors, and nystagmus.

After being hospitalised for 11 days, the goat was euthanised due to unfavourable prognosis and the inability to be handled. At necropsy, the absence of cortical gyri and sulci in the telencephalic surface was noted (Figure 1A). The cerebellum showed marked hypoplasia, and the vermis and cerebellar hemispheres were vestigial (Figure 1A). The cerebellar folia were rudimentary and reduced in number.

In serial transverse brain sections, the grey matter was thickened (pachygyria) in the cortex of the frontal, temporal, parietal and occipital lobes, and the white matter was thinner than normal (Figure 1B). The white matter was not expanded inside the grey matter. The nodulus was absent in the cerebellar vermis and the fourth ventricle was enlarged.

The central nervous system and the other organs were fixed in 10% formalin. After fixation, the fragments were embedded in paraffin and cut into 5- μ m-thick sections. The sections were stained with hematoxylin-eosin and cresyl violet with luxol fast blue and subjected to routine neuropathological examination. The grey and white matter were found



to be thicker and thinner than normal, respectively. A derangement of cortical neurons was seen in the grey matter. The neurons were randomly arranged without laminar organisation from the superficial molecular layer to the deeper cortical layer (Figure 1D). In the molecular layer, the neurons were irregularly dispersed; some sections had neuronal hypercellularity, while others displayed hypocellularity. The neocortex contained nests of heterotopic granular neurons and scattered heterotopic white matter bundles. Microscopic examination of the cerebellum revealed the presence of cortical dysgenesis. Folia were reduced in size and number and displayed evidence of abnormal development. The cerebellar heterotopia consisted of disorganised Purkinje and granular cells. Purkinje cells were irregularly dispersed within the granular and molecular layers. The molecular layer was reduced in size. The cerebellar white matter contained randomly arranged heterotopic neurons, suggesting arrested migration. Occasionally, granular neurons nests with rare Purkinje cells were observed within the white matter (Figure 1E). Hypomyelination was not observed by the cresyl violet with luxol fast blue stain.

The diagnosis of lissencephaly was made based on macroscopic and histologic features. To the best of our knowledge, this is the first report of lissencephaly in goats. Agyria and thickening of the grey matter of the telencephalon arise from disturbance of neuronal migration, resulting in structural disorganisation of the neurons that normally form the six cell layers of the brain cortex (AYALA et al., 2007). Lissencephaly is characteristically observed in the normal brains of rodents, rabbits, birds and bats and has no known functional significance (GREENE et al., 1976). In other species, this congenital anomaly is considered rare and is associated with functional disturbances. Proper brain function depends on the correct positioning of neurons. Changes in the position of cells results in failure of the establishment of neural connections and therefore of normal neuronal interactions, resulting in abnormal functions and clinical signs (AYALA et al., 2007). The lissencephalic brain cortex is responsible for nonspecific clinical signs. In this case, the clinical signs observed were characteristic of cerebellar lesions (WASHBURN & STREETER, 2004). Cortical signs described in dogs, cats and humans with lissencephaly such as blindness, depression, and seizures were not observed in this case. Because motor functions are coordinated by the cerebellum, it is likely that the high degree of cerebellar dysfunction may have masked any clinical signs associated with cortical dysfunction.

In the case reported herein, the cerebellar and brain lesions were similar, suggesting a neuronal migration disorder as the cause of both lesions, as proposed by DE LAHUNTA & GLASS (2009). The presence of a single goat with this malformation suggests that the malformation was not of infectious origin. In addition, because only a single case was observed, and because lissencephaly is a malformation not previously described in goats, it is unlikely that this disease was inherited. However, the lesions observed in this case are similar to those caused by genetic mutations in other species. In humans, the genes associated with lissencephaly are LIS1 and DCX; other genes that may be responsible for malformations associated with lissencephaly are not known (ROSS et al., 2001; KEAYS et al., 2007). The combination of microencephaly, cerebellar hypoplasia and hypoplasia of the corpus callosum in humans has been linked to autosomal recessive mutations in genes such as TUBA1A and RELN (ROSS et al., 2001). The developmental process of the cerebral cortex is unique to mammals (AYALA et al., 2007), suggesting that the mechanism of malformation is the same in different species. However, it is possible that the same malformation may be due to different causes (RADOSTITS et al., 2007). In this case, it is likely that a spontaneous genetic mutation or developmental error was responsible for this malformation. In humans, intrauterine hypoxia or perfusion failure have been proposed as causes of lissencephaly (DE LAHUNTA & GLASS, 2009). Anoxic insult during neuronal migration results in disorganisation and hypocellularity of the layers of the telencephalon, causing lissencephaly and microcephaly (ROESSMAN & HORI, 1985). The presence of the teratogenic plant *M. tenuiflora* on the farm also suggests that this case of lissencephaly might have been caused by the ingestion.

Although diseases associated with neuronal migration disorders such as lissencephaly are rare in domestic animals, they should nevertheless be included in the differential diagnosis of diseases of the nervous system in goats. If new cases should arise, a possible genetic origin of the malformation should be investigated.

ETHICAL STATEMENT

We declare to whom correspond that we assume any responsibility about any process realized during the development of the research entitled Lissencephaly and cerebellar hypoplasia in a goat. Likewise we are available to answer any questions that may be needed.

REFERENCES

- AYALA, R. et al. Trekking across the Brain: The journey of neuronal migration. **Cell**, v.128, n.12, p.29-40, 2007. Available from: <<http://dx.doi.org/10.1016/j.cell.2006.12.021>>. Accessed: Nov. 12, 2012. doi: 10.1016/j.cell.2006.12.021.
- DE LAHUNTA, A.; GLASS, E. Development of nervous system: malformation. In: _____. **Veterinary neuroanatomy and clinical neurology**. 3.ed. Saint Louis, Missouri: Saunders Elsevier, 2009. Cap.3, p.23-53.
- GREENE, C.E. et al. Lissencephaly in two Lhasa Apso dogs. **Journal of the American Veterinary Medicine Association**, v.169, n.4, p.405-410, 1976.
- GUERRINI, R.; PARRINI, E. Neuronal migration disorders. **Neurology of Disease**, v.38, p.154-166, 2010. Available from: <<http://www.ncbi.nlm.nih.gov/pubmed/19245832>>. Accessed: Nov. 12, 2012. doi: 10.1016/j.nbd.2009.02.008.
- HERRMANN, A. et al. Lissencephaly and microencephaly combined with hypoplasia of corpus callosum and cerebellum in a domestic cat. **Tierärztliche Praxis Kleintiere**, v.2, p.116-120, 2011.
- KEAYS, D.A. et al. Mutations in α -tubulin cause abnormal neuronal migration in mice and lissencephaly in humans. **Cell**, v.128, p.45-57, 2007. Available from: <<http://download.cell.com/pdf/PIIS0092867406016114.pdf?intermediate=true>>. Accessed: Oct. 10, 2012. doi: 10.1016/j.cell.2006.12.017.
- MEDEIROS, J.M. et al. Mortalidade perinatal em caprinos no semi-árido da Paraíba. **Pesquisa Veterinária Brasileira**, v.25, n.4, p.201-206, 2005. Available from: <<http://dx.doi.org/10.1590/S0100-736X2005000300008>>. Accessed: Dez. 12, 2012. doi: 10.1590/S0100-736X2005000300008.
- PIMENTEL, L.A. et al. *Mimosa tenuiflora* as a cause of malformation in ruminants in the northeastern Brazilian semiarid rangelands. **Veterinary Pathology**, v.44, p.928-931, 2007. Available from: <<http://vet.sagepub.com/content/44/6/928.full.pdf+html>>. Accessed: May. 03, 2012. doi: 10.1354/vp.44-6-928.
- RADOSTITS, O.M. et al. Diseases of the newborn. In: _____. **Veterinary medicine - A textbook of the diseases of cattle, horses, sheep, pigs and goats**. 10.ed. Philadelphia: Saunders Elsevier, 2007. Cap.3, p.127-172.
- ROESSMAN, U.; HORI, A. Agyria (Lissencephaly) with anomalous pyramidal crossing: case report and review of literature. **Journal of the Neurological Science**, v.69, p.357-364, 1985.
- ROSS, M.E. et al. Lyssencephaly with cerebellar hypoplasia (LCH): a heterogenous group of cortical malformations. **Neuropediatrics**, v.32, p.256-263, 2001.
- SAITO, M. et al. Magnetic resonance imaging features of lissencephaly in 2 Lhasa Apso dogs. **Veterinary Radiology & Ultrasound**, v.43, n.4, p.331-337, 2002. Available from: <<http://onlinelibrary.wiley.com/doi/10.1111/j.1740-8261.2002.tb01013.x/abstract>> Accessed: May. 05, 2012. doi: 10.1111/j.1740-8261.2002.tb01013.x.
- WASHBURN, K.E.; STREETER, R.N. Congenital defects of the ruminant nervous system. **Veterinary Clinical Food Animal**, v.20, p.413-434, 2004.
- ZAKI, F.A. Lissencephaly in Lhasa Apso dogs. **Journal of the American Veterinary Medicine Association**, v.169, n.11, p.1165-1168, 1976.