











## Valvular endocarditis associated with *Helcococcus ovis* in a cow in Southern Brazil

Regina Tose Kemper<sup>1</sup>  Bruna Correa Lopes<sup>1</sup>  Rafael Biondo Rosa<sup>1</sup>   
 Francieli Adriane Molossi<sup>1</sup>  Bianca Santana de Cecco<sup>1</sup>  Fabiana Quos Mayer<sup>2</sup>   
 Rosane Maria Sordi Driemeier<sup>1</sup>  Luciana Sonne<sup>1\*</sup> 

<sup>1</sup>Setor de Patologia Veterinária, Universidade Federal do Rio Grande do Sul (UFRGS) 9154-000, Porto Alegre, RS, Brasil. E-mail: lusonne@yahoo.com.br.

\*Corresponding author.

<sup>2</sup>Centro de Pesquisa em Saúde Animal, Instituto de Pesquisas Veterinárias Desidério Finamor, Eldorado do Sul, RS, Brasil.

**ABSTRACT:** A 4-year-old cow with a history of breathing difficulty, progressive weight loss, and muffled heart sound was treated for a period of two weeks, but died and underwent necropsy examination. Macroscopic examination revealed heart with vegetative proliferative lesion firmly adhered to pulmonary valve, lungs with marked consolidation, and the presence of thrombus in vessels. There were grade II ulcers in abomasal mucosa associated to blood clots. Microscopic examination revealed marked thickening of the pulmonary valve due to the proliferation of fibrous connective tissue, inflammatory neutrophil infiltration, fibrin deposition, and a significant number of coccoid basophilic bacteria. Septic thromboemboli were present in the large and small pulmonary blood vessels suggestive of embolic pneumonia. The bacterial culture of the valve showed growth of small, nonhemolytic colonies that demonstrated satellitism to coagulase-negative staphylococci contaminating colonies, which were subjected to 16S gene sequencing and were compatible with *Helcococcus ovis* in GenBank. This was the first report of *H. ovis* endocarditis in cattle in South America.

**Key words:** heart, bacteria, PCR, cattle, valve.

### Endocardite vegetativa associada à *Helcococcus ovis* em uma vaca no Sul do Brasil

**RESUMO:** Um bovino, fêmea, 4 anos com histórico de dificuldade respiratória, perda de peso progressiva e som cardíaco abafado, foi tratado por um período de duas semanas, porém veio a óbito e foi submetido a exame de necropsia. No exame macroscópico, notou-se coração com lesão proliferativa vegetativa firmemente aderida em valva pulmonar, pulmões com consolidação acentuada, e presença de trombos no interior de vasos. Havia ainda úlcera abomasal grau II em mucosa associada a coágulo sanguíneo. No exame microscópico notou-se acentuado espessamento da valva pulmonar por proliferação de tecido conjuntivo fibroso, infiltrado inflamatório de neutrófilos, deposição de fibrina e acentuado número de miríades bacterianas basofílicas coccoides. Tromboembolia séptica foi vista no interior de vasos pulmonares de pequeno e médio calibre, sugestivo de pneumonia embólica. Em cultivo bacteriano da valva notou-se crescimento de colônias pequenas, não hemolíticas que demonstravam satelitismo a colônias contaminantes de estafilococos coagulase negativa, essas foram submetidas ao sequenciamento do gene 16S e foram compatíveis com *Helcococcus ovis* no GenBank. Este foi o primeiro relato de endocardite por *H. ovis* em bovino na América do Sul.

**Palavras-chave:** coração, bactéria, PCR, bovinos, válvula.

Endocarditis is an inflammation of the endocardium, which is mainly caused by bacterial infection of the valves. Valvular endocarditis can arise from primary bacterial infection of the valves and/or be a result of extension from mural endocarditis (MILLER & GAL, 2017). The valve affected can differ among species. In cattle, the right atrioventricular valve is the most commonly affected (BEXIGA et al., 2008); while in small animals (dogs and cats), the aortic and mitral valves are far more commonly involved (MACDONALD et al., 2010).

A wide range of bacterial species has been reported as the causative agent of valvular

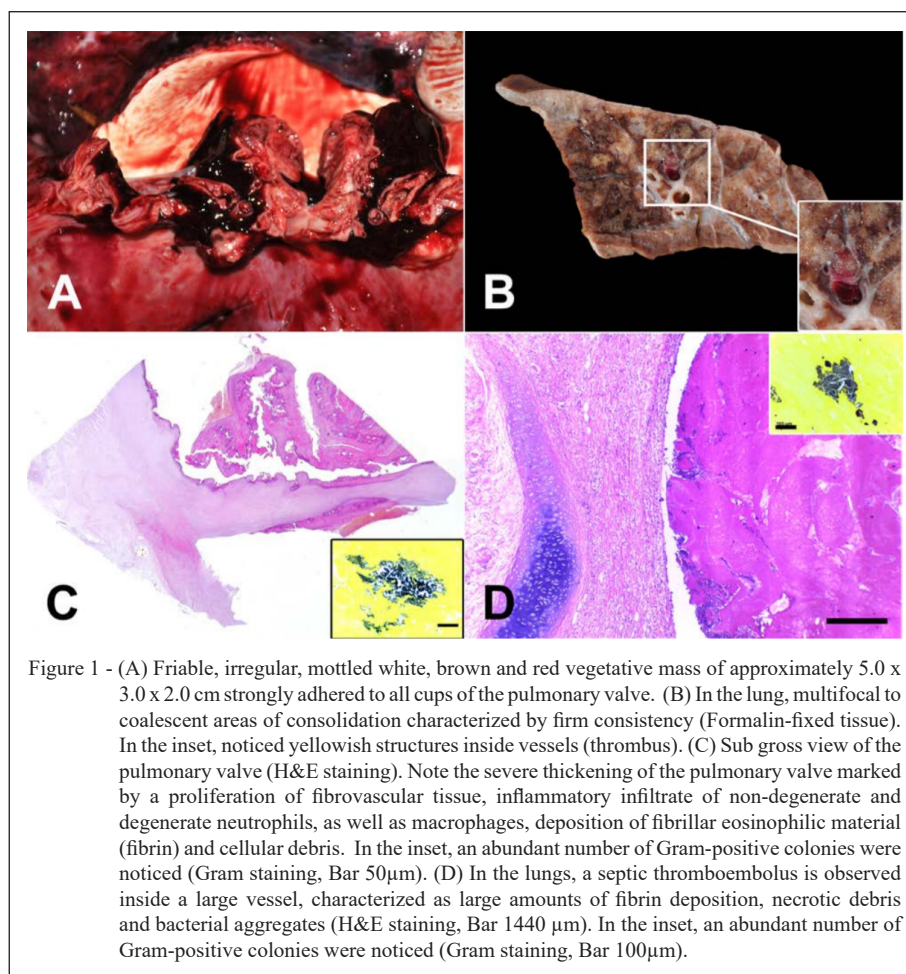
endocarditis in cattle; however, *Trueperella pyogenes* and *Streptococcus* spp. are recognized as the main etiological agents (BEXIGA et al., 2008). Recent research on the causative agents of endocarditis in cattle in Germany has pointed out *Helcococcus ovis* as an emerging pathogen (KUTZER et al., 2008). *H. ovis* is a Gram-positive, catalase-negative coccus first described in 1999 from isolates of sheep, in the United Kingdom (UK) (COLLINS et al., 1999). Since then, different studies have described this bacterium in different animal species and causing diverse clinical presentations, such as mastitis in sheep (COLLINS et al., 1999), endocarditis and abortion

in cattle (POST et al., 2003), and pulmonary abscessation in horse (ROTHSCHILD et al., 2004). The objective of this study was to describe a case of valvular endocarditis caused by *H. ovis* in a cow.

A 5-year-old Holstein cow was submitted to necropsy examination with a history of progressive weight loss and pneumonia before calving. The cow was treated with tetracycline, dipyrone and flunixin meglumine for approximately two weeks; however, the doses were not recorded by the farmer. After calving, the progressed weight loss and muffled heart sounds were noticed 3 days before the animal died. During the macroscopic examination, severe pale mucous membranes were noticed. In the pericardium, epicardium and extending to the pulmonary artery, extensive areas of hemorrhage were observed. Examination of the heart cavities demonstrated a friable, irregular, mottled white, brown and red

vegetative mass of approximately 5.0 x 3.0 x 2.0 cm strongly adhered to all cusps of the pulmonary valve (Figure 1A). In the lungs, multifocal to coalescent areas of consolidation in all pulmonary lobes was characterized by firm consistency, reddish color and associated with interlobular edema, and yellowish, firm structures inside vessels were seen (thrombus) (Figure 1B). The abomasum was markedly distended and filled with free blood clots, associated with severe multifocal mucosal ulceration (ulcer grade II), as defined by HUND & WITTEK (2017), when a large blood vessel was eroded and a considerable amount of blood loss happens. Hemorrhagic content was seen throughout the intestinal tract.

Tissue samples from lungs, heart, kidney, liver, nervous system and alimentary tract were collected and fixed in 10% buffered formalin, processed routinely, cut in 3µm section and stained



with hematoxylin and eosin, and also Gram stain (heart and lung tissues). Microscopic examination revealed severe thickening of the pulmonary valve marked by a proliferation of fibrovascular tissue, inflammatory infiltrate of non-degenerate and degenerate neutrophils, as well as macrophages, deposition of fibrillar eosinophilic material (fibrin), cellular debris, and an abundant number of Gram positive coccoid bacterial colonies (Figure 1C).

In the lungs, multifocal severe thrombosis characterized by a large amounts of fibrin deposition inside large and small arterioles, associated with Gram positive bacterial colonies (Figure 1D) similar to those seen in the pulmonary valve were noticed. Adjacent to these areas a severe inflammatory infiltrate of neutrophils, areas of coagulative necrosis, edema, and fibrosis, as well as hemorrhage and a moderate number of macrophages filled with hemosiderin pigment were observed in the alveolar space. Interlobular septa were thickened by fibrous connective tissue and inflammatory infiltrate of non-degenerate and degenerate neutrophils, as well as fibrin deposition. There was also moderate thickening of the visceral pleura, characterized by the proliferation of connective tissue. In the abomasum, severe multifocal areas of mucosal discontinuity correlated with fibrin deposition, cellular debris, and inflammatory infiltrate of neutrophils, macrophages, hemorrhage, and coccoid bacterial aggregates in the mucosa adjacent were noticed.

Refrigerated samples of the lungs and valve were cultivated on Blood Agar (5% sheep blood; Mueller Hinton, Kasvi®, Brazil) and Macconkey Agar plates (Kasvi®, Brazil) followed by aerobic incubation at 37 °C for 72 hours. After that, a moderate number of nonhemolytic small greyish colonies (about 1 mm) were visualized on the plates from the valve samples; however, not on the lungs, showing satellitism with other contaminant colonies of coagulase-negative staphylococci (CoNS), were morphologically compatible with bacteria of the genus *Streptococcus*. From these colonies, slides stained with Gram stain were prepared and Gram-positive cocci arranged in pairs and clusters were identified.

The isolated colonies were then submitted to the 16S rRNA gene sequencing. The DNA was extracted by phenol-chloroform protocol (GREEN & SAMBROOK, 2012). The 16S rRNA partial gene sequence was amplified by polymerase chain reaction (PCR) to determine its identity, using the primers forward (5'GTGCCAGCMGCCGCGGTAA3') and reverse (5'TAATCTWTGGGVHCCATCAGG3') and was subjected to nucleotide sequencing. The PCR

reaction was performed according to KOZICH et al. (2013). The obtained sequence was searched at GenBank database, and the highest match was obtained with the 16S rRNA gene sequence of "*Helcococcus ovis* 1527\_Yamagata\_170207" (GenBank accession no. LC367063.1) with identity and query cover of 100%, and E-value of 5e-149.

The macroscopic, microscopic, bacteriologic and molecular findings were compatible with valvular endocarditis caused by the bacterium *H. ovis*. BUCZINSKI et al. (2012) reported in their study that tachycardia and auscultation of heart murmur, along with the presence of fever were the diagnostic criteria with the highest specificity when analyzing 460 cases of bacterial endocarditis in cattle. In the present case, muffled heart sounds and progressive weight loss were noticed. No diagnostic methods, other than clinical examination were available and at the time our team arrived at the farm the animal died. Although, KUTZER et al. (2008) point out that *H. ovis* may be an emerging pathogen in cases of valvular endocarditis, this condition in cattle is usually caused by *Streptococcus* sp. and *Trueperella pyogenes* (BUCZINSKI et al., 2012). The present case stands out because the species *H. ovis* is hardly registered as causing disease and there are few reports in the literature about this bacterium causing clinical cases.

The valve involved in this case was the pulmonary, which is uncommon. The right atrioventricular valve is most commonly affected as reported by BUCZINSKI et al. (2012) in a meta-analysis study, in which only 13.7% of the cases presented involvement of the pulmonary valve. KUTZER et al. (2008) during their study in an abattoir also reported the right atrioventricular valve as the most common site of infection followed by bicuspid valve. However, there are contradictory studies, affirming that the right atrioventricular valve is more commonly involved in ruminants (MEURS, 2009; ROBINSON & ROBINSON, 2016). From 55 cases of endocarditis in cattle studied by KUTZER et al. (2008) only one case presented vegetative proliferation in more than one valve (tricuspid and pulmonary). While BUCZINSKI et al. (2012) in a meta-analysis of 460 confirmed cases of endocarditis did not bring up that information and only separated which valve was most commonly affected. POST et al. (2003) reported a case of valvular endocarditis by *H. ovis* in the right atrioventricular valve of a bull in the state of North Carolina (USA), and the microscopic findings, such as severe inflammatory infiltrate and areas of necrosis, were similar to those in our study.

Similar patterns of chronic endocarditis caused by *H. ovis* was noticed by KUTZER et al. (2008), in which consist of valvular thrombi characterized by a luminal zone and having unorganized fibrinous exudate.

It is not well understood how *H. ovis* enters the bloodstream or its original habitat; however, ROTHSCHILD et al. (2004) suggested that the possible source of infection could be the skin. Bacteria from the skin can enter into the systemic circulation due to lesions that break the skin barrier, leading to bacteremia, and may adhere to heart valves (ROBINSON & ROBINSON, 2016). In the present case, no surgical procedure was done, nor open wound or history of previous diseases was observed or reported.

Pneumonia was present and identified as respiratory distress. The presence of thrombus associated with Gram-positive colony, histopathologic pattern, diffuse and widely distributed emboli in lungs, and the presence of endocarditis in the right side of the heart support the statement that pneumonia was due to thromboembolism. Our findings contrast with the ones in ZHANG et al. (2009) and GARCÍA et al. (2012) were in sheep and goat, respectively, described bronchopneumonia caused by *H. ovis*. We believed that our report and the other two reports described above had a different route of infection. In thromboembolic pneumonia, the multifocal to widely diffuse lesions are associated with the hematogenous origin of the agent, in which a septic emboli present in other organs can detach and travel through the bloodstream, ending this way in blood vessels as it gets smaller and the emboli are not able to move onward leading to lesions in those locals, such as endocarditis can be the primary source. Conversely, the causative agent in bronchopneumonia has mainly the airborne as the route of entry, and the lesions in the lungs are primarily cranioventral (CASWELL & WILLIAMS, 2017).

The cow in this study had severe abomasal ulcers, abomasal ulceration can lead to blood loss consequently anemia. One of the clinical signs of anemia is pale mucous and severe anemia might cause respiratory distress (HETZEL et al., 1998). In this cow we believe the severe blood loss due to the ulceration have contributed to her death, the sudden blood loss may have complicated the clinical symptoms of endocarditis and pneumonia.

The methods used in classical bacteriology were unable to reach a definitive diagnosis and were necessary to use molecular analysis to define which species was involved. Thus, it was possible to define the species as *H. ovis* by combining molecular, epidemiological and pathological characteristics

involved in *H. ovis* endocarditis as well as biochemical characteristics of the species already described in the literature. Concerning the lack of bacterial growth of *H. ovis* in the lungs, numerous factors, such as sampling in non-infected areas or antimicrobial therapy, can influence the bacteriological diagnosis and the negative result does not necessarily represent that the suspected microorganism is not the etiologic agent involved in the lesions found in the lung. Besides, *H. ovis* shows growth in satellites, and the lack of inoculation with other bacteria (e.g. *Staphylococcus aureus*) may have disadvantaged the isolation of the agent (KUTZER et al., 2008).

In conclusion, the macroscopic, microscopic, bacteriologic and molecular findings were compatible with endocarditis caused by *H. ovis* in a dairy cow. To the author's best knowledge, this is the first report of this bacterium causing endocarditis in cattle in South America. Therefore, *H. ovis* is an uncommon and relatively unreported cause of disease in cattle.

## ACKNOWLEDGMENTS

The authors would like to thank CNPq (Conselho Nacional de Desenvolvimento Científico e Tecnológico) and CAPES (Coordenação de Aperfeiçoamento de Pessoal de Nível Superior) for financial support.

## SOURCES AND MANUFACTURES

Kasvi<sup>®</sup>, São José dos Pinhais-PR, Brazil.

## DECLARATION OF CONFLICT OF INTERESTS

The authors declare that they have no conflicts of interest of personal, academic, political or financial interests relating to the publication.

## AUTHORS' CONTRIBUTIONS

R.T Kemper, R.B. Rosa, F.A. Molossi, B. S. Cecco, R. S. Driemeier and L.Sonne contributed to the collection of the samples, made substantial contribution to gross and histopathological analysis, drafted and revised the manuscript and its final version. B.C. Lopes and F.Q. Mayer contributed to the microbiology and molecular analysis as well as drafting and revising the manuscript and its final version.

## REFERENCES

BEXIGA, R. et al. Clinicopathological presentation of cardiac disease in cattle and its impact on decision making. **The Veterinary Record**, v.162, n.18, p.575-580, 2008. Available from: <<https://veterinaryrecord.bmj.com/content/vetrec/162/18/575.full.pdf>> Accessed: Oct. 21, 2019. doi: 10.1136/vr.162.18.575.

- BUCZINSKI, S. et al. The diagnostic criteria used in bovine bacterial endocarditis: A meta-analysis of 460 published cases from 1973 to 2011. **The Veterinary Journal**, v.193, n.2, p.349-357, 2012. Available from: <<https://reader.elsevier.com/reader/sd/pii/S1090023312000822?token=390324833BD0F7ED9A293A0AD02FFB11A011384018D4B3E68199DFC5DE2F80BF9AB1EA295A272F3FFB0F693258A1A668>>. Accessed: Oct. 21, 2019. doi: 10.1016/j.tvjl.2012.02.012.
- CASWELL, J.F. & WILLIAMS, K.J. Respiratory system. In: ZACHARY, J.F. **Pathologic basis of veterinary disease**. St. Louis: Elsevier, 2017. Cap.5, p.523-653.
- COLLINS, M.D. et al. *Helcococcus ovis* sp. nov., a Gram-positive organism from sheep. **International Journal of Systematic Bacteriology**, v.49, n.4, p.1429-1432, 1999. Accessed in: Oct. 21, 2019. doi: 10.1099/00207713-49-4-1429
- GARCÍA, A., et al. *Helcococcus ovis* isolated from a goat with purulent bronchopneumonia and pulmonary abscesses. **Journal of Veterinary Diagnostic Investigation**, v. 24, n.1, p.235-237, 2012. Available from: <[https://journals.sagepub.com/doi/full/10.1177/1040638711425950?url\\_ver=Z39.88-2003&rfr\\_id=ori:rid:crossref.org&rfr\\_dat=cr\\_pub%3dpubmed](https://journals.sagepub.com/doi/full/10.1177/1040638711425950?url_ver=Z39.88-2003&rfr_id=ori:rid:crossref.org&rfr_dat=cr_pub%3dpubmed)>. Accessed: Jan. 30, 2020. doi: 10.1177/1040638711425950.
- GREEN, M.R. & SAMBROOK, J. Isolation and Quantification of DNA. In: GREEN M.R. & SAMBROOK J. **Molecular cloning**. New York: Cold Spring Harbor Laboratory Press, 2012, 4<sup>th</sup> Edition. p.1-80.
- HETZEL, T.M & LOSEK, J.D. Unrecognized severe anemia in children presenting with respiratory distress. **American Journal of Emergency Medicine**, v.16, n.4, p.386-389, 1998. Available from: <<https://www.ncbi.nlm.nih.gov/pubmed/9672458>>. Accessed: Jan. 30, 2020. doi: 10.1016/s0735-6757(98)90135-8.
- HUND, A. & WITTEK, T. Labmagengeschwür beim Rind. **Tierärztliche Praxis Großtiere**, v.45, n.2, p.121-128, 2017. Available from: <<https://www.thieme-connect.com/products/ejournals/html/10.15653/TPG-160754>> Accessed: Oct. 21, 2019. doi: 10.15653/tpg-160754.
- KOZICH, J.J. et al. Development of a Dual-Index Sequencing Strategy and Curation Pipeline for Analyzing Amplicon Sequence Data on the MiSeq Illumina Sequencing Platform. **Applied and Environmental Microbiology**, v.79, n.17, p.5112-5120, 2013. Available from: <<https://aem.asm.org/content/aem/79/17/5112.full.pdf>>. Accessed: Oct. 21, 2019. doi: 10.1128/aem.01043-13.
- KUTZER P. et al. *Helcococcus ovis*, an emerging pathogen in bovine valvular endocarditis. **Journal of Clinical Microbiology**, v.46, n.10, p.3291-3295, 2008. Available from: <<https://www.ncbi.nlm.nih.gov/pmc/articles/PMC2566082/pdf/0867-08.pdf>> Accessed: Oct. 21, 2019. doi: 10.1128/JCM.00867-08.
- MACDONALD, K. Infective endocarditis in dogs: diagnosis and therapy. **Veterinary Clinics of North America: Small Animal Practice**, v.40, n.4, p.665-684, 2010. Available from: <[https://www.vetsmall.theclinics.com/article/S0195-5616\(10\)00038-0/abstract](https://www.vetsmall.theclinics.com/article/S0195-5616(10)00038-0/abstract)>. Accessed: Oct. 21, 2019. doi: 10.1016/j.cvsm.2010.03.010.
- MEURS, K.M. Acquired heart diseases in cattle. In: ANDERSON, D.E. & RINGS, D.M. **Current Veterinary Therapy- Food Animal Practice**. St. Louis: Saunders Elsevier, 2009. Cap. 50, p.216-220.
- MILLER, L.M. & GAL, A. Cardiovascular system and lymphatic vessels. In: ZACHARY, J.F. **Pathologic basis of veterinary disease**. St. Louis: Elsevier, 2017. Cap.10, p.561-616.
- POST, K.W. et al. Valvular endocarditis associated with *Helcococcus ovis* infection in a bovine. **Journal of Veterinary Diagnostic Investigation**, v.15, n.5, p.473-475, 2003. Available from: <<https://journals.sagepub.com/doi/abs/10.1177/104063870301500513>> Accessed: Oct. 21, 2019. doi: 10.1177/104063870301500513.
- ROBINSON, W.F & ROBINSON, N.A. Cardiovascular system. In: MAXIE, M.G. **Pathology of Domestic Animals-Volume 3**. St. Louis: Elsevier, 2016. Cap.1, p.16-101.
- ROTHSCHILD, C.M. et al. *Helcococcus ovis* isolated from a pulmonary abscess in a horse. **Journal of Clinical Microbiology**, v.42, n.5, p.2224-2226, 2004. Available from <<https://www.ncbi.nlm.nih.gov/pmc/articles/PMC404590/>>. Accessed: Oct. 21, 2019. doi: 10.1128/JCM.42.5.2224-2226. 2004.
- ZHANG, Y. et al. Isolation of *Helcococcus ovis* from sheep with pleuritis and bronchopneumonia. **Journal of Veterinary Diagnostic Investigation**, v.21, n.1, p.164-166, 2009. Available from: <[https://journals.sagepub.com/doi/full/10.1177/104063870902100130?url\\_ver=Z39.88-2003&rfr\\_id=ori:rid:crossref.org&rfr\\_dat=cr\\_pub%3dpubmed](https://journals.sagepub.com/doi/full/10.1177/104063870902100130?url_ver=Z39.88-2003&rfr_id=ori:rid:crossref.org&rfr_dat=cr_pub%3dpubmed)>. Accessed: Jan. 30, 2020. doi: <https://doi.org/10.1177/104063870902100130>.