












## Assessment of prostate tissue remodeling in rats exposed to bisphenol A and the phytoestrogens genistein and indole-3-carbinol during the perinatal period

Éricka Stéphanhy Brandão Bueno<sup>1</sup>  Carlos Domingos Vieira Neto<sup>2</sup>  Alessandro Rodrigues<sup>2</sup>   
Thaina Cavalleri Sousa<sup>1</sup>  Karianne Delalibera Hinokuma<sup>1</sup>  Ariana Musa de Aquino<sup>3</sup>   
Wellerson Rodrigo Scarano<sup>4</sup>  Joyce Zalotti Brandt<sup>4</sup>  Leonardo de Oliveira Mendes<sup>1,5\*</sup> 

<sup>1</sup>Programa de Pós-graduação em Ciência Animal, Universidade do Oeste Paulista (UNOESTE), Presidente Prudente, SP, Brasil.

<sup>2</sup>Faculdade de Ciências da Saúde, Universidade do Oeste Paulista (UNOESTE), Presidente Prudente, SP, Brasil.

<sup>3</sup>Henry Ford Cancer Institute, Henry Ford Health, Detroit, MI, United States of America.

<sup>4</sup>Departamento de Biologia Estrutural e Funcional, Instituto de Biociências (IBB), Universidade Estadual Paulista (UNESP), Botucatu, SP, Brasil.

<sup>5</sup>Programa de Pós-graduação em Ciências da Saúde, Universidade do Oeste Paulista (UNOESTE), 19050-920, Presidente Prudente, SP, Brasil.  
E-mail: leobio85@gmail.com. \*Corresponding author.

**ABSTRACT:** Bisphenol A (BPA) is a compound known for its direct action on the prostate. Prostatic morphogenesis is a critical period when interference by any compound could permanently damage the organ. As such, the present study evaluated the morphological aspects resulting from gestational and lactational administration of BPA, indole-3-carbinol (I3C) and genistein (GEN) in prepubescent male rats. Pregnant Sprague Dawley females were allocated into 4 experimental groups and received the following: C: Control (no treatment); B: BPA (10 µg/Kg); BG: BPA+GEN (5 mg/Kg); BI: BPA+I3C (20 mg/Kg) from gestation day (GD) 17 to postnatal day (PND) 21. After euthanasia on PND22, the prostate was collected and processed. When administered alone, BPA reduced the stromal compartment when compared to group C ( $P = 0.039$ ). This decline was reversed in the groups submitted to GEN ( $P = 0.019$ ) or I3C ( $P = 0.017$ ). The groups treated with BPA ( $P < 0.0001$ ) and the phytoestrogens ( $P < 0.0001$ ) exhibited decreased epithelial height in relation to the control group. These changes were observed in stereological and morphometric analyses, but not in fractal analysis ( $P = 0.569$ ). The area occupied by collagen increased in groups treated with BPA ( $P < 0.0001$ ) and phytoestrogens ( $P < 0.0001$ ) in relation to controls, while collagen distribution values were higher in all the treated groups ( $P < 0.0001$ ), according to fractal analysis. Thus, BPA induced prostrate stroma remodeling with no influence from the phytoestrogens, which may affect glandular development and cause histopathological changes in adulthood.

**Key words:** prostate, environmental exposure, phytonutrients, endocrine disruptor.

### Avaliação da remodelação tecidual prostática em ratos expostos ao bisfenol A e aos fitoestrógenos genisteína e indol-3-carbinol durante o período perinatal

**RESUMO:** O Bisfenol A (BPA) é um composto conhecido pela sua ação direta na próstata. A morfogênese prostática é um período crítico e a interferência de qualquer composto pode acarretar danos permanentes a este órgão. Dessa forma, o presente estudo avaliou os aspectos morfológicos resultantes da administração gestacional e lactacional ao BPA, indol-3-carbinol (I3C) e genisteína (GEN) em ratos machos pré-púberes. Fêmeas prenhas da linhagem Sprague-Dawley foram divididas em quatro grupos experimentais e receberam: C: Controle; B: BPA (10 µg/Kg); BG: BPA+GEN (5 mg/Kg); BI: BPA+I3C (20 mg/Kg) do dia gestacional 17 até o dia pós-natal (DPN) 21. Após a eutanásia no DPN22 a próstata foi coletada e processada. O BPA quando administrado isoladamente ocasionou redução do compartimento estromal em comparação ao grupo C ( $P = 0,039$ ). Essa redução foi revertida nos grupos que foram submetidos à administração de GEN ( $P = 0,019$ ) ou I3C ( $P = 0,017$ ). Os grupos tratados com BPA ( $P < 0,0001$ ) e os fitoestrógenos ( $P < 0,0001$ ) apresentaram redução da altura epitelial quando comparados com o grupo C. Tais modificações encontradas nas análises estereomorfológicas não foram evidenciadas pela análise fractal ( $P = 0,569$ ). Verificou-se aumento da área ocupada pelo colágeno nos grupos submetidos à administração de BPA ( $P < 0,0001$ ) e fitoestrógenos ( $P < 0,0001$ ) em relação ao grupo C. Com relação ao padrão de distribuição dessas fibras, a análise fractal revelou maiores valores em todos os grupos tratados ( $P < 0,0001$ ). Assim, verificou-se que o BPA induziu remodelação no estroma prostático, sem influência dos fitoestrógenos, o que pode afetar o desenvolvimento glandular e provocar alterações histopatológicas na vida adulta.

**Palavras-chave:** próstata, exposição ambiental, fitonutrientes, desregulador endócrino.

## INTRODUCTION

Recent years have seen an increase in the environmental dissemination of chemical substances capable of interfering in hormone metabolism. These substances, known as endocrine disruptors

(EDs), have been reported as possibly causing toxic effects, even at low doses (ZHOU et al., 2018), and include substances classified as alkylphenols, pesticides, phthalates, polychlorinated biphenyls (PDBs) and plasticizers, such as bisphenol A (BILA & DEZZOTI, 2007).

Bisphenol A (BPA) is a synthetic monomer used to produce polycarbonate plastic and epoxy resins (BRANDT et al., 2014). Because it acts similarly to endogenous hormones, it is considered an ED, with exposure in humans occurring through food, drinks and skin contact (CALAFAT et al., 2008). BPA exposure can trigger problems at different stages of human development, the fetal period being the most critical due to the compound's ability to cross the placenta. This is because its chemical structure, similar to that of estrogens such as estradiol and diethylstilbestrol (HU et al., 2016), means it can act directly on tissue remodeling in reproductive organs (CAMPOS et al., 2015).

The hormone-dependent nature of the prostate and its extended window of susceptibility make it one of the organs most susceptible to BPA (SCARANO et al., 2018). Since its development begins in the intrauterine phase and ends after birth, gestational and lactational exposure is a critical period to assess the effects of chemical compounds on prostatic morphogenesis. There are also clear indications that BPA stimulates prostate cell proliferation and causes morphological changes (WU et al., 2016).

According to previous studies, other substances, such as phytochemicals, may also influence the prostatic microenvironment, albeit positively. These compounds are associated with pro-apoptotic, anti-inflammatory and antiproliferative activity (DAVE et al., 2005; LI et al., 2005) and can reverse the harmful effects of BPA. Two of the most noteworthy phytochemicals are genistein (GEN) and indole-3-carbinol (I3C).

GEN is known to inhibit cell proliferation and angiogenesis in tumor processes (CHAO, 2008), with foods derived from soybean as its main source (SETCHELL et al., 1998). It is important to note that, according to NAGATA et al. (2006), GEN can cross the placenta to the fetus, where high serum levels of this isoflavone have been found.

Another notable phytochemical in the scientific literature is I3C, the main bioactive compound reported in high concentrations in vegetables from the family Brassicaceae. In animals exposed to BPA during the perinatal period, I3C disrupted the response to estrogen and reduced estrogen receptor expression, promoting a potential antitumor effect and reversing prostate tissue alterations (BRANDT et al., 2014). The chemoprotection provided by dietary phytochemicals is linked to a decline in the incidence and progression of different neoplasms, mitigating inflammatory processes and oxidative stress caused

by potentially harmful substances, such as BPA (BILIR et al., 2017; KRIZOVÁ et al., 2019).

Fractal analysis is a particularly useful quantitative method for characterizing complex structures with a measurable value (fractal dimension), indicating variations in a structure as it is viewed on different scales, and can be used to assess DE-induced histopathological changes (TAMBASCO et al., 2009). The technique is based on the relationship between the resolution and scale of the object, with the result expressed by an equation. In urology, fractal dimension analysis is widely used to study prostate tumor tissue (DE ARRUDA et al., 2013).

The largely qualitative nature of morphological analyses means that tissue remodeling assessment remains uncertain, characterized by subjective, inaccurate interpretations, prompting the need for tools aimed at quantitatively and accurately analyzing and validating these data. As such, the objectives of the present study are to: (i) characterize prostate tissue remodeling in prepubescent rats exposed to BPA during the perinatal period; (ii) assess the influence of the phytochemicals GEN and I3C on the harmful effects of BPA in the prostate tissue microenvironment.

## MATERIALS AND METHODS

### *Animals and the experimental environment*

Male and female Sprague-Dawley (SD) rats of reproductive age were obtained from CEMIB-UNICAMP (Campinas, São Paulo state-SP) and kept in the vivarium of the Department of Pathology at the UNESP School of Medicine in Botucatu (SP), Brazil. The animals were allocated to polypropylene cages (41x34x16cm) for mating at a ratio of three females to one male (3:1) and; subsequently, two male offspring per cage. The cages were sealed with stainless steel wire bar lids and lined with autoclaved white pine shavings. Both the cages and shavings were changed twice a week. The environmental conditions in the vivarium were controlled throughout the experiment, as follows: temperature ( $22 \pm 2$  °C), relative humidity ( $55 \pm 10\%$ ), 12-hour light/dark cycle and continuous exhaust ventilation system. All the animals received commercial phytoestrogen-free feed (NUVILAB-CR1/Nuvital-PR) and filtered water in 500 mL sealed glass feeders with steel nozzles. Water and feed were provided *ad libitum*. The procedures for handling the animals, drug administration, anesthesia and euthanasia were approved by the Animal Ethics Committee of the School of Medicine in Botucatu (protocol number CEUA 1024-2013).

### *Bisphenol A, indole-3-carbinol and genistein*

BPA and the phytoestrogens I3C and GEN were purchased from Sigma-Aldrich (St. Louis, Mo, USA). BPA was diluted in dimethyl sulfoxide (DMSO) (carrier) at a concentration of 10 µg/Kg/day (PRINS et al., 2007), and I3C and GEN in corn oil at concentrations of 20 (WU et al., 2011) and 5 mg/kg/day (KALUDJEROVIC et al., 2012), respectively. All the substances were administered orally (gavage) to the female rats.

### *Experimental design*

After the acclimation period, three females and one male were allocated to each cage for 12h (dark period). The presence of sperm in the vaginal smear and positive vaginal cytology were considered indicative of gestational day 0 (GD 0) and these females were then housed individually.

Groups of pregnant females (n=8/group, 4 experimental groups) were orally administered (gavage) BPA (10 µg/Kg/day), I3C (20 mg/Kg) and GEN (5 mg/Kg) from GD17 to postnatal day 21 (PND21), the period of prostatic morphogenesis (PRINS et al., 2007). During this period the females were given water and phytoestrogen-free feed *ad libitum*. Thus, four experimental groups were formed: control (C); BPA (B); BPA+GEN (BG) and BPA+I3C (BI). After birth, the number of pups per litter was reduced to eight, preferably four females and four males.

On PND 22, the males were anesthetized in a CO<sub>2</sub> chamber, euthanized by decapitation and the prostate complex removed for histological analyses (Figure 1).

### *Analysis of the prostate structure*

The ventral prostate fragments were submitted to methacarn fixation for 3 hours (6 methanol: 3 chloroform: 1 acetic acid) and kept in 70% alcohol. Next, the material was dehydrated in solutions with increasing ethanol concentrations, cleared in xylene and embedded in paraplast (Oxford Labware, St. Louis, MO, USA). Cross-sections (4 µm thick) of the middle portion of the ventral prostate were prepared using a rotary microtome (Leica, Nussloch, Germany) and submitted to staining, as follows:

1. *hematoxylin and eosin (HE)*: analysis of fractal dimension, epithelial height and stereological analysis;
2. *picrosirius-hematoxylin (PSH)*: identify and quantify the area occupied by collagen, and fractal dimension analysis.

### *Stereological analysis*

HE-stained histological sections of 8 animals/group were analyzed by photographing 10 histological fields/section at 40x magnification and measuring the size of the epithelium, lumen and stroma using a Weibel grid. To that end, a Weibel grid

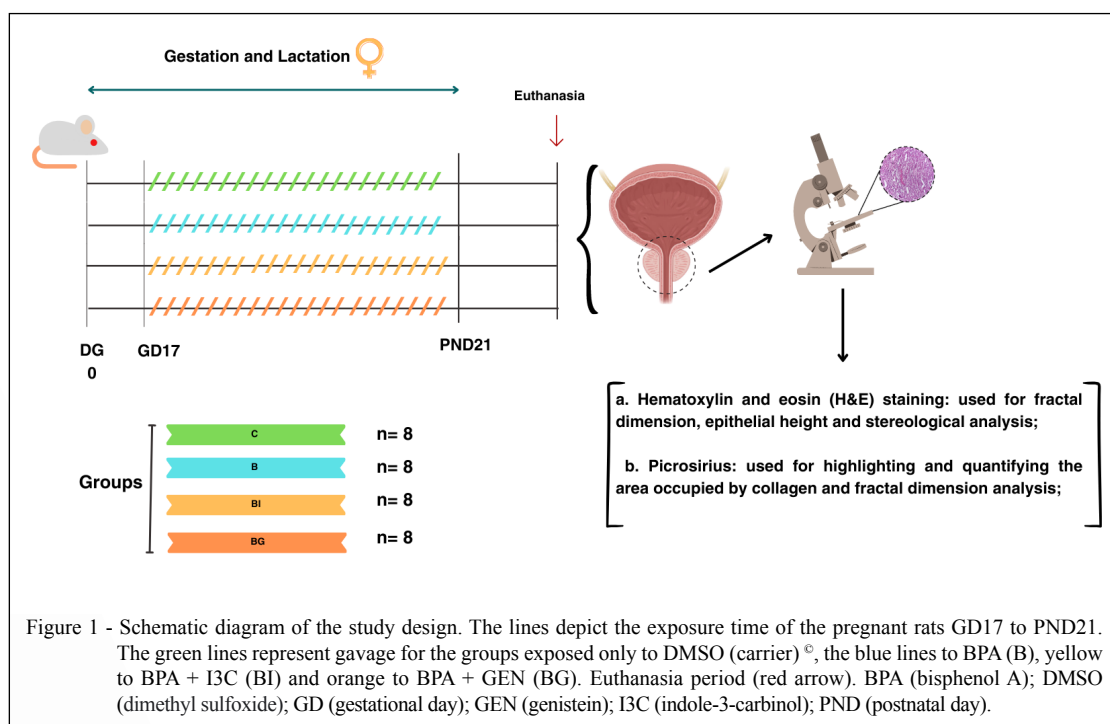


Figure 1 - Schematic diagram of the study design. The lines depict the exposure time of the pregnant rats GD17 to PND21. The green lines represent gavage for the groups exposed only to DMSO (carrier) <sup>®</sup>, the blue lines to BPA (B), yellow to BPA + I3C (BI) and orange to BPA + GEN (BG). Euthanasia period (red arrow). BPA (bisphenol A); DMSO (dimethyl sulfoxide); GD (gestational day); GEN (genistein); I3C (indole-3-carbinol); PND (postnatal day).

containing 168 points and 84 lines was superimposed on the histological image and the area occupied by the compartments manually counted (WEIBEL & PAUMGARTNER, 1978).

#### *Epithelial height analysis*

The epithelial height of the prostate tissue was determined in HE-stain histological sections according to the instructions provided by Image J software (The National Institutes of Health – NIH), available free of charge online (<http://rsbweb.nih.gov/ij/>), using the straight line selection tool. HE-stained histological sections of 8 animals/group were analyzed by photographing 10 histological fields/section at 40x magnification and measuring 5 different epithelial regions/histological field, using the tip to the base of the cell as standard.

#### *Fractal dimension*

HE-stained histological sections of 8 animals/group were photographed (10 fields/section) at 40x magnification and converted into binary images for reading and fractal dimension analysis. Image J software and the box-counting method (CURY et al., 2018) were used in two dimensions, enabling quantification of pixel distribution in the space and disregarding image texture. This means that two images with the same pixel distribution, one binary and the other grey scale, will have the same fractal dimension. The fractal histological slides were analyzed based on the ratio between the resolution and scale assessed and the result was quantitatively expressed as the fractal dimension of the object, as follows:  $FD = (\text{Log Nr} / \log r - 1)$ , where Nr is the number of equal elements needed to fill the original object and r the scale applied to that object. Thus, the fractal dimension calculated was always between 0 and 2, with no difference in textures.

#### *Quantification of the area occupied by collagen*

The reactive volume of collagen was quantified in the picrosirius-stained histological sections using Image J software (National Institute of Health, USA). Histological sections of five animals per groups were analyzed and photographed (10 histological fields/section, at 40x magnification), totaling 100 measurements per group. The system was programmed to only recognize red and estimate the collagen (stained red) percentage per histological field (AQUINO et al., 2019).

#### *Quantification of type I and III collagen*

The slides stained with picrosirius were analyzed under polarized light, which differentiates

between collagen types based on the intensity of the birefringent fibers, where red indicates type I collagen and green type III (JUNQUEIRA et al., 1978; Montes et al., 1980). Analysis was performed using the Image J software RGB tool, which separates the red, green, and blue channels of an RGB image (ImageJ, 2004), making it possible to identify and quantify collagen fibers.

#### *Statistical analysis*

The results obtained were statistically tested using the Shapiro-Wilk test, which demonstrated non-normal distribution for fractal dimension, epithelial height, stereological analysis, and collagen area. These data were submitted to the Kruskal-Wallis test and medians compared by Dunn's test (significance set at  $P < 0.05$ ). All statistical analyses were performed with GraphPad Prism software 8.0.

## RESULTS

When administered alone, BPA reduced the stromal compartment (Figure 2C, L) in relation to the control group (C:  $23.59 \pm 7.41$ ; mean B:  $19.99 \pm 7.76$ ;  $P = 0.039$ ) (Figure 2A, C and L). This decline reverted in groups treated with either GEN ( $24.05 \pm 8.69$ ;  $P = 0.019$ ) or I3C ( $24.54 \pm 9.70$ ;  $P = 0.017$ ) (Figure 2E, G, L).

The luminal compartment also decreased in the group submitted to GEN administration ( $33.70 \pm 10.48$ ) when compared to animals treated with BPA alone ( $38.77 \pm 10.49$ ;  $P = 0.019$ , Figure 2C, G and M). BPA reduced epithelial height in all the experimental groups (mean C:  $12.74 \pm 1.85$ ; B:  $11.81 \pm 1.81$ ; BI:  $11.01 \pm 1.71$ ; BG:  $11.28 \pm 1.80$ ;  $P < 0.0001$ ) (Figure 2J). Conversely in regard to the space this compartment occupies in prostate tissue, neither BPA nor the phytochemicals altered this parameter in relation to controls ( $P = 0.320$ , Figure 2K). Despite the BPA-induced changes observed, the fractal dimension was similar between the groups ( $P = 0.569$ , Figure 2I).

In relation to stromal collagen, the area occupied by these fibers increased in the BPA (Figure 3E, F and R) ( $3.32 \pm 1.95$ ;  $P < 0.0001$ ) and phytoestrogen-treated groups (BG:  $3.12 \pm 1.08$ ; BI:  $3.24 \pm 1.00$ ;  $P < 0.0001$ ) (Figure 3I, J, M and N) in relation to group C ( $0.80 \pm 0.52$ ) (Figure 3A and B).

Analysis under polarized light showed an increase in type I collagen in group B ( $10.06 \pm 0.39$ ;  $P < 0.001$ ) in relation to the other groups (C:  $9.66 \pm 0.25$ ; BI:  $9.72 \pm 0.23$ ; BG:  $9.78 \pm 0.25$ ) (Figures 3D, H, L, P and S), whereas type III collagen declined after isolated BPA administration ( $0.22 \pm 0.02$ ;  $P =$



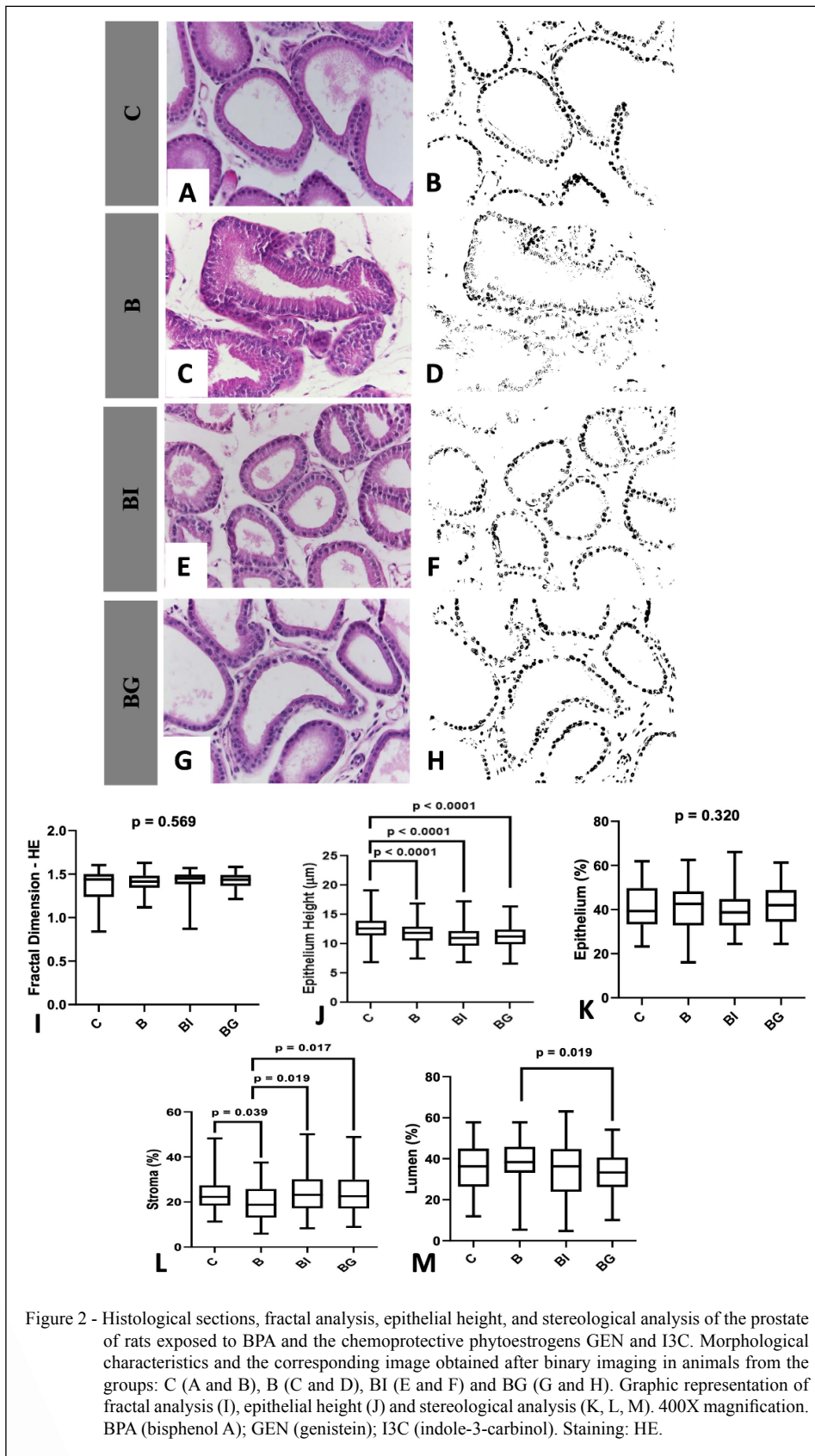
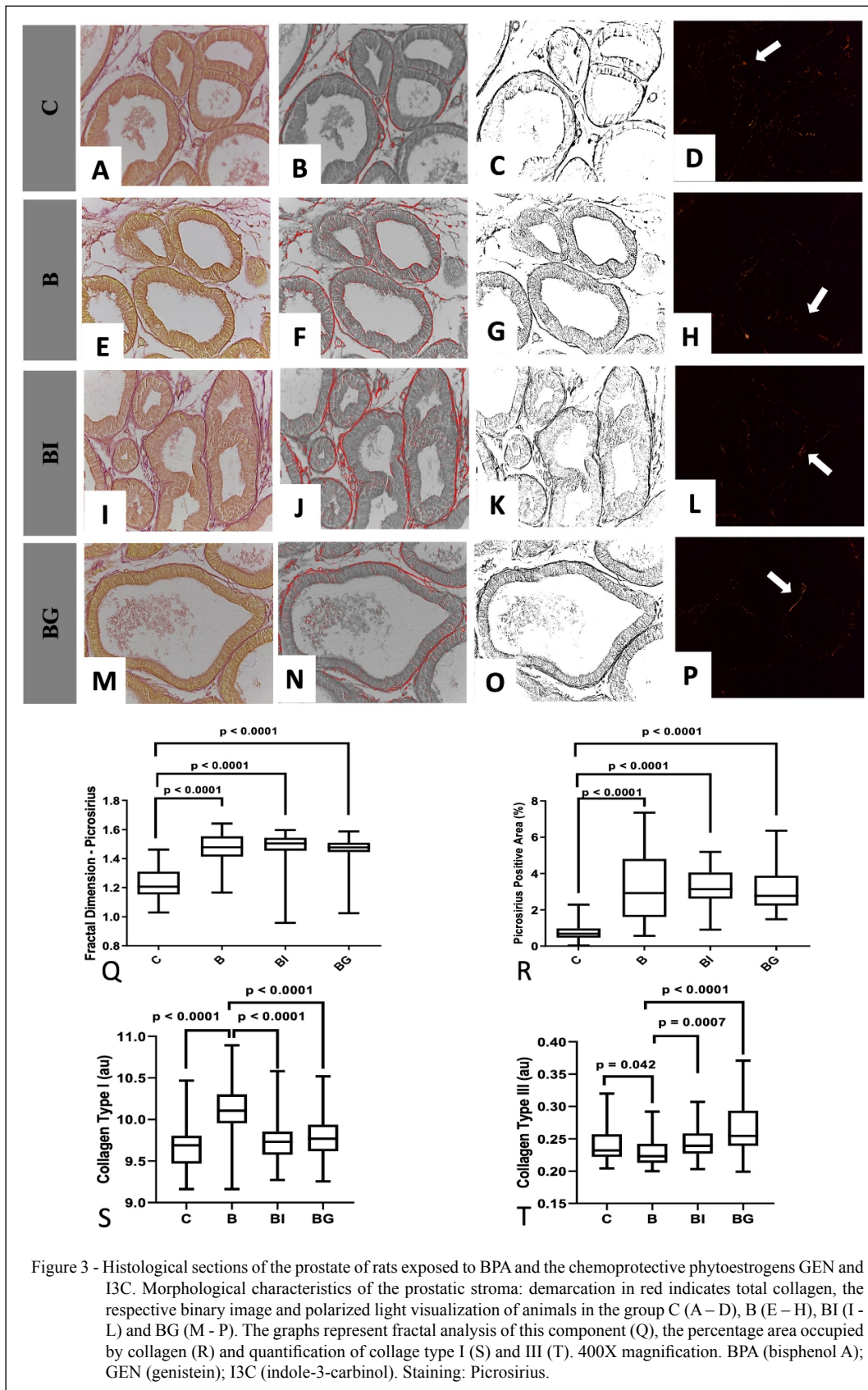


Figure 2 - Histological sections, fractal analysis, epithelial height, and stereological analysis of the prostate of rats exposed to BPA and the chemoprotective phytoestrogens GEN and I3C. Morphological characteristics and the corresponding image obtained after binary imaging in animals from the groups: C (A and B), B (C and D), BI (E and F) and BG (G and H). Graphic representation of fractal analysis (I), epithelial height (J) and stereological analysis (K, L, M). 400X magnification. BPA (bisphenol A); GEN (genistein); I3C (indole-3-carbinol). Staining: HE.



0.042) and increased with phytoestrogen application (BI:  $0.24 \pm 0.02$ ;  $P = 0.0007$ ) (BG:  $0.26 \pm 0.03$ ;  $P < 0.0001$ ) (Figure 3T).

With respect to the distribution pattern of these fibers, fractal analysis revealed higher values in all the treated groups (C:  $1.22 \pm 0.11$ ; B:  $1.46 \pm 0.11$ ; BI:  $1.46 \pm 0.13$ ; BG:  $1.45 \pm 0.11$ ;  $P < 0.0001$ ).

## DISCUSSION

The results obtained in the present study indicated prostate morphological alterations caused by gestational and lactational exposure to BPA and the phytochemical GEN and I3C. The changes were more pronounced in the stromal compartment, which declined under BPA administration, with an increase in the area occupied by collagen. The phytochemicals, in turn, increased the size of the stromal compartment, albeit without reversing the rise in collagen, with a similar fractal dimension to that of the BPA group.

The stromal collagen alterations observed in this study corroborated the research of BRANDT et al. (2014), who found that BPA exposure increases the density of collagen and reticular fibers around the prostatic acini. This is due to the change in the ductal budding pattern caused by perinatal BPA exposure, altering the distribution, number and aggregation of extracellular matrix elements, also observed by PRINS et al. (2007) and SCARANO et al. (2005). Other authors have also reported that administering compounds that mimic estrogen increases the stromal compartment (PRINS et al., 2007; SCARANO et al., 2005; 2008; BRANDT et al., 2014).

BERNARDO et al. (2015) also observed an increase in stromal compartment and reduction in luminal compartment for BPA doses of 25 and 250  $\mu\text{g}/\text{kg}/\text{day}$  administered during the perinatal period, with no changes in the epithelial compartment. The authors also demonstrated the protective role of GEN, which reversed stromal hyperplasia.

As such, BPA caused changes in the prostatic microenvironment in animals exposed during gestation and lactation. GOLUB et al. (2010) found that perinatal exposure to BPA can significantly change the cytoarchitecture and homeostasis of the prostate, with possible long-term effects. In line with these findings, PRINS et al. (2007) reported that early exposure to BPA may interfere in prostatic development, even inducing metaplasia, hyperplasia, and inflammation in adulthood.

BERNARDO et al. (2015) reported that GEN in the maternal diet may attenuate the harmful

effects on prostatic development of gestational exposure to low BPA doses, since GEN can easily cross the human placenta (BALAKRISHNAN et al., 2010). Conversely, KONG et al. (2013) controversially reported that low GEN doses may be toxic, resulting in behavioral and reproductive alterations, thus requiring further research to determine their effects in the prostatic microenvironment.

According to BRANDT et al. (2014), I3C can attenuate the harmful effects of gestational exposure to BPA, playing a chemoprotective role in the prostate. KIM et al. (2013), BRANDT et al. (2014) and LIU et al. (2014) found that I3C can act as a cell proliferation inhibitor and has antitumor properties. This may be attributed to the phytochemical's ability to inhibit type II metalloproteinase, the enzyme responsible for collagen degradation, culminating in accumulation of this protein in the prostatic stroma and; consequently, inhibiting possible metastatic processes (HUANG & CHENG, 2009). Similarly, DUCHNIK et al. (2019) conducted a study involving exposure to soybean isoflavones from the perinatal period to sexual maturity and found that these vegetable compounds are beneficial to collagen synthesis, increasing its expression in the skin of adult rats.

There is still no scientific consensus about the effects of BPA on the prostatic microenvironment, particularly regarding environmentally safe doses and exposure times for humans. In contrast to our findings, BRANDT et al. (2014) and BERNARDO et al. (2015) reported that a dose of 25  $\mu\text{g}/\text{kg}/\text{day}$  increased the stromal compartment and decreased its luminal compartment. However, 250  $\mu\text{g}/\text{kg}/\text{day}$  increased the lumen and reduced the stroma, exhibiting dose-dependent effects.

Given this wide range of discrepant results in the scientific literature, it is important to use tools that provide a more reliable morphological analysis. Thus; although, some authors, such as WALISZEWSKI et al. (2015), have questioned the use of fractal analysis, highlighting the lack of consensus between histology and fractal dimension. DE ARRUDA et al. (2013) suggested that a larger fractal dimension is associated with greater tissue disorganization. By contrast, PU et al. (2012) revealed higher values for this parameter in nontumor tissue. As such, despite the contrasting results in the scientific literature to obtain a response pattern for this technique, it is clearly effective in detecting histological differences between tissues, corroborating other analyses, such as those used in the present study.



## CONCLUSION

Exposure to BPA altered the prostatic microenvironment of prepubescent animals, particularly the stromal compartment, with no influence from the phytoestrogens, and can therefore affect gland development and cause histopathological changes in adulthood.

## ACKNOWLEDGMENTS

We are grateful to Universidade do Oeste Paulista (UNOESTE) for their institutional support, and the Fundação de Amparo à Pesquisa do Estado de São Paulo (FAPESP) (2012/24935-6). Coordenação de Aperfeiçoamento de Pessoal de Nível Superior (CAPES), Brasil - Finance code 001.

## DECLARATION OF CONFLICT OF INTEREST

There are no conflicts of interest to declare.

## AUTHORS' CONTRIBUTIONS

All the authors contributed equally to conceiving and writing the manuscript. All the authors critically reviewed the manuscript and approved the final version.

## BIOETHICS AND BIOSECURITY COMMITTEE APPROVAL

All the experiments were conducted in line with guidelines established by the Brazilian Animal Research Association (COBEA) and approved by the Animal Ethics Committee of the Botucatu School of Medicine (protocol number CEUA 1024-2013).

## REFERENCES

- AQUINO, A. M. et al. Arsenic exposure during prepuberty alters prostate maturation in pubescent rats. **Reproductive Toxicology**, v.89, p.136-144, 2019. Available from: <<https://doi.org/10.1016/j.reprotox.2019.07.010>>. Accessed: Apr. 21, 2021. doi: 10.1016/j.reprotox.2019.07.010.
- BALAKRISHNAN, B. et al. Transplacental transfer and biotransformation of genistein in human placenta. **Placenta**, v.31, n.6, p.506-511, 2010. Available from: <<https://doi.org/10.1016/j.placenta.2010.03.007>>. Accessed: Sept. 23, 2021. doi: 10.1016/j.placenta.2010.03.007.
- BERNARDO, B. D. et al. Genistein reduces the noxious effects of in utero bisphenol A exposure on the rat prostate gland at weaning and in adulthood. **Food and Chemical Toxicology**, v.84, p.64-73, 2015. Available from: <<https://doi.org/10.1016/j.fct.2015.07.011>>. Accessed: Sept. 01, 2021. doi: 10.1016/j.fct.2015.07.011.
- BILA, D. M.; DEZOTTI, M. Desreguladores endócrinos no meio ambiente: efeitos e consequências. **Química Nova**, v.30, n.3, p.651-666, 2007. Available from: <<https://doi.org/10.1590/S0100-4042200700030002>>. Accessed: Dec. 23, 2021. doi: 10.1590/S0100-4042200700030002.
- BILIR, B. et al. Effects of genistein supplementation on genome wide DNA methylation and gene expression in patients with localized prostate cancer. **International Journal of Oncology**, v.51, n.1, p.223-234, 2017. Available from: <<https://doi.org/10.3892/IJO.2017.4017>>. Accessed: Feb. 04, 2022. doi: 10.3892/IJO.2017.4017.
- BRANDT, J. Z. et al. Indole-3-carbinol attenuates the deleterious gestational effects of bisphenol A exposure on the prostate gland of male F1 rats. **Reproductive Toxicology (Elmsford, N.Y.)**, v.43, p.56-66, 2014. Available from: <<https://doi.org/10.1016/J.REPROTOX.2013.11.001>>. Accessed: Apr. 02, 2021. doi: 10.1016/J.REPROTOX.2013.11.001.
- CALAFAT, A. M. et al. Exposure of the U.S. Population to Bisphenol A and 4-tertiary-Octylphenol: 2003–2004. **Environmental Health Perspectives**, v.116, n.1, p.39, 2008. Available from: <<https://doi.org/10.1289/EHP.10753>>. Accessed: Feb. 02, 2022. doi: 10.1289/EHP.10753.
- CAMPOS, M. S. et al. Prepubertal exposure to bisphenol-A induces ER $\alpha$  upregulation and hyperplasia in adult gerbil female prostate. **International Journal of Experimental Pathology**, v.96, n.3, p.188-195, 2015. Available from: <<https://doi.org/10.1111/IJP.12120>>. Accessed: Sept. 22, 2022. doi: 10.1111/IJP.12120.
- CHAO, W. X. Health effects of soy protein and isoflavones in humans. **The Journal of Nutrition**, v. 138, n. 6, 2008. Available from: <<https://doi.org/10.1093/JN/138.6.1244S>>. Accessed: Feb. 18, 2021. doi: 10.1093/JN/138.6.1244S.
- CURY, S. S. et al. Fractal dimension analysis reveals skeletal muscle disorganization in mdx mice. **Biochemical and biophysical research communications**, v.503, n.1, p.109-115, 2018. Available from: <<https://doi.org/10.1016/j.bbrc.2018.05.189>>. Accessed: Feb. 21, 2022. doi: 10.1016/j.bbrc.2018.05.189.
- DAVE, B. et al. The soy isoflavone genistein promotes apoptosis in mammary epithelial cells by inducing the tumor suppressor PTEN. **Carcinogenesis**, v.26, n.10, p.1793-1803, 2005. Available from: <<https://doi.org/10.1093/CARCIN/BGI131>>. Accessed: Nov. 11, 2021. doi: 10.1093/CARCIN/BGI131.
- DE ARRUDA, P. F. et al. Quantification of fractal dimension and Shannon's entropy in histological diagnosis of prostate cancer. **BMC clinical pathology**, v.13, n.6, 2013. Available from: <<https://doi.org/10.1186/1472-6890-13-6>>. Accessed: Nov. 11, 2021. doi: 10.1186/1472-6890-13-6.
- DUCHNIK, E. et al. Effects of the soy isoflavones, genistein and daidzein, on male rats' skin. **Postepy Dermatologii i Alergologii**, v.36, n.6, p.760-766, 2019. Available from: <<https://doi.org/10.5114/ADA.2019.87280>>. Accessed: Sept. 13, 2021. doi: 10.5114/ADA.2019.87280.
- GOLUB, M. S. et al. Bisphenol A: developmental toxicity from early prenatal exposure. Birth Defects Research Part B: **Developmental and Reproductive Toxicology**, v.89, n.6, p.441-466, 2010. Available from: <<https://doi.org/10.1002/BDRB.20275>>. Accessed: Nov. 13, 2022. doi: 10.1002/BDRB.20275.
- HU, Y. et al. Bisphenol A, an environmental estrogen-like toxic chemical, induces cardiac fibrosis by activating the ERK1/2



- pathway. **Toxicology Letters**, v.250-251, p.1-9, 2016. Available from: <<https://doi.org/10.1016/J.TOXLET.2016.03.008>>. Accessed: Jun. 22, 2021. doi: 10.1016/J.TOXLET.2016.03.008.
- HUNG, W. C.; CHANG, H. C. Indole-3-carbinol inhibits Sp1-induced matrix metalloproteinase-2 expression to attenuate migration and invasion of breast cancer cells. **Journal of agricultural and food chemistry**, v.57, n.1, p.76-82, 2009. Available from: <<https://doi.org/10.1021/jf802881d>>. Accessed: Jun. 01, 2022. doi: 10.1021/jf802881d.
- JUNQUEIRA, L. C. et al. Differential staining of collagens type I, II and III by 496 Sirius Red and polarization microscopy. **Archivum Histologicum Japonicum**, v.41, n.3, p.267-74, 1978. Available from: <<https://doi.org/10.1679/aohc.46.589>>. Accessed: Dec. 13, 2021. doi: 10.1679/aohc.46.589.
- KALUDJEROVIC, J. et al. Early life exposure to genistein and daidzein disrupts structural development of reproductive organs in female mice. **Journal of Toxicology and Environmental Health. Part A**, v.75, n.11, p.649-660, 2012. Available from: <https://doi.org/10.1080/15287394.2012.688482>. Accessed: Jan. 05, 2022. doi: 10.1080/15287394.2012.688482.
- KIM, E. K. et al. Indole-3-carbinol and 3',3'-diindolylmethane modulate androgen's effect on C-C chemokine ligand 2 and monocyte attraction to prostate cancer cells. **Cancer Prevention Research (Philadelphia, Pa.)**, v.6, n.6, p.519-529, 2013. Available from: <https://doi.org/10.1158/1940-6207.CAPR-12-0419>. Accessed: Jan. 04, 2022. doi: 10.1158/1940-6207.CAPR-12-0419.
- KONG, D. et al. Individual and combined developmental toxicity assessment of bisphenol A and genistein using the embryonic stem cell test in vitro. **Food and Chemical Toxicology**, v.60, p.497-505, 2013. Available from: <<https://doi.org/10.1016/J.FCT.2013.08.006>>. Accessed: Sept. 12, 2021. doi: 10.1016/J.FCT.2013.08.006.
- KŘÍŽOVÁ, L. et al. Isoflavones. **Molecules** (Basel, Switzerland), v.24, n.6, 2019. Available from: <https://doi.org/10.3390/MOLECULES24061076>. Accessed: Feb. 12, 2022. doi: 10.3390/MOLECULES24061076.
- LIU, A. G. et al. Enhancement of broccoli indole glucosinolates by methyl jasmonate treatment and effects on prostate carcinogenesis. **Journal of Medicinal Food**, v.17, n.11, p.1177-1182, 2014. Available from: <<https://doi.org/10.1089/JMF.2013.0145>>. Accessed: Feb. 12, 2022. doi:10.1089/JMF.2013.0145.
- MONTES, G. S. et al. Histochemical and morphological characterization of reticular fibers. **Histochemistry**, v.65, n.2, p.131-41, 1980. Available from: <<https://doi.org/10.1007/BF00493161>>. Accessed: Feb. 28, 2021. doi:10.1007/BF00493161.
- NAGATA, C. et al. Associations among maternal soy intake, isoflavone levels in urine and blood samples, and maternal and umbilical hormone concentrations (Japan). **Cancer causes & control: CCC**, v.17, n.9, p.1107-1113, 2006. Available from: <<https://doi.org/10.1007/s10552-006-0044-4>>. Accessed: Feb. 28, 2021. doi: 10.1007/s10552-006-0044-4.
- PRINS, G. S. et al. Developmental estrogen exposures predispose to prostate carcinogenesis with aging. **Reproductive toxicology**, v.23, n.3, p.374-382, 2007. Available from: <<https://doi.org/10.1016/j.reprotox.2006.10.001>>. Accessed: Sept. 18, 2021. doi: 10.1016/j.reprotox.2006.10.001.
- PU, Y. et al. Determination of Optical Coefficients and Fractal Dimensional Parameters of Cancerous and Normal Prostate Tissues. **Applied Spectroscopy**, v.66, n.7, p.828-834, 2012. Available from: <<https://doi.org/10.1366/11-06471>>. Accessed: Sept. 2, 2021. doi: 10.1366/11-06471.
- SCARANO, W. R. et al. Tissue remodeling in Guinea pig lateral prostate at different ages after estradiol treatment. **Cell Biology International**, v.29, n.9, p.778-784, 2005. Available from: <<https://doi.org/10.1016/j.cellbi.2005.05.003>>. Accessed: Feb. 21, 2021. doi: 10.1016/j.cellbi.2005.05.003.
- SCARANO, W. R. et al. Cell junctions in the prostate: an overview about the effects of Endocrine Disrupting Chemicals (EDCS) in different experimental models. **Reproductive Toxicology**, v.81, p.147-154, 2018. Available from: <<https://doi.org/10.1016/j.reprotox.2018.08.009>>. Accessed: Feb. 21, 2021. doi: 10.1016/j.reprotox.2018.08.009.
- SETCHELL, K. D. et al. Isoflavone content of infant formulas and the metabolic fate of these phytoestrogens in early life. **The American Journal of Clinical Nutrition**, v.68, n.6 Suppl, p.1453S-1461S, 1998. Available from: <<https://doi.org/10.1093/ajcn/68.6.1453S>>. Accessed: Dec. 21, 2022. doi: 10.1093/ajcn/68.6.1453S.
- TAMBASCO, M. et al. Quantifying the architectural complexity of microscopic images of histology specimens. **Micron**, v.40, n.4, p.486-494, 2009. Available from: <<https://doi.org/10.1016/j.micron.2008.12.004>>. Accessed: Mar. 05, 2022. doi: 10.1016/j.micron.2008.12.004.
- WALISZEWSKI, P. et al. On the relationship between tumor structure and complexity of the spatial distribution of cancer cell nuclei: A fractal geometrical model of prostate carcinoma: Grading and Complexity. **Prostate**, v.75, n.4, p.399-414, 2015. Available from: <<https://doi.org/10.1002/pros.22926>>. Accessed: Mar. 16, 2021. doi: 10.1002/pros.22926.
- WEIBEL, E. R.; PAUMGARTNER, D. Integrated stereological and biochemical studies on hepatocytic membranes. II. Correction of section thickness effect on volume and surface density estimates. **The Journal of Cell Biology**, v.77, n.2, p.584-597, 1978. Available from: <<https://doi.org/10.1083/jcb.77.2.584>>. Accessed: Jan. 24, 2022. doi: 10.1083/jcb.77.2.584.
- WU, J. H. et al. Oral exposure to low-dose bisphenol A aggravates testosterone-induced benign hyperplasia prostate in rats. **Toxicology and Industrial Health**, v.27, n.9, p.810-819, 2011. Available from: <<https://doi.org/10.1177/0748233711399310>>. Accessed: Jan. 24, 2022. doi: 10.1177/0748233711399310.
- WU, J. Oral administration of low-dose bisphenol A promotes proliferation of ventral prostate and upregulates prostaglandin D2 synthase expression in adult rats. **Toxicology and Industrial Health**, v.32, p.1848-1858, 2016. Available from: <<https://doi.org/10.1177/0748233715590758>>. Accessed: Feb. 18, 2022. doi: 10.1177/0748233715590758.