



Missed iatrogenic partial disruption of the male urethra, caused by catheterization

Erich K. Lang, Quan D. Nguyen, Karl Zhang, Matthew H. Smith

Department of Imaging (EKL), Johns Hopkins Medical Institutions, Baltimore, Maryland, USA and Department of Radiology (EKL, QDN, KZ, MHS), SUNY Downstate Medical School, Brooklyn, New York, USA

This 37-year-old male presented at the emergency room with shortness of breath (SOB), a distended abdomen and a history of anuria for 2 days. Clinical examination revealed a left pleural effusion, cardiomegaly and ascites. An abdominal ultrasound confirmed the presence of massive ascites. The bladder appeared to be distended on ultrasound. The abdomen was not tender to palpation. The admission temperature was 37.6 C, BP 134/58, PR 86, and RR 20. Blood-chemistries showed the RBC 4.2 mil, WBC 6800, BUN 32, creatinine 2.6, glucose 106, K 4.2.

In view of the anuric status and apparently distended bladder, retrograde placement of a Foley catheter was attempted by the nurse. When she failed, a junior resident made a second attempt, but failed likewise. He did not introduce a parallel micro-catheter, which could have been used to inject contrast-laced jell to further outline the path of the urethra. A scout film of the abdomen revealed an ominous deviation of the tip of the catheter to the left (Figure-1 arrow), which was not appreciated. Urologic consult was requested. After a 6 hour delay the urologist noted the penile shaft to be swollen, the scrotum to be distended with fluid. The patient's temperature was now 38.4°C, and he complained of vague prepubic pain.

A computed tomogram of the pelvis with sagittal reconstruction was performed, demonstrating a distended bladder and significant fluid accumulation with interspersed gas in the pre- and retrourethral space (Figure-2 arrow). The tip of the catheter (Figure-2 dotted arrow) appeared to be outside the urethra and angled posteriorly. A suprapubic catheter was then inserted,

decompressing the bladder. Prior to removal of the Foley catheter a small amount of dilute non-ionic contrast medium was injected to delineate the urethra. The urethra was noted (Figure-3 arrow) to be displaced downward and posteriorly by massive urine extravasation in the anterior peri-urethral space (Figure-3 arrow-heads). Furthermore, note the subcutaneous air delineating the corpora cavernosa in the penile shaft (Figure-3 curved arrow). Finally an 8 French catheter was passed with an antegrade approach, via the suprapubic access site

Figure 1 – Ominous deviation of the tip of the catheter to the left (arrow).

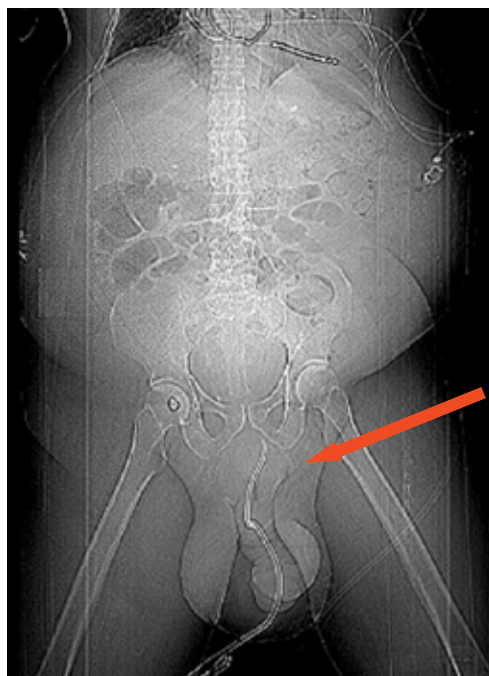
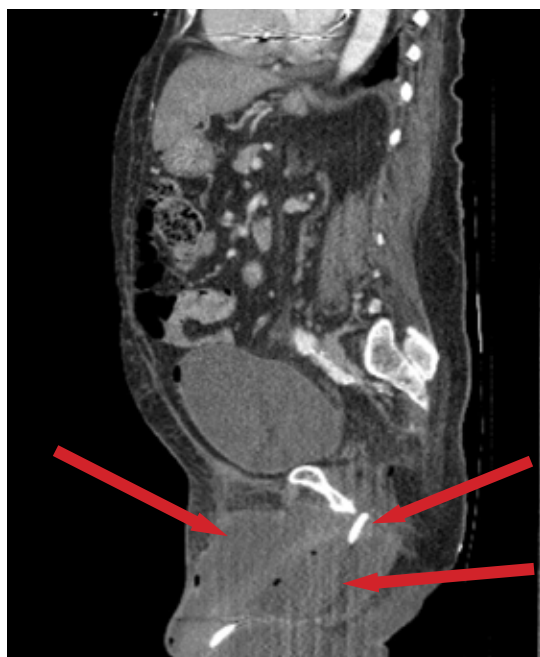

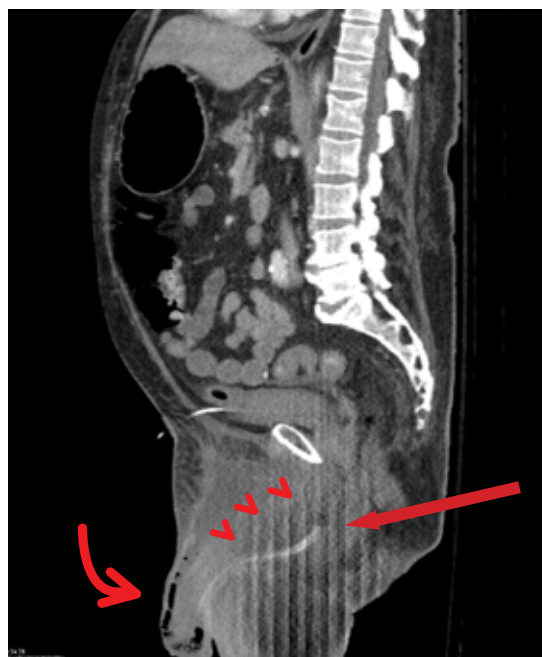
Figure 2 – Distended bladder and significant fluid accumulation with interspersed gas in the pre- and retrourethral space (arrows). Tip of the catheter (dotted arrow) appeared to be outside the urethra and angled posteriorly.



under fluoroscopic guidance across the only partly dehiscent urethra. It was left in position for 8 weeks as was the suprapubic catheter. Satisfactory healing, without a stricture at this point in time, resulted.

Seating of a Foley catheter in the male patient has a high rate of complication when performed by marginally or inexperienced operators (1). In male patients introduction of a parallel microcatheter to the point of perceived obstruction and delineation of the further path of the urethra by a mixture of non-ionic contrast medium and gel, may allow fluoroscopic guided placement of a guide-wire, which can then be safely followed by the Foley catheter. CT with sagittal and coronal reconstructions is the procedure of choice to identify leakage from partial or complete urethral dehiscence (2). Compared to the CT cysto-urethrogram, the retrograde cysto-urethrogram may identify only 17.8% of partial dehiscence with minimal leakage (2). Moreover, clinical symptoms are not reliable to predict urethral injury. TRUS however is a reliable technique for assessing injury to the female urethra (3).

Figure 3 - Urethra was noted (arrow) to be displaced downward and posteriorly by massive urine extravasation in the anterior peri-urethral space (arrow-heads). Furthermore, note the subcutaneous air delineating the corpora cavernosa in the penile shaft (curved arrow).



REFERENCES

1. Manalo M Jr, Lapitan MC, Buckley BS: Medical interns' knowledge and training regarding urethral catheter insertion and insertion-related urethral injury in male patients. *BMC Med Educ.* 2011; 11: 73.
2. Han KS, Choi HJ, Jung DC, Park S, Cho KS, Joung JY, et al.: A prospective evaluation of conventional cystography for detection of urine leakage at the vesicourethral anastomosis site after radical prostatectomy based on computed tomography. *Clin Radiol.* 2011; 66: 251-6.
3. Ying T, Li Q, Shao C, Zhu Z, Feng L, Hu B: Value of transrectal ultrasonography in female traumatic urethral injuries. *Urology.* 2010; 76: 319-22.

Correspondence address:

Dr. Erich K. Lang
Departments of Urology and Radiology
SUNY, Downstate Health Science Center
455 Lenox Road
Brooklyn, NY, 11203, USA
E-mail: erich.lang@downstate.edu