

# Oral adverse effects of head and neck radiotherapy: literature review and suggestion of a clinical oral care guideline for irradiated patients

Elen de Souza TOLENTINO<sup>1</sup>, Bruna Stuchi CENTURION<sup>1</sup>, Lúcia Helena Caetano FERREIRA<sup>2</sup>, Andréia Pereira de SOUZA<sup>3</sup>, José Humberto DAMANTE<sup>4</sup>, Izabel Regina Fischer RUBIRA-BULLEN<sup>5</sup>

1- DDS, MSc, PhD student, Department of Stomatology, Bauru School of Dentistry, University of São Paulo, Bauru, SP, Brazil.

2- Undergraduate student, Bauru School of Dentistry, University of São Paulo, Bauru, SP, Brazil.

3- DDS, Bauru School of Dentistry, University of São Paulo, Bauru, SP, Brazil.

4- DDS, MSc, PhD, Full Professor, Department of Stomatology, Bauru School of Dentistry, University of São Paulo, Bauru, SP, Brazil.

5- DDS, MSc, PhD, Associate Professor, Department of Stomatology, Bauru School of Dentistry, University of São Paulo, Bauru, SP, Brazil.

**Corresponding address:** Bruna Stuchi Centurion - Rua Capitão Gomes Duarte, 20-40 apto 208 - Bauru-SP, Brazil - 17012-226 - Phone: 14 3206 3404 / 17 8144 3404. - e-mail: brcenturion@usp.br

**Received: December 03, 2009 - Modification: May 10, 2010 - Accepted: October 26, 2010**

## ABSTRACT

Radiotherapy, alone or associated with surgery or chemotherapy, produces a significant increase in cure rates for many malignancies of the head and neck region. However, high doses of radiation in large areas, including the oral mucosa, may result in several undesired reactions that manifest during or after the completion of therapy. The multidisciplinary management is the best alternative to minimize or even prevent such reactions, and the dentist has a fundamental role in this context. This paper reviews the literature related to the main oral sequelae from head and neck radiotherapy and establishes clinical oral management protocol for these irradiated patients.

**Key-words:** Radiotherapy. Radiation effects. Head and neck neoplasms. Mucositis. Osteoradionecrosis. Xerostomia.

## INTRODUCTION

With increasing dental awareness and elderly population, it is reasonable to expect that more and more dentate patients will be diagnosed with head and neck cancer.

Radiotherapy, alone or associated with surgery or chemotherapy, has produced a significant increase in cure rates for many malignancies of the head and neck region<sup>23</sup>. However, high doses of radiation in large areas, including the oral mucosa, skin, maxilla, mandible and salivary glands may result in several undesired reactions that manifest during or after the completion of therapy. This damage is caused by the ionizing radiation in normal tissues located in the radiation field<sup>27</sup>.

Mucositis, candidosis, dysgeusia, radiation caries, osteoradionecrosis, soft tissue necrosis, progressive periodontal attachment loss, trismus and xerostomia are some of radiotherapy's complications, significantly affecting patients'

quality of life.

Implementation of oral care protocols before and after radiation therapy and frequent assessment of lesions during therapy can prevent or, at least, decrease the incidence and severity of these complications. The literature is confusing about the establishment of a clinical care guideline. Therefore, this paper discusses the main adverse effects of head and neck radiotherapy and proposes a clinical oral management protocol for patients undergoing this treatment.

## LITERATURE REVIEW

Radiation-induced changes can be divided into two groups, based on the usual time of their occurrence: early or acute side effects that are noted during or immediately after treatment; and late side effects that develop months or years after the end of radiation therapy<sup>23</sup>. The degree, progression and no reversibility of these changes are related to the

radiation dose, the irradiation field, the degree of hypovascularity and hypocellularity of tissues, the age at diagnosis and the healing capacity of the exposed epithelial cells<sup>6,25</sup>. There are many oral complications related to the radiation treatments and the most prevalent are discussed in this work:

### Mucositis

Mucositis is the most common acute side effect experienced by patients undergoing head and neck radiotherapy<sup>23</sup>. In almost all cases the patients experience confluent mucositis by approximately the third week of treatment<sup>10</sup>. Mucosal damage occurs because of decreased cell renewal in the epithelium, which causes mucosal atrophy and ulceration<sup>6</sup>. This is accompanied by pain, burning and discomfort, which are greatly aggravated by contact with highly spicy foods. When the irradiation field involves the pharyngeal mucosa, it may produce difficulties in swallowing and speech.

Clinically, mucositis is characterized by inflammation, erythema, mucosal atrophy, exulceration and ulceration of the oral mucosa with or without pseudomembranes (Figure 1).

### Salivary gland dysfunction

Head and neck radiotherapy commonly damages the salivary glands, decreasing the salivary flow rate and changing salivary composition<sup>7</sup>. As a result, the sensation of oral dryness (xerostomia) occurs early during the irradiation treatment<sup>1</sup>. The duration of depressed salivary function varies among patients. Recovery of adequate saliva may be gradual over several months or may result in permanent glandular changes that cause irreversible loss of ability to secrete saliva<sup>16,19</sup>. The extent of radiation-induced salivary dysfunction depends on the dose of radiation, the volume of irradiated gland tissue and the nature of the salivary glands being irradiated<sup>18</sup>. The functional impairment of salivary glands results in impeded oral functioning, a burning sensation, cracked lips, and increased susceptibility to oral infections and dental caries<sup>10,33</sup>. Radiation therapy also changes the composition of saliva, increasing its viscosity, reducing its buffering capacity, altering its concentration of electrolytes, and changing its nonimmune and immune antibacterial systems<sup>10,19,33</sup>.

### Radiation caries

Changes in the chemical composition of saliva and increased amounts of cariogenic oral bacteria result in rapid decalcification of dental enamel. Radiation caries is not caused directly by irradiation, but results from the sequelae of xerostomia: decrease of pH, reduced buffering capacity, and increased viscosity<sup>23</sup>. Clinically it has a rampant form, and tends to spread to all dental surfaces,

changing their translucency and color. The carious process can cause increased friability and the breakdown of teeth. The most common type is widespread superficial lesions attacking buccal, occlusal, incisal and palatal surfaces<sup>35</sup>.

### Craniofacial disturbances

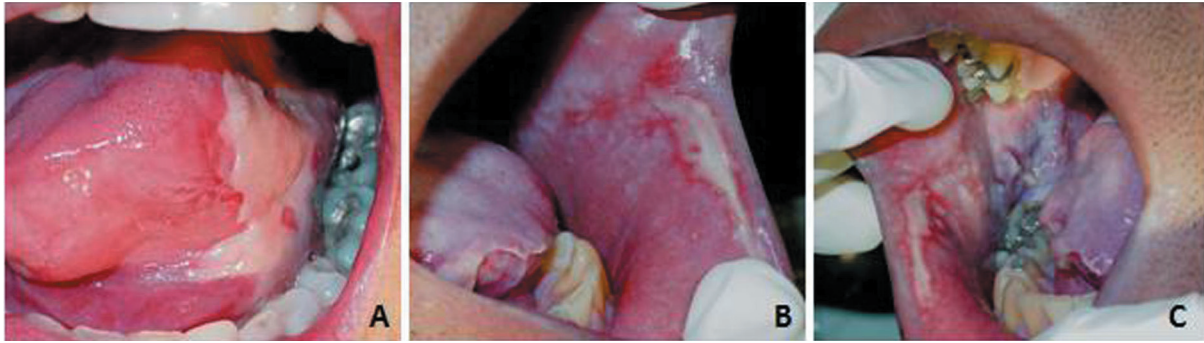The craniofacial disturbances are those that shall occur when radiation therapy is performed in children. This way, irradiation may induce some disturbances in the craniofacial region, if it is performed in earlier stages, when teeth are still being formed.

Abnormally small teeth (microdontia), short or blunted roots, small crowns, malocclusion, incomplete calcification, enlarged pulp chambers (taurodontism), premature closure of apices and delayed or arrested development of teeth have been reported<sup>7,22,24</sup>. The occurrence of these changes in the primary teeth can cause significant malocclusion and may adversely affect facial development<sup>23</sup>. Children undergoing radiation therapy may experience abnormalities in the growth and maturation of craniofacial skeletal structures<sup>4,26</sup>. Craniofacial and dental abnormalities can cause severe cosmetic or functional sequelae, necessitating surgical or orthodontic intervention.

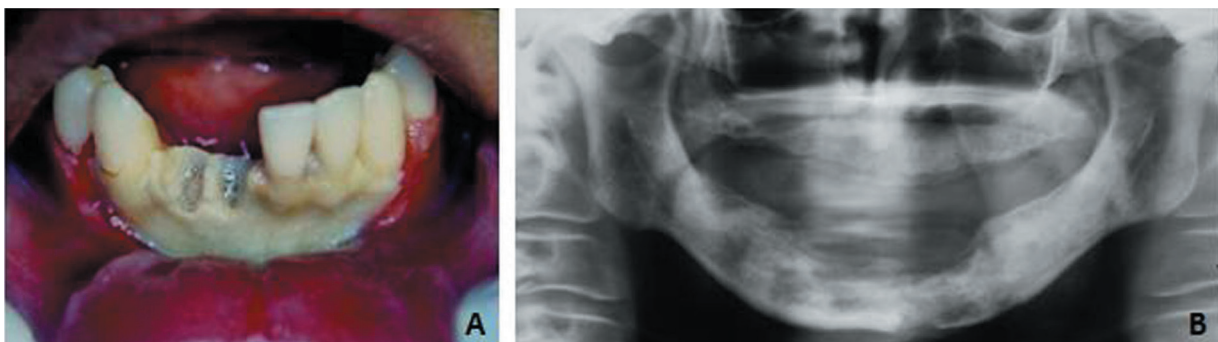
### Osteoradionecrosis

One of the most severe adverse effects of radiotherapy is osteoradionecrosis, an inflammatory condition resultant of the bone ionizing radiation. This radiation results in irreversible damages to the osteocytes and the microvascular system, with a progressive decrease of the microvascularization. The tissue becomes hypovascular, hypocellular and hypoxic. All these features avoid the bone healing, and it can proceed to a necrosis with or without infection. These changes in bone result from injury to the remodeling system (osteocytes, osteoblasts and osteoclasts), causing atrophy, osteoradionecrosis and pathological fractures<sup>13,33</sup>. Tooth extraction and dental disease in irradiated regions have long been recognized as major risk factors for the development of osteoradionecrosis<sup>13</sup>. The mandible is much more susceptible to osteoradionecrosis than the maxilla, because its vascularization is poor and bone density is high. This adverse effect usually occurs within one year of therapy. Radiologic features include ill-defined cortical destruction with or without sequestration<sup>18</sup>.

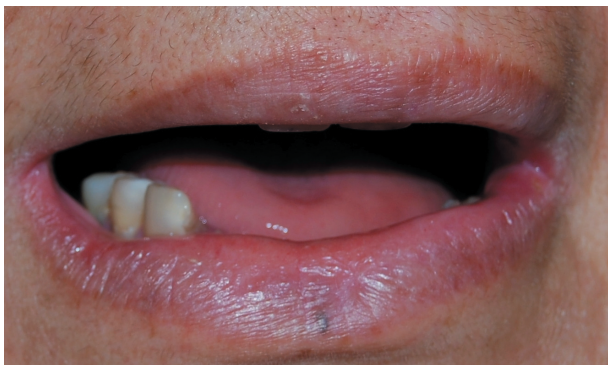Clinical manifestations of osteoradionecrosis may include pain, orofacial fistulas, exposed necrotic bone, pathologic fracture and suppuration<sup>10</sup>. The patient may presents clinical signs and symptoms of ulceration or necrosis on the mucosa, with exposure of necrotic bone for longer than 3 months. Radiographically, irregular bone destruction is



**Figure 1-** A: Mucosal atrophy and ulceration with pseudomembrane in the lateral tongue border; B and C: Diffuse erythema and ulceration with pseudomembrane in the tongue and lip mucosa of a patient subjected to head and neck radiotherapy (photographs kindly provided by Dr. Juliana Bertoldi Franco)



**Figure 2-** A: Clinical aspect of bone exposure and necrosis in a patient with osteoradionecrosis after radiotherapy treatment (photograph kindly provided by Dr. Marcos Martins Curi). B: Panoramic radiograph showing irregular osteolytic areas in the mandible of a patient with osteoradionecrosis



**Figure 3-** Limited mouth opening in a woman subjected to radiotherapy after a nasopharyngeal carcinoma 8 years before

observed and the mandible is most frequently involved (Figure 2). Associated symptoms of pain, trismus, and suppuration in the area of the lesion may also be present. The progression of this process can lead to pathologic fracture and intraoral and/or extraoral fistula<sup>11</sup>.

### Trismus

Chronic reduction in oral opening is relatively uncommon in the general population but may be

seen in a significant proportion of patients who have undergone treatment for an oral cancer by surgery, radiotherapy, chemotherapy or combinations of these.

The mechanisms by which mandibular hypomobility due to the radiotherapy develops, and the factors which determine speed of onset, severity, and extent, are poorly understood. Its development is thought to progress in three phases: an initial nonspecific inflammatory phase, a fibrotic cellular phase, and a matrix densification and remodeling phase<sup>3</sup>. It is generally viewed to be the result of fibrosis leading to a loss of flexibility and extension. Usually temporomandibular joint hypomobility is regarded as a late effect of high radiation dose. An oral opening lower than 20 mm can be considered as trismus<sup>22</sup> (Figure 3).

## DISCUSSION AND MANAGEMENT PROTOCOLS

Radiotherapy is a treatment modality largely used for head and neck malignancies and although presents a significant increase in cure rates, it is still associated with several and complex oral complications. This therapy presents many

challenges primarily because the head and neck region has many critical structures that can be damaged by tumor or treatment. Damage to these tissues by tumor or therapy can result in significant structural, cosmetic and functional deficits that negatively impact on quality of life<sup>14</sup>. Of the long-term survivors treated with head and neck radiation therapy, 77% to 100% have mild-to-severe radiation damage of soft tissues and bones<sup>24,26</sup>.

The major clinical problem for patients developing oral mucositis is pain. Its adverse consequences include a decreased ability to eat, speak and sleep. The loss of the integrity of the oral mucosa also predisposes patients to systemic infections with bacteria, yeast and viruses<sup>23</sup>. Current care for patients with mucositis is essentially palliative and includes appropriate oral hygiene, dietary modifications and mucosal protectants. Special attention should be given to plaque control and oral hygiene. The protocol adopted by our service agrees with Otmani<sup>23</sup> (2007), who recommends the use of nonalcoholic antiplaque rinses (like isotonic saline or sodium bicarbonate solution) to maintain oral moistness and decrease pathogenic flora. We recommended the use of topical anesthetics for pain relief, such as 2% viscous lidocaine or tetracaine-chloride (hexomedine spray), unless the pain requires systemic analgesic drugs, such non-steroids or opioids. Antimicrobial agents must be considered for either fungal or bacterial infections<sup>10,17</sup>. In our opinion, the use of complete dentures in this period should be discontinued. The dentures should be cleaned and immersed in a 0.5% sodium hypochlorite solution for 30 min. If necessary to substitute the dentures, it is recommendable to do it only at the end of the therapy. Indeed, a study of Sandoval, et al.<sup>29</sup> (2003) showed that low-energy laser was well tolerated and showed beneficial effects on the management of oral mucositis, improving the quality of life during the oncologic treatment.

Rubira, et al.<sup>28</sup> (2007) evaluated the oral sequelae of radiotherapy in patients treated for head and neck tumors and showed that the main effect of radiotherapy in the head and neck region was a reduction of the salivary flow rate. Several moistening agents and saliva substitutes are recommended to relief the discomfort due to hyposalivation<sup>1</sup>. In this situation, we strongly recommend increasing amounts of liquid ingested, use of artificial saliva, use of non-alcoholic mouthrinses with 0.12% chlorhexidine for plaque control, and topical fluoride application to avoid caries development. In some cases, we also prescribe dribbling lemon or 2% citric acid in the tongue dorsum to stimulate salivation as long as the patient does not suffer from mucositis.

Some studies show that prophylactic treatment

with specific cholinergic receptor agonists (e.g., pilocarpine) temporarily protects salivary-gland cells from acute radiation damage, reducing symptoms of xerostomia and mucosal toxicity<sup>9,16</sup>. Johnson, et al.<sup>13</sup> (1993) evaluated pilocarpine hydrochloride for the treatment of radiation-induced xerostomia to test its safety and efficacy in reversing the decrease in the production of saliva. Patients received either placebo or pilocarpine (5 mg or 10 mg orally three times a day) for 12 weeks and were evaluated at base line and every 4 weeks. There was overall improvement in 54% of the 5-mg group as compared with 25% of the placebo group. Saliva production was improved, but it did not correlate with symptomatic relief. There were comparable improvements in the group receiving the 10-mg dose. The primary adverse effect was sweating, in addition to other minor cholinergic effects. Six and twenty-nine percent of the patients in the 5-mg and 10-mg groups, respectively, withdrew from the study because of adverse effects. According to these authors, there were no serious adverse effects related to pilocarpine.

Nakamura, et al.<sup>20</sup> (2009) evaluated 39 patients with xerostomia which received pilocarpine (5 mg three times a day) for at least for 12 weeks unless they had experienced unacceptable adverse effects. All patients received radiotherapy that included the parotid glands in the radiation field >50 Gy. The toleration rate was only 47%. The most common adverse effect was sweating with an incidence of 64%. The author concluded that for Japanese, 5 mg t.i.d. pilocarpine caused a high incidence of unacceptable adverse effects. A lower dose of pilocarpine needs to be considered.

In our service, we avoid using pilocarpine because of the several adverse effects of this medicament, such as excessive sweating, nausea, diarrhea, chills, flushing, rhinitis, dizziness, headache, asthenia, urinary frequency, vasodilatation and bradycardia. Pilocarpine is contraindicated in patients with asthma, hypersensitivity and ophthalmologic diseases (miosis). We only prescribe pilocarpine in cases of really severe hyposalivation (such as salivary flow rates lower than 0.1 mL/min without stimulus in patients refractory to other treatments), after medical examination and consent. In addition, administration of medications that are known to induce xerostomia (e.g., anorectic, antiemetic, antihistaminic, antihypertensive and antidepressant agents) should be carefully considered.

Because of the hyposalivation, patients also could develop dysgeusia and deglutition disorders, which influence in their nutritional and systemic conditions. Therefore, the low immunity may allow the establishment of opportunist infections, such as candidiasis, a common fungal infection caused by *Candida albicans*. Rubira, et al.<sup>28</sup> (2007) found a

significant correlation between the higher frequency of candidiasis and post radiotherapy time (39.3 months;  $p=0.028$ ). In most cases, we adopt the use of nystatin 100,000 IU/mL, in oral suspension, t.i.d, for 15 days. More severe cases require the use of systemic medication, such as fluconazole 150 mg, one tablet a week, for 1 or 2 weeks, if necessary.

The decision to extract tooth before or after radiotherapy has traditionally been based on clinical experience and empirically designed protocols. The literature data regarding dental evaluation and extraction are confusing and inconclusive, showing conflicting results when comparing extractions before and after radiation therapy, and the main cause of this decision is the possibility to develop osteoradionecrosis<sup>15</sup>. To minimize the risk of developing osteoradionecrosis, optimal precautions should be adopted. These include complete removal of the nonrestorable teeth as soon as possible to maximize the healing period. When osteoradionecrosis results in small lesions of the bone, daily saline irrigations and antibiotic coverage are recommended<sup>23</sup>. For advanced presentations of osteoradionecrosis (pathologic fracture, fistula, full-thickness devitalization of bone), segmental mandibular resection with free vascularized-bone grafting become the standard of care. If osteoradionecrosis is of fibroblastic origin, treatment with antioxidants and antifibrotic drugs may be promising<sup>31</sup>. Treatment of avascular osteonecrosis of the jaws involves a variety of therapies that include antibiotics, 0.12% chlorhexidine mouthwash, sequestrectomy, surgical resection of the necrotic bone, and hyperbaric oxygen therapy<sup>2</sup>.

An important point when considering dental extractions before radiotherapy is the time interval between dental extractions and the beginning of radiation therapy. This time must be sufficient for initial healing and to allow that tissues support the radiation delivered. However, the healing time should not be extended a long period that could compromise the oncologic treatment and prognosis<sup>15</sup>.

Some studies have shown that the use of hyperbaric oxygen resulted in improved local control and survival of the irradiated patients<sup>11,34</sup>. The hyperbaric oxygen therapy is one option to decrease the side effects of radiotherapy, without the adverse effects of some medicaments.

The prevalence of post-radiotherapy mandibular hypomobility has been reported to vary between 5% and 38%<sup>30,32</sup>. The variable incidence of mandibular hypomobility within this patient cohort appears to depend on a number of factors, which include the location of the tumor, the nature and extent of surgery, the field of tissue irradiated, the use of combined surgery and adjunctive radiotherapy, and

the level of movements performed by the patient in the period immediately following treatment. Similarly, individual patient variation may have an effect, including advanced age, obesity, reduced tissue vascularity and other co-morbidities, such as hypertension, diabetes and connective tissue diseases<sup>8</sup>.

A systematic review of mandibular hypomobility in head and neck oncology described the effects of therapeutic interventions as being scarcely investigated<sup>5</sup>. Although many of the interventions described have some rationale, there is little, if any, high quality evidence to support them. Treatment therefore tends to be pragmatic and empirical, and the chosen modality will be dependent on the cause of the hypomobility. Some of the usually instituted treatments include physical and thermal therapies, massage, dietary advice, mandibular opening devices and simple exercises, electrotherapy, surgery and drugs<sup>8</sup>. We refer our patients to physical therapy, which consists in the modalities cited above.

The management of irradiated patients is a challenge to the dentist. Most of the clinicians do not know when and how intervene in these patients. There is no consensus in the literature about a standard oral attendance protocol to prevent and treat the patients in these cases. For this reason, based on the reviewed literature and considering the absence of an established protocol of intervention of head and neck irradiated patients, we propose an oral clinical care guideline for these patients (Figure 4). Preferably, the patients should not undergo oral procedures during radiotherapy. These interventions should be done before or after the radiation treatment.

Oral procedures must be accomplished 20 to 30 days before the first session of radiotherapy, for tissue repair and healing. After the radiotherapy treatment, the dentist can perform non-invasive procedures, such as small restorations; placement of new prostheses should wait 3 months; and at least 6 months should be have been elapsed to perform surgeries. The invasive procedures should be accomplished under prophylactic antibiotic therapy since the microvasculature of the bone is

	Before radiotherapy	After radiotherapy
Non-invasive procedures	20 days	3 months
Invasive procedures	30 days	6 months*

\* Prophylactic antibioticotherapy recommended

Figure 4- Suggestion of a clinical oral management protocol to head and neck irradiated patients

affected. We prescribe clindamycin-chloride 300 mg 2 h before the procedure and clindamycin-chloride 300 mg is maintained every 6 h for 7 days. Rehabilitation with osseointegrated implants must be avoided for at least 12 months (Figure 4). Indeed, a multidisciplinary treatment, including physicians, dentists, speech therapy, nutritionists, and psychologists, is the best alternative to minimize or even prevent such reactions.

## CONCLUSION

The oral management protocol of head and neck irradiated patients suggested in this work aimed to improve the approaching of these cases, which require special attention and knowledge by dental professionals. Early or late radiotherapy sequelae persist throughout years and the dentist should be able to decide how to minimize pain and morbidity of these patients, as well as know the moment to step in. It is evident that the most important aspect to consider is the knowledge of radiation exposure, volume, modality, urgency, general state and prognosis of each case. Professionals should know that each case is particular and unique and that all factors already mentioned must be considered if the patient needs to undergo surgery.

## ACKNOWLEDGEMENTS

The authors would like to thank Dr. Marcos Martins Curi and Dr. Juliana Bertoldi Franco for their support to this study.

## REFERENCES

- Andrews N, Griffiths C. Dental complications of head and neck radiotherapy: Part 2. *Aust Dent J*. 2001;46(3):174-82.
- Curi MM, Cossolin GS, Koga DH, Araujo SR, Feher O, Santos MO, et al. Treatment of avascular osteonecrosis of the mandible in cancer patients with a history of bisphosphonate therapy by combining bone resection and autologous platelet-rich plasma: report of 3 cases. *J Oral Maxillofac Surg*. 2007;65(2):349-55.
- Delanian S, Lefaix JL. The radiation-induced fibroatrophic process: therapeutic perspective via the antioxidant pathway. *Radiother Oncol*. 2004;73(2):119-31.
- Denys D, Kaste SC, Kun LE, Chaudhary MA, Bowman LC, Robbins KT. The effects of radiation on craniofacial skeletal growth: a quantitative study. *Int J Pediatr Otorhinolaryngol*. 1998;45(1):7-13.
- Dijkstra PU, Kalk WW, Roodenburg JL. Trismus in head and neck oncology: a systematic review. *Oral Oncol*. 2004;40(9):879-89.
- Dörr W, Hamilton CS, Boyd T, Reed B, Denham JW. Radiation-induced changes in cellularity and proliferation in human oral mucosa. *Int J Radiat Oncol Biol Phys*. 2002;52(4):911-7.
- Duggal MS. Root surface areas in long-term survivors of childhood cancer. *Oral Oncol*. 2003;39(2):178-83.
- Garnett MJ, Nohl FS, Barclay SC. Management of patients with reduced oral aperture and mandibular hypomobility (trismus) and implications for operative dentistry. *Br Dent J*. 2008;204(3):125-31.
- Gornitsky M, Shenouda G, Sultanem K, Katz H, Hier M, Black M, et al. Double-blind randomized, placebo-controlled study of pilocarpine to salvage salivary gland function during radiotherapy of patients with head and neck cancer. *Oral Surg Oral Med Oral Pathol Oral Radiol Endod*. 2004;98(1):45-52.
- Hancock PJ, Epstein JB, Sadler GR. Oral and dental management related to radiation therapy for head and neck cancer. *J Can Dent Assoc*. 2003;69(9):585-90.
- Henk JM, Smith CW. Radiotherapy and hyperbaric-oxygen in head and neck cancer. Interim report of second clinical trial. *Lancet*. 1977;2(8029):104-5.
- Jereczek-Fossa BA, Orecchia R. Radiotherapy-induced mandibular bone complications. *Cancer Treat Rev*. 2002;28(1):65-74.
- Johnson JT, Ferretti GA, Nethery WJ, Valdez IH, Fox PC, Ng D, et al. Oral pilocarpine for post-irradiation xerostomia in patients with head and neck cancer. *N Engl J Med*. 1993;329(6):290-5.
- Ko C, Citrin D. Radiotherapy for the management of locally advanced squamous cell carcinoma of the head and neck. *Oral Dis*. 2009;15(2):121-32.
- Koga DH, Salvajoli JV, Alves FA. Dental extractions and radiotherapy in head and neck oncology: review of the literature. *Oral Dis*. 2008;14(1):40-4.
- Konings AW, Coppes RP, Vissink A. On the mechanism of salivary gland radiosensitivity. *Int J Radiat Oncol Biol Phys*. 2005;62(4):1187-94.
- Köstler WJ, Hejna M, Wenzel C, Zielinski CC. Oral mucositis complicating chemotherapy and/or radiotherapy: options for prevention and treatment. *CA Cancer J Clin*. 2001;51(5):290-315.
- Mitchell MJ, Logan PM. Radiation-induced changes in bone. *Radiographics*. 1998;18(5):1125-36.
- Möller P, Perrier M, Ozsahin M, Monnier P. A prospective study of salivary gland function in patients undergoing radiotherapy for squamous cell carcinoma of the oropharynx. *Oral Surg Oral Med Oral Pathol Oral Radiol Endod*. 2004;97(2):173-89.
- Nakamura N, Sasano N, Yamashita H, Igaki H, Shiraishi K, Terahara A, et al. Oral pilocarpine (5 mg t.i.d.) used for xerostomia causes adverse effects in Japanese. *Auris Nasus Larynx*. 2009;36(3):310-3.
- Oh HK, Chambers MS, Martin JW, Lim HJ, Park HJ. Osteoradionecrosis of the mandible: treatment outcomes and factors influencing the progress of osteoradionecrosis. *J Oral Maxillofac Surg*. 2009;67(7):1378-86.
- Okeson JP. Management of temporomandibular disorders and occlusion. St. Louis: Mosby; 1998.
- Otmani N. Oral and maxillofacial side effects of radiation therapy on children. *J Can Dent Assoc*. 2007;73(3):257-61.
- Paulino AC, Simon JH, Zhen W, Wen BC. Long-term effects in children treated with radiotherapy for head and neck rhabdomyosarcoma. *Int J Radiat Oncol Biol Phys*. 2000;48(5):1489-95.
- Prott FJ, Handschel J, Micke O, Sunderkötter C, Meyer U, Piffko J. Long-term alterations of oral mucosa in radiotherapy patients. *Int J Radiat Oncol Biol Phys*. 2002;54(1):203-10.
- Raney RB, Anderson JR, Kollath J, Vassilopoulou-Sellin R, Klein MJ, Heyn R, et al. Late effects of therapy in 94 patients with localized rhabdomyosarcoma of the orbit: report from the Intergroup Rhabdomyosarcoma Study (IRS)-III, 1984-1991. *Med Pediatr Oncol*. 2000;34(6):413-20.
- Rosales AC, Esteves SC, Jorge J, Almeida OP, Lopes MA. Dental needs in Brazilian patients subjected to head and neck radiotherapy. *Braz Dent J*. 2009;20(1):74-7.
- Rubira CM, Devides NJ, Ubada LT, Bortolucci AG Jr, Lauris JR, Rubira-Bullen IR, et al. Evaluation of some oral postradiotherapy sequelae in patients treated for head and neck tumors. *Braz Oral Res*. 2007;21(3):272-7.
- Sandoval RL, Koga DH, Buloto LS, Suzuki R, Dib LL. Management of chemo- and radiotherapy induced oral mucositis with low-energy laser: initial results of A.C. Camargo Hospital. *J Appl Oral Sci*. 2003;11(4):337-41.

- 30- Steelman R, Sokol J. Quantification of trismus following irradiation of the temporomandibular joint. *Mo Dent J*. 1986;66(6):21-3.
- 31- Teng MS, Futran ND. Osteoradionecrosis of the mandible. *Curr Opin Otolaryngol Head Neck Surg*. 2005;13(4):217-21.
- 32- Thomas F, Ozanne F, Mamelle G, Wibault P, Eschwege F. Radiotherapy alone for oropharyngeal carcinomas: the role of fraction size (2 Gy vs 2.5 Gy) on local control and early and late complications. *Int J Radiat Oncol Biol Phys*. 1988;15(5):1097-102.
- 33- Vissink A, Jansma J, Spijkervet FK, Burlage FR, Coppes RP. Oral sequelae of head and neck radiotherapy. *Crit Rev Oral Biol Med*. 2003;14(3):199-212.
- 34- Watson ER, Halnan KE, Dische S, Saunders MI, Cade IS, McEwen JB, et al. Hyperbaric oxygen and radiotherapy: a Medical Research Council trial in carcinoma of the cervix. *Br J Radiol*. 1978;51(611):879-87.
- 35- White SC, Pharoah MJ. *Oral radiology: principles and Interpretation*. St. Louis: Mosby; 2004.