

Features of the female prostate according to age: an autopsy study

Características da próstata feminina de acordo com a idade: um estudo de autópsia

Thalita Cristina M. Costa; Patrícia M. Cury; Ana Maria G. Custódio

Faculdade de Medicina de São José do Rio Preto, São Paulo, Brazil.

ABSTRACT

Introduction: The prostate gland plays an important role in male and female reproductive system. Data on this organ have not been fully explored in women since its first description, probably because it is considered a vestigial gland. **Objective:** To correlate the morphology of the female prostate with age in autopsy. **Material and methods:** Thirty-two female cadavers, 31 adults and one newborn, underwent dissection of the region corresponding to the prostate for histological analysis. The urethral region was divided into three portions: proximal, median, and distal. All the glands present in the samples were counted. Clinical data were collected, including age and previous diagnosis of menopause. **Results:** There were no macroscopically visible prostate. Morphological analyses showed glands surrounding the urethra with a stratified epithelium, ranging from squamous to columnar types, with prevalence of basophilic cells and some presenting with secretion inside. A significant correlation with prostate tissue was found between the median and the proximal urethra, as well as between the median and distal urethra, suggesting that when the glandular structures increase in the median region, there is also an increase in the anterior and distal structures. Moreover, a prevalence of the glands in the median urethra was observed in post-menopausal women. **Conclusion:** This study suggests that the number of female prostate glands increases after menopause, with proliferative spread and growth of the median portion to the proximal and distal portions.

Key words: prostate; women; menopause.

INTRODUCTION

The prostate gland plays a role in both male and female reproductive systems. Data on this organ have not been fully explored in women since its first description, probably because it is considered a vestigial gland and due to its limited study in autopsy material⁽¹⁾. Recent experimental studies with rodents have increased the knowledge of the female prostate⁽²⁻⁸⁾.

In 1672, Renier de Graaf identified the first mammal female prostate as a group of glands surrounding the urethra, similar to the male prostate. In 1880, Alexander J. C. Skene observed the presence of two paraurethral ducts opening around the urethra, with no obvious function, which were identified as Skene's paraurethral glands, considered a vestigial organ. In 1906, Barnett also identified these deep urethral glands and described their location between the bladder neck and the external urethral meatus, near to the urethra, and above the pubocervical fascia. The

anatomy of the female prostate differs from that of the male organ. In men, the prostate surrounds the urethra and is encapsulated, while in women it is not well defined, does not have a capsule, and can not be macroscopically observed⁽¹⁾.

Histologically, the female prostate has more ducts than glands; the opposite occurs in men. The glands are presented either in groups or isolated; they are composed of basal and secreting cells; the latter may be cylindrical, cubic, or columnar. Intermediate cells may be observed by electron microscopy among these cell types⁽¹⁾.

The prostate location in the urethra may vary, and is more commonly seen in the distal portion. However, it may be observed in the proximal (meatal type), distal (posterior type), and in the entire urethra (rudimentary type)⁽¹⁾.

The female prostate plays an important role in reproduction, since it supports spermatozoa in the female body, providing nutrients through the prostate fluid, which has the same features

as that the male⁽⁹⁾, and affects the sexual behavior⁽¹⁾. Some studies have associated the female prostate with the Gräfenberg point (G-point), reporting that ejaculation may be stimulated by the G-point⁽¹⁰⁾, while other authors advocate the idea that they are the same structure⁽¹¹⁾.

Few studies have investigated the prostate in healthy women; thus, compared to the extensive knowledge about male prostate, the female prostate features are still not fully understood. According to Dodson (1994)⁽¹²⁾, prostate markers and prostate specific antigen (PSA) were found in urethral syndrome, urethral carcinoma, and breast cancer, but the normal female prostate pattern has not been fully described. Thus, the present study was performed in order to correlate prostate morphology with age in female cadavers.

MATERIAL AND METHODS

Female cadavers were submitted to autopsy at a Death Certification Service, over a period of 10 months, the regions corresponding to the prostate were subjected to dissection and analysis. The research ethics committee of the institution approved the study. The exclusion criteria were: presence of body decomposition, loss of urethral region integrity, and stillborn child.

The bladder and urethra were dissected and abdominally removed in a single portion during autopsy, and the material was preserved in 10% buffered formalin. The entire urethral region was transversally divided into three segments after being separated from the bladder – proximal, median, and distal samples – and embedded in paraffin.

These 3-5 µm blocks from each cadaver were sectioned at three different levels (proximal, median, and distal portions), with the distal portion corresponding to the urethral meatus. The slides were stained with hematoxylin-eosin (HE) and examined by light microscopy. To characterize the presence of prostate tissue and its prevalent site, the number of glands on each slice (anterior, median, posterior samples) was determined.

Clinical data including age, leading cause of death, and underlying causes of death were obtained from the death certificate of each subject. Information regarding the diagnosis of menopause and urinary tract infection for the case studies were obtained from medical records.

Data on morphological features of prostate at different ages were statistically analyzed using Fisher's exact test, analysis of variance and the Kruskal-Wallis test, and Spearman's correlation coefficient was calculated.

RESULTS

Clinical analysis

Thirty-two female cadavers were studied; there were 31 adults with an average age of 60.6 years (range: 25-96 years) and one newborn. The main causes of death reported in the death certificate were acute heart failure and bronchopneumonia (nine and seven cases, respectively). Among 21 patients with available data on menopause, menopausal status was determined in 14. Moreover, only three patients had a history of urinary tract infection among the six patients with available data (**Table 1**).

Morphological analysis

Thirty-two urethras were dissected from the female cadavers studied over a period of 10 months, but seven could not be analyzed due to autolysis on the material. One case of a child was not included in the statistical analysis due to the lack of similar cases for comparison.

No macroscopic prostate was visualized in the cases. The prostate tissue was histologically identified in all cadavers studied (**Table 2**). Glands were predominantly found in the proximal, median, and distal regions of 10, seven, and six cases, respectively. In one case, the urethra showed no prevalent region for the gland.

Morphological analysis showed glands surrounding the urethra, which presented a stratified epithelium ranging from squamous to columnar types; basophils were prevalent, and some glands showed secretion. A dense stromal tissue was observed around the glands (**Figure 1**).

Nine prostate tissues were considered as cystic, and most showed internal calculus (**Figure 2**). One case of paraurethral bleeding was found (**Figure 3**), 12 cases showed an increase in vascular structures (paraurethral ectasia), and chronic lymphocytic inflammation was observed in 62% of cases (**Figure 4**).

Statistical analysis

Data were analyzed aiming to establish a statistical correlation between the histological data from the autopsy material with individual's age and clinical parameters. The material of a stillborn and seven prostate tissues could not be analyzed due to a lack of similar cases for comparison and because of poor preservation, respectively. Therefore, 24 prostate tissues were considered for statistical analysis.

According to Fisher's exact test, no correlation was found between menopause and inflammation, bleeding, cystic structures, or urinary tract inflammation or infection ($p =$

0.15, $p = 1$, $p = 0.17$, $p = 0.40$, respectively). No statistically significant correlation between age and prevalent regions for gland was found by analysis of variance ($p = 0.53$) (Figures 5 to 8).

Since the number of glands did not show a regular pattern according to age, Spearman's test was used instead of the Pearson's correlation test. Significant correlations were found between the median and proximal urethral portions (Spearman's correlation: 0.430, $p = 0.034$), as well as between the median and distal urethras (Spearman's correlation: 0.438, $p = 0.032$), suggesting the occurrence of an increase in anterior and distal structures when the median region structures are increased. The Kruskal-Wallis test revealed a predominance of the prostate glands in the median urethra of women who had reached menopause ($H = 6.47$, $p = 0.011$, adjusted for ties) (Table 3).

DISCUSSION

Histological analysis of the autopsy material revealed glands composed of both squamous and columnar epithelium surrounding the urethra, with a dense stromal tissue around these structures, as also reported in the literature^(9, 12-15).

According to Zaviačić (1998)⁽¹⁾, the female prostate can be classified into several types. The anterior, proximal, or meatal types are the richest in prostate tissue, located in the distal half of the female urethra, in the anterior urethra, and behind the urethral meatus. These are the most common type, observed in 66% of cases. The posterior or distal type is the largest prostate tissue, and has been found in the posterior urethra extending to the vesical neck (10% of cases). The rudimentary type includes a small number of glands and ducts that have been found in the entire urethra (8% of cases). Another prostate type has been

TABLE 1 – Clinical data from the female cadavers studied

Patient	Age	Cause of death	Urinary tract infection	Menopause
1	96	Bronchopneumonia	Unknown	Yes
2	75	Bronchopneumonia	Unknown	Yes
3	85	Cardiogenic pulmonary edema	Unknown	Yes
4	54	Acute heart failure	Unknown	Unknown
5	51	Acute heart failure	No	Unknown
6	74	Bronchopneumonia	Yes	Yes
7	60	Not determined	Yes	Yes
8	58	Bronchopneumonia	No	No
9	72	Acute heart failure	Unknown	Unknown
10	76	Acute heart failure	Unknown	Unknown
11	43	Meningitis	Unknown	Unknown
12	74	Acute heart failure	Unknown	Unknown
13	54	Cardiogenic pulmonary edema	Unknown	Unknown
14	47	Acute heart failure	Unknown	No
15	25	Bronchopneumonia	Unknown	Unknown
16	75	Pulmonary hemorrhage	Unknown	Yes
17	71	Acute heart failure	Unknown	Yes
18	65	Cardiogenic pulmonary edema	Unknown	Yes
19	45	Cardiogenic pulmonary edema	No	No
20	68	Neutropenic fever	Unknown	Yes
21	96	Acute heart failure	Unknown	Yes
22	40	Bronchopneumonia	Yes	No
23	81	Arrhythmia	Unknown	Yes
24	0 (NB)	Congenital malformation	Unknown	Unknown
25	38	Cardiogenic pulmonary edema	Unknown	Unknown
26	76	Arrhythmia	Unknown	Yes
27	64	Cardiogenic pulmonary edema	Unknown	Yes
28	39	Cardiac tamponade	Unknown	No
29	42	Acute heart failure	Unknown	No
30	25	Bronchopneumonia	Unknown	No
31	53	Encephalic vascular accident	Unknown	Unknown
32	85	Cardiogenic pulmonary edema	Unknown	Yes

NB: newborn.

TABLE 2 – Histological characteristics of prostate glands

Patient	Age	Number of prostate glands			Total number of gland	Paraurethral inflammation	Paraurethral ectasia	Paraurethral bleeding	Cystic gland
		Proximal urethra	Median urethra	Distal urethra					
1	96	168	17	13	198	Yes	No	No	Yes
2	75	98	15	67	180	No	No	Yes	Yes
3	85	0	10	0	10	No	No	No	Yes
4	54	28	7	6	41	Yes	Yes	No	No
5	51	28	10	20	58	Yes	No	No	No
6	74	17	15	19	51	Yes	Yes	No	No
7	60	9	30	20	59	No	No	No	No
8	58	5	5	4	14	Yes	Yes	No	No
14	47	1	16	6	23	Yes	No	No	No
16	75	34	16	8	58	No	No	No	Yes
17	71	107	64	48	219	No	No	No	Yes
18	65	38	8	9	55	No	Yes	No	Yes
19	45	12	10	10	32	Yes	Yes	No	No
20	68	23	26	6	55	Yes	Yes	No	No
21	96	6	8	2	16	Yes	Yes	No	No
22	40	15	3	0	18	Yes	Yes	No	No
23	81	72	17	19	108	No	Yes	No	No
26	76	7	23	43	73	No	Yes	No	No
27	64	35	44	30	109	Yes	No	No	No
28	39	47	27	59	133	Yes	No	No	No
29	42	8	5	26	39	No	No	No	Yes
30	25	5	0	43	48	Yes	Yes	No	No
31	53	6	11	24	41	Yes	Yes	No	Yes
32	85	14	31	25	70	Yes	No	No	Yes

TABLE 3 – Features of prostate glands and menopause

Patient	Number of prostate glands			Total number of gland	Menopause
	Proximal urethra	Median urethra	Distal urethra		
1	168	17	13	198	Yes
2	98	15	67	180	Yes
3	0	10	0	10	Yes
6	17	15	19	51	Yes
7	9	30	20	59	Yes
8	5	5	4	14	No
14	1	16	6	23	No
16	34	16	8	58	Yes
17	107	64	48	219	Yes
18	38	8	9	55	Yes
19	12	10	10	32	No
20	23	26	6	55	Yes
21	6	8	2	16	Yes
22	15	3	0	18	No
23	72	17	19	108	Yes
26	7	23	43	73	Yes
27	35	44	30	109	Yes
28	47	27	59	133	No
29	8	5	26	39	No
30	5	0	43	48	No
32	14	31	25	70	Yes

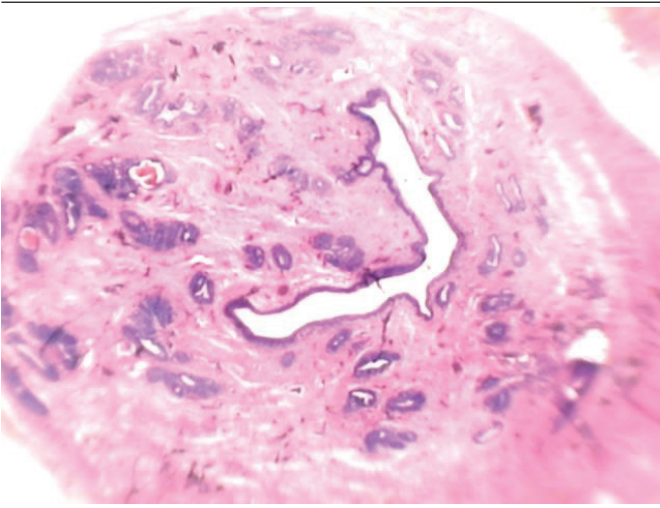


FIGURE 1 – Histological panoramic view of prostate tissue

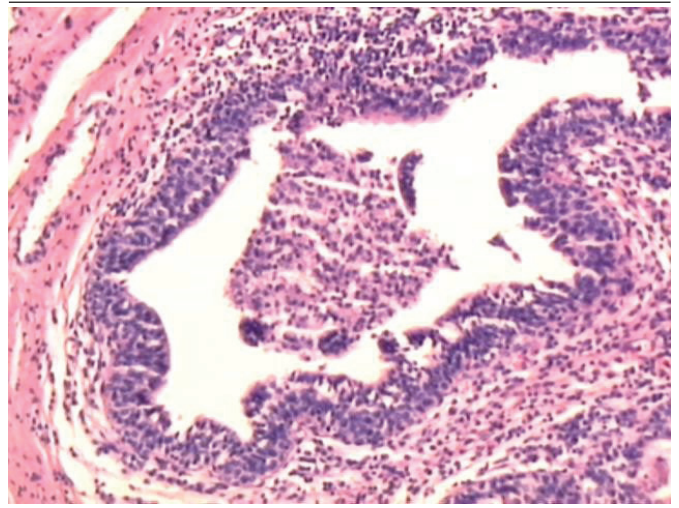


FIGURE 4 – Distal urethral portion. Inflammation surrounding the glands. Magnification: 40x

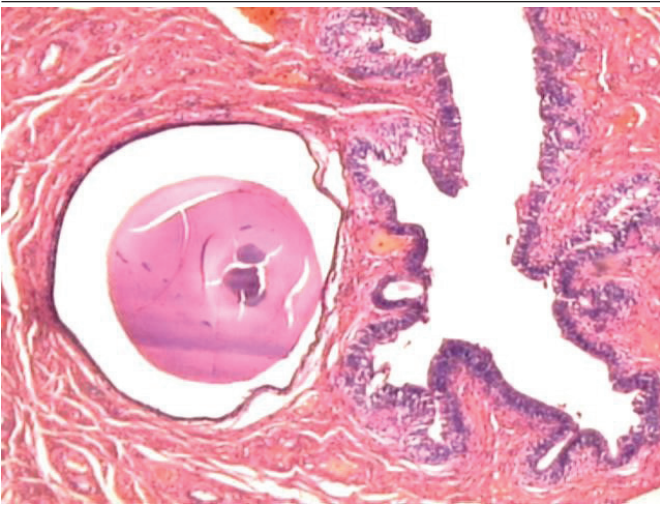


FIGURE 2 – Glands and cystic structures surrounding the urethra. Magnification: 40x

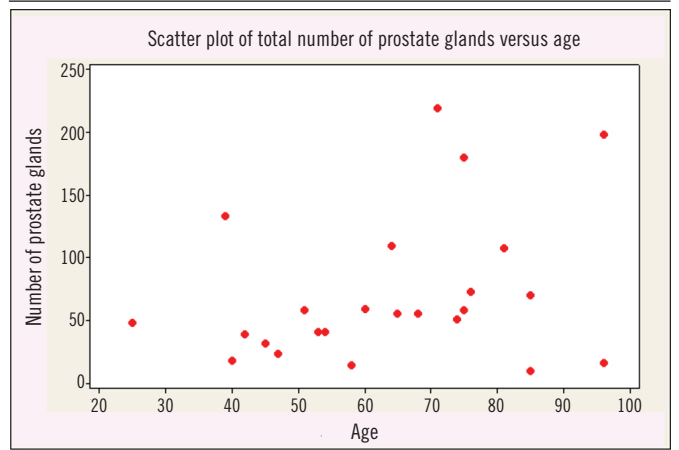


FIGURE 5 – Correlation between number of prostate glands and age

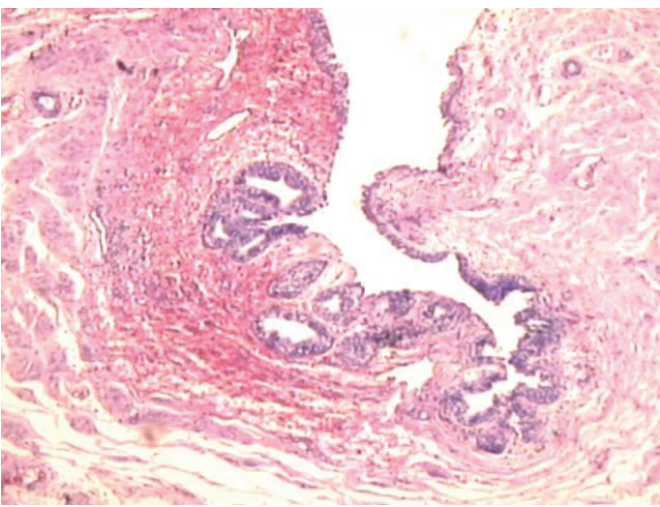


FIGURE 3 – Median urethral portion. Presence of surrounding bleeding. Magnification: 40x

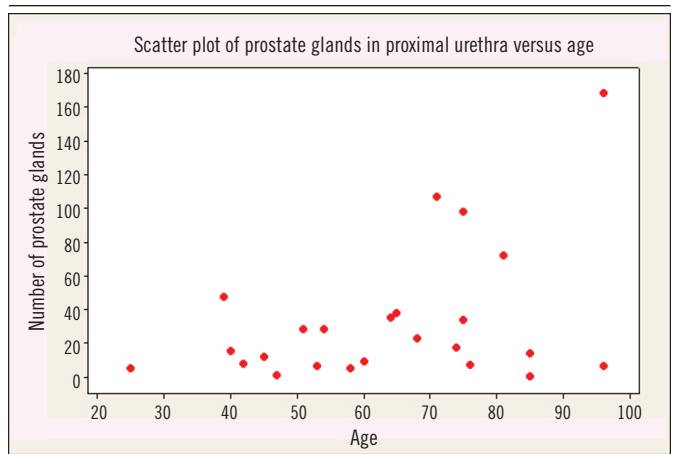


FIGURE 6 – Correlation between prostate glands in the proximal urethral portion and age

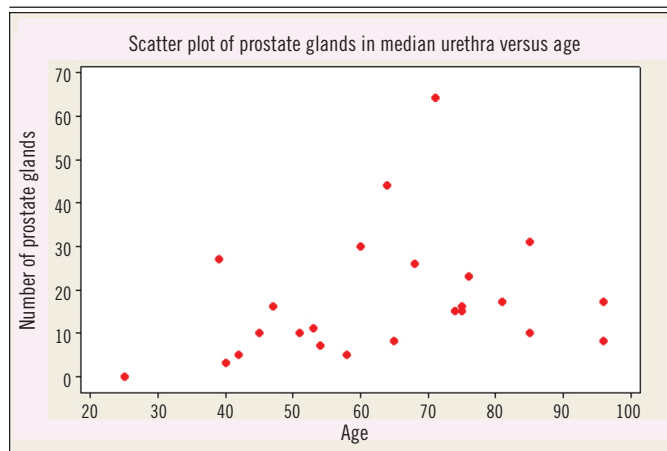


FIGURE 7 – Correlation between prostate glands in the median urethral portion and age

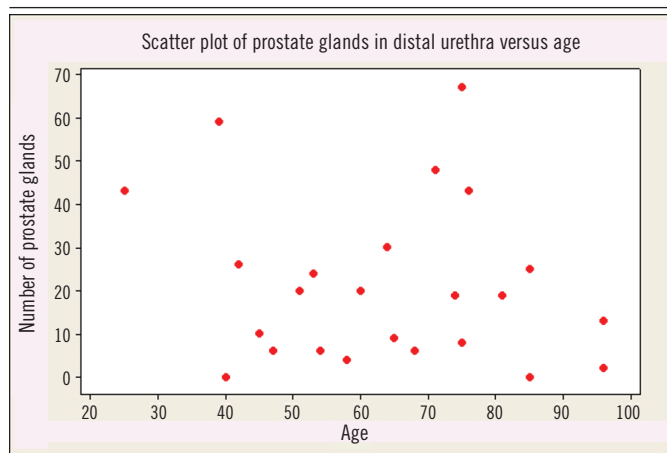


FIGURE 8 – Correlation between prostate glands in the distal urethral portion and age

identified, and is also formed by prostate tissue in the entire urethra (6% of cases).

No macroscopic prostate was visualized in this study. According to Zaviačič (1998)⁽¹⁾, the female prostate size and weight corresponds to the entire female urethra and prostate combined, with an average size of $3.3 \times 1.9 \times 1$ cm, and an average weight of 5.2 g. No size data were obtained in the present study. This study found nine cases of glands containing some cystic structures.

Very few studies in female prostate have been published. Wimpissinger *et al.* (2009)⁽¹⁶⁾ used endoscopy and nuclear magnetic resonance to evaluate seven women who had shown signs and symptoms of prostate problems such as ejaculation and chronic urethral pain. However, no histological study has been carried out.

Custodio *et al.* (2008)⁽⁶⁾ studied the effect of aging on gerbil prostate and reported that reduced levels of dehydroepiandrosterone and estradiol during senescence led to epithelial hypertrophy, metaplasia, neoplasia, and hyperplasia.

CONCLUSION

The number of prostate glands increases after menopause, with proliferative growth and spread from the median to proximal and distal urethra. These results suggest that a reduction in hormone levels can stimulate increase of the female prostate gland and induce further disorders in the woman. This study did characterize the paraurethral glands in women; however, due to the small number of patients studied, this data should be replicated in another cohort.

RESUMO

Introdução: A próstata é uma glândula com papel importante no sistema reprodutor masculino e feminino. Dados sobre esse órgão não foram completamente explorados em mulheres desde a sua primeira descrição, provavelmente por ser considerada uma glândula vestigial. **Objetivo:** Correlacionar a morfologia da próstata feminina com a idade em autópsias. **Material e métodos:** Trinta e dois cadáveres do sexo feminino, sendo 31 adultos e um recém-nascido, tiveram sua região correspondente à próstata dissecada e avaliada por meio de histologia. A região uretral foi dividida em três partes: anterior, mediana e distal. As glândulas presentes nas amostras foram contadas. Dados clínicos foram coletados, incluindo idade e diagnóstico prévio de menopausa. **Resultados:** Não foram observadas próstatas macroscopicamente. Análises morfológicas mostraram glândulas ao redor da uretra com epitélio estratificado, variando do tipo escamoso a colunar, com predomínio de células basófilas e algumas apresentando secreção em seu interior. Correlação significativa com tecido prostático foi detectada entre a uretra mediana e a proximal, assim como entre as uretras mediana e distal, sugerindo que quando as estruturas glandulares aumentam na região mediana, há também aumento nas estruturas anterior e distal. Além disso, o predomínio das glândulas na uretra mediana foi observado em mulheres pós-menopausa. **Conclusão:** Este estudo sugere que o número de glândulas prostáticas femininas aumenta após a menopausa, com disseminação e crescimento da região mediana para a proximal e distal.

Unitermos: próstata; mulheres; menopausa.

REFERENCES

1. Zaviačič M, Sloboda, Jakubovský J, et al. Metastasizing adenocarcinoma of the female prostate (Skene's paraurethral glands). Histological and immunohistochemical prostate marker studies and first ultrastructural observation. *Pathol Res Pract*. 1998; 194: 129-36.
2. Santos FCA, Carvalho HF, Góes RM, et al. Structure, histochemistry, and ultrastructure of epithelium and stroma in the gerbil (*Meriones unguiculatus*) female prostate. *Tissue Cell*. 2003; 35: 447-57.
3. Santos FCA, Leite RP, Custódio AMG, et al. Testosterone stimulates growth and secretory activity of the female prostate in the adult gerbil (*Meriones unguiculatus*). *Biol Reprod*. 2006; 75: 370-9.
4. Santos FCA, Custodio AMG, Campos SGP, et al. Antiestrogen therapies affect tissue homeostasis of the gerbil (*Meriones unguiculatus*) female prostate and ovaries. *Biol Reprod*. 2008; 79: 674-85.
5. Custodio AMG, Góes RM, Taboga SR. Acid phosphatase activity in gerbil prostate: comparative study in male and female during postnatal development. *Cell Biol Int*. 2004; 28: 335-44.
6. Custodio AMG, Santo FCA, Campos SGP, et al. Aging effects on the Mongolian gerbil female prostate (Skene's paraurethral glands): structural, ultrastructural, quantitative, and hormonal evaluations. *Anat Rec*. 2008; 291: 463-74.
7. Santos FCA, Taboga SR. Female prostate: a review about the biological repercussions of this gland in humans and rodents. *Anim Reprod*. 2006; 3: 3-18.
8. Perez AP, Biancardi MF, Goes RM, et al. Exposure to ethinylestradiol during prenatal development and postnatal supplementation with testosterone causes morphophysiological alterations in the prostate of male and female adult gerbils. *Int. J. Exp. Pathol*. 2011; 92: 121-30.
9. Zaviačič MZ, Zaviačić M, Ablin RJ. The female prostate and prostate-specific antigen. Immunohistochemical localization, implications of this prostate marker in women and reasons for using the term "prostate" in the human female. *Histol Histopathol*. 2000 Jan; 15(1): 131-42.
10. Schubach G. The G-spot is the female prostate. *Am J Obstet Gynecol*. 2002 Apr; 186(4): 850.
11. Hines TM. The G-spot: a modern gynecologic myth. *Am J Obstet Gynecol*. 2001 Aug; 185(2): 359-62.
12. Dodson MK, Cliby WA, Keeney GL, et al. Skene's gland adenocarcinoma with increased serum level of prostate-specific antigen. *Gynecol Oncol*. 1994; 55: 304-7.
13. Dodson MK, Cliby WA, Pettavel PP, et al. Female urethral adenocarcinoma: evidence for more than one tissue of origin? *Gynecol Oncol*. 1995; 59: 352-7.
14. Ali SZ, Smilari TF, Gal D, et al. Primary adenoid cystic carcinoma of Skene's glands. *Gynecol Oncol*. 1995; 57: 257-61.
15. McCluggage WG, Ganesan R, Hirschowitz L, et al. Ectopic prostatic tissue in the uterine cervix and vagina: report of a series with a detailed immunohistochemical analysis. *Am J Surg Pathol*. 2006 Feb; 30(2): 209-15.
16. Wimpissinger F, Tscherny R, Stackl W. Magnetic resonance imaging of female prostate pathology. *J Sex Med* 2009; 6: 1704-11.

CORRESPONDING AUTHOR

Thalita Cristina de Mello Costa

Faculdade de Medicina de São José do Rio Preto, Avenida Brigadeiro Faria Lima, 5.544; Vila São Jorge; CEP: 15090-000; São José do Rio Preto-SP, Brasil; e-mail: thalitamcosta@hotmail.com.