



Idiopathic pulmonary fibrosis can be a transient diagnosis

Martina Rodrigues de Oliveira¹, Daniel Antunes Silva Pereira¹,
Olívia Meira Dias¹, Ronaldo Adib Kairalla¹, Carlos Roberto Ribeiro Carvalho¹,
Bruno Guedes Baldi¹

TO THE EDITOR:

Usual interstitial pneumonia (UIP) can be accompanied by various clinical conditions, probably the most important of which is idiopathic pulmonary fibrosis (IPF), although the exact incidence and prevalence of IPF, in Brazil or elsewhere, remains unknown.⁽¹⁻³⁾ The diagnosis of IPF can be established only after the exclusion of other diseases potentially associated with the UIP pattern, such as chronic hypersensitivity pneumonitis, connective tissue diseases, especially rheumatoid arthritis, drug toxicity, and asbestosis.^(1,2,4,5) The association between antineutrophil cytoplasmic antibody (ANCA)-positive vasculitis and interstitial lung disease (ILD) has recently been described, including another possible etiology for the UIP pattern. Here, we report the case of a patient with an initial diagnosis of IPF who later developed ANCA-positive vasculitis.

A 62-year-old nonsmoking male patient, a bricklayer, presented with a one-year history of dry cough and slowly progressive dyspnea, classified as grade 2 on the modified Medical Research Council scale. He was being treated with omeprazole, bromopride, and simvastatin for gastroesophageal reflux disease and dyslipidemia. Pulmonary auscultation revealed crackles at both lung bases, and the SpO₂ was 97% on room air. The findings of an HRCT scan of the chest (Figure 1) were consistent with a UIP pattern. Pulmonary function tests revealed a mild restrictive pattern (FVC, 78% of predicted/3.6 L; FEV₁, 81% of predicted/2.8 L; FEV₁/FVC ratio, 0.78; and total lung capacity, 75% of predicted/5.25 L) with normal DLCO (92% of predicted/27.6 mL/min/mmHg). During a six-minute walk test, there was no desaturation (minimum SpO₂, 96%), and the six-minute walk distance was 548 m.

The results of laboratory tests were normal, and autoantibody tests were negative, including tests for rheumatoid factor, antinuclear antibodies, anti-Jo-1, anti-Scl-70, and ANCA. The findings of a transthoracic echocardiogram were also normal. A surgical lung biopsy performed at another institution was reviewed and was found to show the UIP histopathological pattern, confirming the diagnosis of IPF. At that time, the patient was still under treatment for gastroesophageal reflux disease.

After one year of clinical stability, the patient was admitted to the hospital with a one-month history of daily fever (38°C) and hematuria, together with swelling and purple lesions in the lower limbs. Laboratory tests revealed anemia (hemoglobin, 9.5 g/dL), elevated C-reactive protein (155 mg/L; reference range, < 5 mg/L) and elevated creatinine (4.5 mg/dL; estimated

creatinine clearance, 14 mL/min). Urinalysis showed hematuria, proteinuria, and leukocyturia. There were also a mild reduction in complement C3 (86 mg/dL; reference range, 90-180 mg/dL) and C4 (9.6 mg/dL, reference range, 10-40 mg/dL), as well as positivity for myeloperoxidase-ANCA (1/320), antinuclear antibodies (1/320, with fine-speckled nuclear staining pattern), and rheumatoid factor (97 IU/mL).

A new kidney biopsy was performed, and the analysis of the biopsy sample confirmed the diagnosis of pauci-immune crescentic glomerulonephritis associated with microscopic polyangiitis (MPA), and a skin biopsy of the lower limbs showed leukocytoclastic vasculitis. Methylprednisolone pulse therapy was administered at 1 g/day for three days, after which the patient was started on prednisone at a dose of 1 mg/day that was gradually tapered thereafter. Subsequent treatment with mycophenolate (1.5 g/day) produced gradual clinical improvement. After two years of treatment, the patient continued to have mild dyspnea (modified Medical Research Council scale grade 1), to show normal kidney function, and to test negative for ANCA, and well as to have stable HRCT and pulmonary function test findings.

In patients with ANCA-positive vasculitis, particularly MPA, ILD is an uncommon finding and usually affects older men, with myeloperoxidase-ANCA and a UIP pattern on histopathology. However, the pathophysiology of the association of ILD and ANCA-positive vasculitis has not been fully elucidated.⁽⁶⁾

Recent studies have demonstrated that there is a subset of IPF patients who are ANCA-positive at diagnosis or who convert to ANCA positivity during follow-up and subsequently develop MPA.^(6,7) Kagiya et al.⁽⁷⁾ evaluated ANCA positivity and the incidence of MPA in 504 patients with IPF. The authors found that 36 (7%) of the patients were ANCA-positive at diagnosis of IPF. Of the 264 patients who were subsequently tested, 29 (11%) converted to ANCA positivity during the first five years of follow-up. Of the 35 patients who were either ANCA-positive at diagnosis or subsequently converted to ANCA positivity, 9 were diagnosed with MPA.

Two drugs, nintedanib and pirfenidone, both of which slow the decline in lung function, were recently approved for the treatment of IPF.^(8,9) However, to date, there is no recommendation regarding the use of those drugs in patients with ILD associated with ANCA-positive vasculitis, in whom it has been suggested that the use of corticosteroids plus cyclophosphamide or rituximab is a

1. Divisão de Pneumologia, Instituto do Coração – InCor – Hospital das Clínicas, Faculdade de Medicina, Universidade de São Paulo, São Paulo (SP) Brasil.

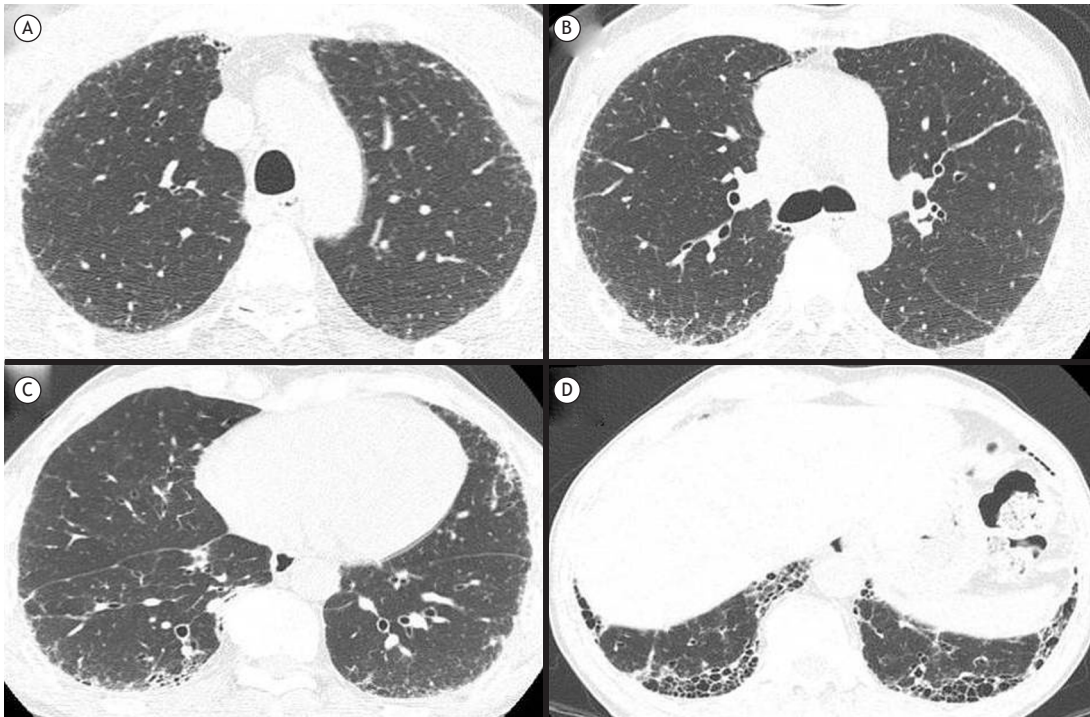


Figure 1. Chest HRCT scans showing findings consistent with the pattern of usual interstitial pneumonia: A) discrete subpleural reticular opacities in the upper lobes; B) subpleural reticular opacities and discrete areas of ground-glass abnormalities at the level of the carina; C) peripheral reticular opacities, traction bronchiolectasis, and discrete areas of ground-glass abnormalities predominantly in the lower lobes; and D) peripheral honeycombing and traction bronchiolectasis in the lower lobes.

better approach.⁽⁶⁾ The combination of mycophenolate and corticosteroids can also be considered.

The prognosis of patients with ILD associated with ANCA-positive vasculitis has not been fully established. In a study of 49 such patients (82% with MPA), mortality was 34% in the first 60 months after the diagnosis. In a review of 65 patients (85% with a UIP pattern) that were followed for 45 months, 35% showed progression of ILD and the remaining 65% showed stability or improvement,⁽⁶⁾ which suggests that the prognosis of ILD associated with ANCA-positive vasculitis is better than is that of IPF.⁽⁶⁾

In conclusion, this report underscores the potential for the occurrence of ILD, including a UIP pattern, in patients with ANCA-positive vasculitis. In that form of vasculitis, interstitial lung involvement can precede systemic manifestations and patients can be initially diagnosed with IPF. We emphasize the importance of an extensive etiological investigation of patients who show a UIP pattern, especially of those in whom the disease has an indolent course. The diagnosis of a secondary cause could facilitate the definition of the best therapeutic strategy and the determination of the prognosis in such patients.

REFERENCES

- Raghu G, Collard HR, Egan JJ, Martinez FJ, Behr J, Brown KK, et al. An official ATS/ERS/JRS/ALAT statement: idiopathic pulmonary fibrosis: evidence-based guidelines for diagnosis and management. *Am J Respir Crit Care Med.* 2011;183(6):788-824. <http://dx.doi.org/10.1164/rccm.2009-040GL>
- Baddini-Martinez J, Baldi BG, Costa CH, Jezler S, Lima MS, Rufino R. Update on diagnosis and treatment of idiopathic pulmonary fibrosis. *J Bras Pneumol.* 2015;41(5):454-66. <http://dx.doi.org/10.1590/S1806-37132015000000152>
- Baddini-Martinez J, Pereira CA. How many patients with idiopathic pulmonary fibrosis are there in Brazil? *J Bras Pneumol.* 2015;41(6):560-1. <http://dx.doi.org/10.1590/S1806-37562015000000165>
- Wuyts WA, Cavazza A, Rossi G, Sverzellati N, Spagnolo P. Differential diagnosis of usual interstitial pneumonia: when is it truly idiopathic? *Eur Respir Rev.* 2014;23(133):308-19. <http://dx.doi.org/10.1183/09059180.00004914>
- Smith M, Dalurzo M, Panse P, Parish J, Leslie K. Usual interstitial pneumonia-pattern fibrosis in surgical lung biopsies. Clinical, radiological and histopathological clues to aetiology. *J Clin Pathol.* 2013;66(10):896-903. <http://dx.doi.org/10.1136/jclinpath-2013-201442>
- Comarmond C, Crestani B, Tazi A, Hervier B, Adam-Marchand S, Nunes H, et al. Pulmonary fibrosis in antineutrophil cytoplasmic antibodies (ANCA)-associated vasculitis. *Medicine (Baltimore).* 2014;93(24):340-9. <http://dx.doi.org/10.1097/MD.0000000000000217>
- Kagiyama N, Takayanagi N, Kanauchi T, Ishiguro T, Yanagisawa T, Sugita Y. Antineutrophil cytoplasmic antibody-positive conversion and microscopic polyangiitis development in patients with idiopathic pulmonary fibrosis. *BMJ Open Respir Res.* 2015;2(1):e000058. <http://dx.doi.org/10.1136/bmjresp-2014-000058>
- King TE Jr, Bradford WZ, Castro-Bernardini S, Fagan EA, Glasspole I, Glassberg MK, et al. A phase 3 trial of pirfenidone in patients with idiopathic pulmonary fibrosis. *N Engl J Med.* 2014;370(22):2083-92. <http://dx.doi.org/10.1056/NEJMoa1402582>
- Richeldi L, du Bois RM, Raghu G, Azuma A, Brown KK, Costabel U, et al. Efficacy and Safety of nintedanib in idiopathic pulmonary fibrosis. *N Engl J Med.* 2014;370(22):2071-82. <http://dx.doi.org/10.1056/NEJMoa1402584>