

Endovascular management of massive pulmonary embolism with clot fragmentation and suction

Tratamento endovascular de embolia pulmonar maciça com fragmentação e aspiração de trombos

Sergio Quilici Belczak¹, Igor Rafael Sincos², Ricardo Aun³, Alex Lederman⁴,
Boulanger Mito Neto⁴, Fernando Saliture⁵, Manoel Lobato⁴

Abstract

Massive pulmonary embolism with right ventricular dysfunction may be treated with thrombolysis, embolectomy, or percutaneous mechanical thrombectomy. This study describes our experience with two patients that had massive pulmonary embolism and were treated with percutaneous mechanical thrombectomy and reports on the mid-term results of this procedure. A 28-year-old man and a 70-year-old woman were diagnosed with deep venous thrombosis and massive pulmonary embolism. They first had lower limb edema followed by sudden onset of dyspnea. Their physical examination revealed edema, tachypnea, chest discomfort and jugular turgescence. Both needed to receive oxygen using a nasal cannula. Doppler ultrasound, echocardiography, and computed tomography angiography were used to establish the diagnoses. Patients underwent percutaneous mechanical thrombectomy using the Aspirex® system (Straub Medical), and their clinical condition and imaging study findings improved substantially. At mid-term follow-up, patient conditions were improving satisfactorily.

Keywords: pulmonary embolism; endovascular procedures; thrombectomy.

Resumo

A embolia pulmonar maciça com disfunção do ventrículo direito pode ser tratada com trombólise, embolectomia ou trombectomia mecânica percutânea. Este estudo descreve nossa experiência com dois pacientes com embolia pulmonar maciça tratados com trombectomia mecânica percutânea e relata os resultados a médio prazo desse procedimento. Um homem de 28 anos e uma mulher de 70 anos foram diagnosticados com trombose venosa profunda e embolia pulmonar maciça. Inicialmente, eles tiveram edema de membros inferiores seguido por início súbito de dispnéia. O exame físico revelou edema, taquipnéia, desconforto torácico, turgência jugular. Em ambos havia sinais de hipóxia e precisaram receber oxigênio usando uma cânula nasal. A ultrassonografia Doppler ecocardiograma e angiotomografia foram utilizadas para estabelecer os diagnósticos. Os pacientes foram submetidos à trombectomia mecânica percutânea utilizando o sistema Aspirex® (Straub Medical). Sua condição clínica e os achados dos estudos de imagem melhoraram substancialmente. No acompanhamento a médio prazo, os pacientes apresentaram melhora significativa do quadro.

Palavras-chave: embolia pulmonar; procedimentos endovasculares; trombectomia.

¹ Universidade de São Paulo - USP, Faculdade São Camilo, Hospital of Carapicuíba, Carapicuíba, SP, Brazil.

² Faculdade São Camilo, Hospital of Carapicuíba, Carapicuíba, SP, Brazil.

³ Universidade de São Paulo - USP, Hospital Israelita Albert Einstein, São Paulo, SP, Brazil.

⁴ Hospital Israelita Albert Einstein, Medical School of Universidade de São Paulo - USP, São Paulo, SP, Brazil.

⁵ Hospital Israelita Albert Einstein, Medical School of Santa Casa de Misericórdia de São Paulo, São Paulo, SP, Brazil.

Financial support: None.

Conflict of interest: No conflicts of interest declared concerning the publication of this article.

Submitted on: 29.08.11. Accepted on: 14.11.12.

Study carried out at the Hospital Israelita Albert Einstein – São Paulo (SP), Brasil.

INTRODUCTION

Massive pulmonary embolism (MPE) is characterized by sudden onset of dyspnea, chest discomfort or syncope, and clinical deterioration toward cardiovascular collapse¹. The clinical picture usually progresses with systemic arterial hypotension, respiratory failure, and impaired organ perfusion². MPE is associated with high morbidity and early mortality rates, especially during hospitalization, and accounts for about 15% of the deaths of hospitalized patients³.

MPE in patients with right ventricular dysfunction (RVD) and hemodynamic instability may determine a worse prognosis⁴. The therapeutic goals for this group of patients are basically the reestablishment of patency of pulmonary circulation and the prevention of further deterioration of right ventricular function.

Thrombolysis, embolectomy, or percutaneous mechanical thrombectomy (PMT) are treatment options for these patients. Recently, Eid-Lidt et al.⁵ advocated the use of PMT for patients with MPE, RVD, and major contraindications to thrombolytic therapy, increased bleeding risk, failed thrombolysis, or unavailable surgical thrombectomy.

This study describes the treatment of two patients with MPE using PMT and their condition at four and six months of follow-up.

CASE DESCRIPTION

Case 1

A 28-year-old man was injured during sports practice. His left lower limb was immobilized due to contusion, after which he experienced a sudden onset of intense dyspnea. The physical examination revealed edema and important muscle tenderness. The patient was dependent on oxygen via a nasal cannula. Left iliofemoral deep venous thrombosis and MPE were diagnosed using Doppler ultrasound and computed tomography angiography (CTA) (Figure 1a-c). An echocardiogram showed moderate reduction of right ventricular performance and peak pulmonary systolic pressure estimated at 47 mmHg. The patient underwent PMT using the Aspirex[®] system (Straub Medical, Wangs, Switzerland), and intraoperative control angiograms confirmed the presence of clots in the pulmonary arteries (Figure 1d). Postoperative CTA control scans showed a substantial reduction of pulmonary clots (Figure 1e-f). The patient had immediate clinical improvement, and exams confirmed absence of deficits in right ventricular performance. A control echocardiogram showed a peak pulmonary systolic pressure estimated at 25 mmHg. The patient was discharged on anticoagulation therapy (Warfarin). Four months later, he had no symptoms. Screening

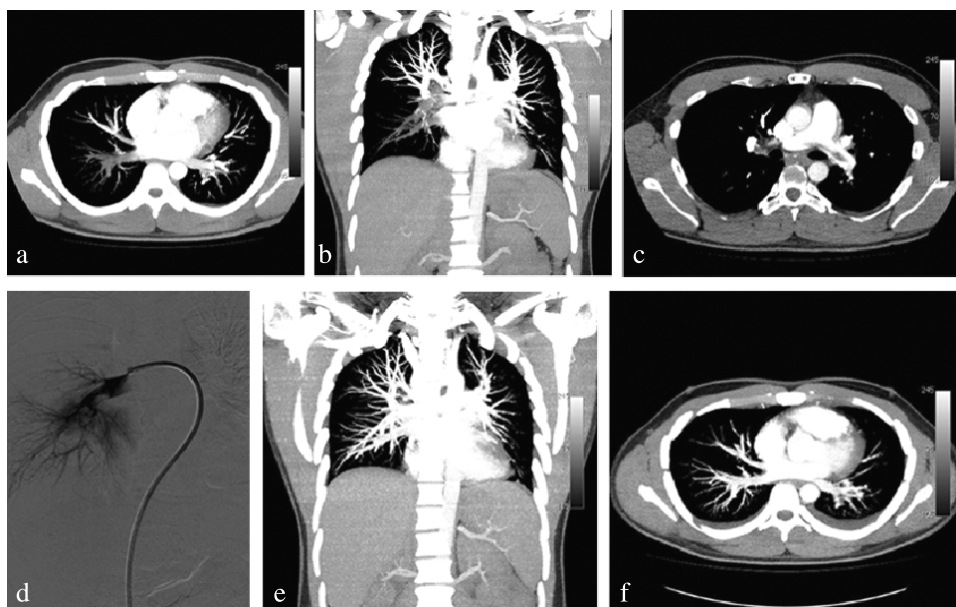


Figure 1. Computed tomography angiography scans (a, b, c) show bilateral massive pulmonary embolism. Arteriogram (d) shows pulmonary clot, and computed tomography angiography control scans (e, f) confirm reduction of clots in pulmonary circulation.

for thrombophilia (deficiencies of antithrombin, protein C and protein S, factor V Leiden, prothrombin gene mutation, lupus anticoagulant, anticardiolipin antibodies, homocysteine, lipoprotein A) was negative.

Case 2

A 70-year-old woman had an ischemic stroke that resulted in motor deficit in the right side. She also had right iliofemoral deep venous thrombosis, which was treated with anticoagulation therapy. Three months later, the patient was seen in the Emergency Room due to sudden dyspnea and intense chest discomfort. Chest CTA (Figure 2a) and Doppler ultrasound of the lower limb revealed the extension of the deep venous thrombosis to the site of the previous injury and MPE. An echocardiogram revealed severely reduced right ventricular performance and peak pulmonary systolic pressure estimated at 42 mmHg. Her clinical condition deteriorated toward dyspnea and discomfort; she was receiving oxygen via a nasal cannula, and saturation was 90%. The patient underwent PMT using the Aspirex® system (Figure 2b-c). Postoperative control angiograms showed a substantial reduction of the clots in the pulmonary arteries. Then, a vena cava filter (Tulip, COOK®) was placed in the infrarenal position to prevent future events (Figure 2d). Control CTA scans revealed a substantial reduction of the clots in the pulmonary artery (Figure 2e). A control echocardiogram showed a mild reduction of right ventricular performance and peak pulmonary systolic pressure estimated at 29 mmHg. Immediate improvement of the

respiratory status was referred by the patient, who was discharged from the hospital four days later. She has been receiving anticoagulation treatment for six months in outpatient follow-up, and her screening for thrombophilia (just as described for Case 1) was negative.

DISCUSSION

The management of RVD secondary to MPE is still not consensual, and the use of thrombolytic therapy in patients with RVD without hypotension is controversial⁴. Management should be more aggressive to restore the patency of pulmonary circulation and to avoid both the deterioration of cardiac function and the progression to cardiogenic shock^{1,6}.

PMT has been developed in the last years as a treatment option for the management of such patients. A device is introduced into the pulmonary circulation for the fragmentation, suction and removal of clots. The basic goals of the different PMT techniques are to eliminate or break the central clots so that they migrate to more distal pulmonary branches, relieve the obstruction of the main pulmonary circulation and reduce the right ventricular pressure overload.

For thrombectomy, we have chosen the catheter Aspirex® (Straub Medical; Wangs, Switzerland). It was designed to remove obstructing thrombus from large vessels; its central part is a high-speed rotational coil that macerates and removes thrombus through aspiration ports at the catheter tip. This combination of clot fragmentation and thrombectomy with the Aspirex® device was associated with an improvement

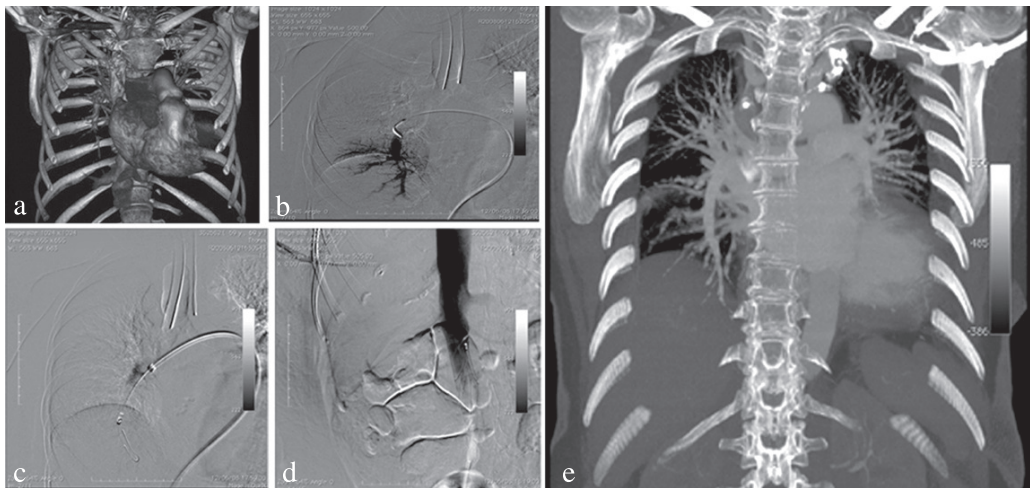


Figure 2. Computed tomography angiography reconstruction (a) and intraoperative arteriogram (b) show one of clots in pulmonary circulation, as well as device placed in pulmonary artery (c) and vena cava filter implanted in infrarenal position (d). Computed tomography angiography scan (e) shows right pulmonary circulation without clots.

in the pulmonary occlusion rate, oxygen saturation, pulmonary artery pressure and, most importantly, a significant increase in systemic arterial pressure¹.

As the technique has been refined, some studies have reported rates of about 90% of success, represented by improvement of the symptoms and echocardiography parameters, as well as good mid-term evolution⁵, as in the two cases reported here. Skaf et al.⁷ failed to demonstrate immediate improvement in systemic arterial pressure after mechanical catheter intervention without administration of fibrinolysis. However, the two cases reported here are in agreement with the conclusions made by Eid-Lidt et al.⁵, who suggested that PMT may be a useful alternative for the management of patients with MPE, RVD, and major contraindications to thrombolytic therapy, increased bleeding risk, failed thrombolysis or unavailable surgical thrombectomy. We also had no procedural complications, despite the potential risk of fatal events associated with any pulmonary catheter interventions, such as pulmonary hemorrhage and peritoneal tamponade¹.

Percutaneous mechanical fragmentation and suction is currently the only promising therapeutic alternative to thrombolysis or surgical embolectomy for patients with MPE and high risk of death from right ventricular failure, although further studies are necessary to define its role in the treatment of cases that are very challenging to the vascular surgeon.

REFERENCES

1. Kucher N, Goldhaber SZ. Mechanical catheter intervention in massive pulmonary embolism: proof of concept. *Chest*. 2008;134(1):2-4. PMID:18628212.
2. Kucher N, Rossi E, De Rosa M, Goldhaber SZ. Massive pulmonary embolism. *Circulation*. 2006;113(4):577-82.
3. Pulido T, Aranda A, Zevallos MA, et al. Pulmonary embolism as a cause of death in patients with heart disease: an autopsy study. *Chest*. 2006;129(5):1282-7. PMID:16685020.
4. Wood KE. Major pulmonary embolism: review of a pathophysiologic approach to the golden hour of hemodynamically significant pulmonary embolism. *Chest*. 2002;121(3):877-905. PMID:11888976.
5. Eid-Lidt G, Gaspar J, Sandoval J, et al. Combined clot fragmentation and aspiration in patients with acute pulmonary embolism. *Chest*. 2008;134(1):54-60. PMID:18198243.
6. Góes Junior AMO, Mascarenhas F, Mourão GS, Elkis H, Pieruccetti MA. Tratamento de tromboembolismo pulmonar por aspiração percutânea do trombo – relato de caso. *J Vasc. Bras*. 2010;9(3):190-5. <http://dx.doi.org/10.1590/S1677-54492010000300018>
7. Skaf E, Beemath A, Siddiqui T, Janjua M, Patel NR, Stein PD. Catheter-tip embolectomy in the management of acute massive pulmonary embolism. *Am J Cardiol*. 2007;99(1):415-20. PMID:17261410.

Correspondence

Sergio Quilici Belczak
Rua Sabará, 47 – Higienópolis
CEP 04515-030 – São Paulo (SP), Brazil
Fone: 55 (11) 3257-7784
E-mail: belczak@gmail.com

Author information

SQB PhD, School of Medicine, Universidade de São Paulo (USP). Full professor of Vascular Surgery, Faculdade São Camilo. Head, Vascular Surgery Service, Hospital Geral de Carapicuíba.
IRS Full professor of Vascular Surgery, Faculdade São Camilo. Head, Vascular Surgery Service, Hospital Geral de Carapicuíba.
RA Professor of Vascular Surgery, Scholl of Medicine, Universidade de São Paulo (USP). Head, Vascular and Endovascular Surgery Service (Prof. Dr. Ricardo Aun), Hospital Israelita Albert Einstein.
AL, BMN, ML assistant physician, Vascular and Endovascular Surgery Service (Prof. Dr. Ricardo Aun), Hospital Israelita Albert Einstein. Former resident physician (vascular and endovascular surgery), School of Medicine, Universidade de São Paulo (USP).
FS assistant physician, Vascular and Endovascular Surgery Service (Prof. Dr. Ricardo Aun), Hospital Israelita Albert Einstein. Former resident physician (vascular and endovascular surgery), School of Medicine, Santa Casa de Misericórdia de São Paulo.

Author's contributions

Conception and design: SQB
Analysis and interpretation: IRS, FS
Data collection: RA, SQB
Writing the article: RA, SQB
Critical revision of the article: BM, AL, ML
Final approval of the article*: BM, AL, ML, RA, SQB, IRS, FS
Statistical analysis: N/A
Overall responsibility: RA, SQB

*All authors have read and approved the final version submitted to J Vasc Bras.