

## Diagnosis and treatment of persistent sciatic artery aneurysm: case report and review of the literature

Marco Antonio Prado Nunes<sup>I</sup>, Roberto Maurício Ferreira Ribeiro<sup>II</sup>, José Aderval Aragão<sup>III</sup>, Francisco Prado Reis<sup>IV</sup>, Vera Lúcia Correa Feitosa<sup>V</sup>

<sup>I</sup>Assistant professor, Universidade Tiradentes (UNIT), Aracaju, SE, Brazil.

<sup>II</sup>Angiologist, Hospital de Urgência de Sergipe João Alves Filho, Aracaju, SE, Brazil.

<sup>III</sup>Assistant professor, UNIT, Aracaju, SE, Brazil. Assistant professor, Universidade Federal de Sergipe (UFS), Aracaju, SE, Brazil.

<sup>IV</sup>Professor, UNIT, Aracaju, SE, Brazil.

<sup>V</sup>Assistant professor, UFS, Aracaju, SE, Brazil.

### Correspondence

J Vasc Bras. 2008; 7(1):66-71.

---

### ABSTRACT

Persistent sciatic artery is a rare anatomical variation whose clinical course is potentially serious, since diagnosis is performed when clinical complications are already present. Such complications are a consequence of the fact that sciatic artery walls have a tendency to atherosclerotic degeneration with aneurysmal formation and may evolve to occlusive thrombosis or to thromboembolism. This article reports the case of a female patient with complaint of intense pain secondary to extrinsic compression of the sciatic nerve by aneurysmal dilatation of the right lower member and hyperpulsatile ipsilateral buttock. Angiographic examination was carried through, showing complete persistent sciatic artery to the right lower member with an aneurysm. The patient was submitted to a surgical procedure using a transgluteal approach and a termino-terminal Dacron graft was interposed between the proximal and distal necks of the aneurysm. The technical aspects and review of literature on diagnosis and therapeutic approach of this anatomical variation are discussed in this work.

Keywords: Persistent sciatic artery, sciatic artery aneurysm, surgical correction, peripheral ischemia.

---

### RESUMO

A persistência da artéria isquiática é uma variação anatômica rara cujo curso clínico é potencialmente grave, pois o diagnóstico ocorre quando já estão presentes complicações clínicas. Essas complicações advêm do fato de a parede da artéria isquiática ter uma tendência à degeneração aterosomatosa com formação aneurismática, podendo evoluir para uma oclusão ou para um tromboembolismo. Este artigo relata o caso de um paciente do sexo feminino, com queixas de dor intensa secundária a compressão extrínseca do nervo isquiático pela dilatação aneurismática no membro inferior direito e pulsatilidade na nádega ipsilateral, apresentando uma massa hiperpulsátil nessa localização. Foi realizado exame angiográfico, que revelou persistência da artéria isquiática à direita, do tipo completo e com aneurisma. A paciente foi submetida a procedimento cirúrgico, sendo utilizada uma abordagem transglútea, e uma prótese de dácron terminoterminal foi interposta entre os colos proximal e distal do aneurisma. Os aspectos técnicos e revisão da literatura sobre o diagnóstico e a terapêutica dessa variação anatômica são discutidos neste trabalho.

Palavras-chave: Persistência da artéria isquiática, aneurisma da artéria isquiática, terapêutica cirúrgica, isquemia periférica.

---

## Introduction

Sciatic artery is an axial artery embryologically responsible for the blood supply of lower limbs. Under normal conditions, around the third month of embryonic life, it regresses to form the proximal segment of the inferior gluteal artery. This occurs after the development of the femoral artery from the external iliac artery.<sup>1</sup>

In case of persistent sciatic artery, the superficial femoral artery undergoes a process of atresia in the distal thigh, and is usually interrupted at the adductor hiatus level, entering the leg as posterior tibial artery. The femoral artery is occasionally very short and ends as the common deep circumflex trunk.<sup>2</sup> Persistent sciatic artery is a rare anatomic variation and tends to formation of aneurysm, atherosclerosis or distal embolization.<sup>3</sup>

Ikezawa et al.<sup>4</sup> performed a review of the available literature and reported occurrence of 168 cases. Persistent sciatic artery is potentially severe, since it has a primitive vascular trunk that plays the role of the main supply vessel for the whole lower limb.<sup>2</sup> On the other hand, diagnosis usually occurs when clinical complications are already present. Such complications result from the fact that sciatic artery wall tends to atheromatous degeneration with aneurysmal formation, and may progress to occlusion or thromboembolism.<sup>3</sup>

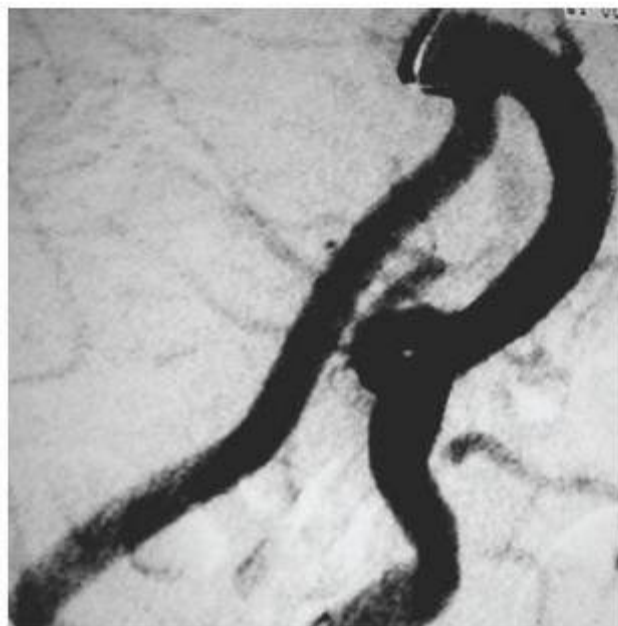Early detection of persistent sciatic artery allows prophylactic surgical therapy, preventing potential and severe complications, which can compromise lower limb circulation.<sup>2</sup> Treatment of lesions resulting from persistent sciatic artery is very hard, due to its rarity and lack of experience by health professionals, who are usually unaware of its course and have difficulty choosing the best treatment for those lesions. Therefore, it is important to perform further studies on this issue, aiming to make early diagnosis feasible and provide a better follow-up of such complications.

## Report

A 55-year-old female patient, complaining of intense secondary pain at intrinsic compression of the sciatic nerve by aneurysmal dilatation in the right lower limb and pulsatility in the ipsilateral buttock was attended at the hemodynamic sector to undergo lower limb arteriography. On physical examination, there was presence of a hyperpulsatile mass in the right buttock. On pulse assessment, right popliteal artery pulse was normal, femoral artery pulse was very weak and tibial posterior and pedal pulses were absent. On the left, all pulses were present and normal.

An angiographic examination was performed through puncture of the left common femoral artery with selective catheterization of the right common iliac artery. There was presence of hypoplasia of the right femoral artery, whose diameter was reduced, going medially and ending at the thigh distal level, from where some muscle branches emerged. There was also dilatation of the right internal iliac artery ([Figure 1](#)) and posterior circulation of the right lower limb supplied by the sciatic artery. It had focal fusiform aneurysmal dilatation in the right gluteal region ([Figure 2](#)), stenosis in its distal neck and followed a descending and posterior route along the thigh ([Figure 3](#)) until reaching the adductor canal, where it continued as popliteal artery. After popliteal artery filling, leg arteries could not be visualized. There was no persistent sciatic artery in the left lower limb.

Due to risk of distal embolization and intense pain in the right lower limb, the patient was submitted to a surgical procedure, using a transgluteal approach to expose the sciatic artery aneurysm, being careful to identify and avoid sciatic nerve lesion. After dissection and clamping of distal and proximal necks, the aneurysm was open and a large thrombus was removed from the aneurysmal sac. There was no evidence of collateral vessels inside the aneurysm. A terminoterminal Dacron graft was interposed between the proximal and distal necks, and the aneurysmal sac was closed over the graft after part of it was removed. One month after the surgery, the patient reported pain relief and was submitted to arterial color flow Doppler ultrasound, showing graft patency.



**Figure 1 - Angiography showing dilatation of the right internal iliac artery**

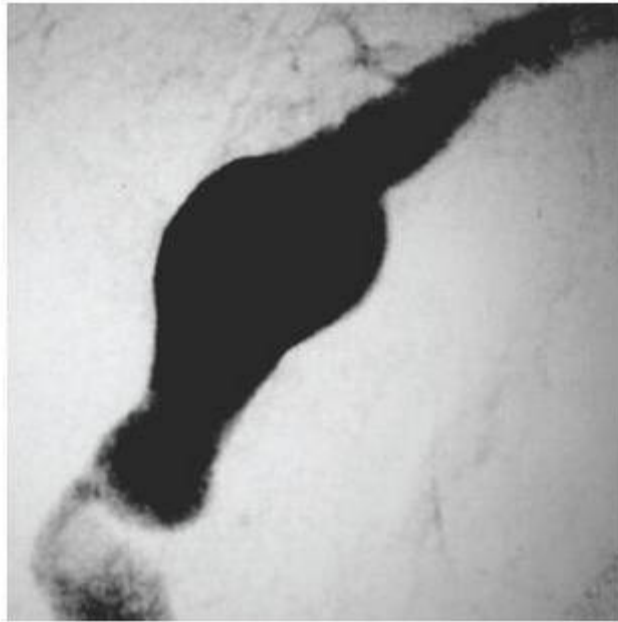
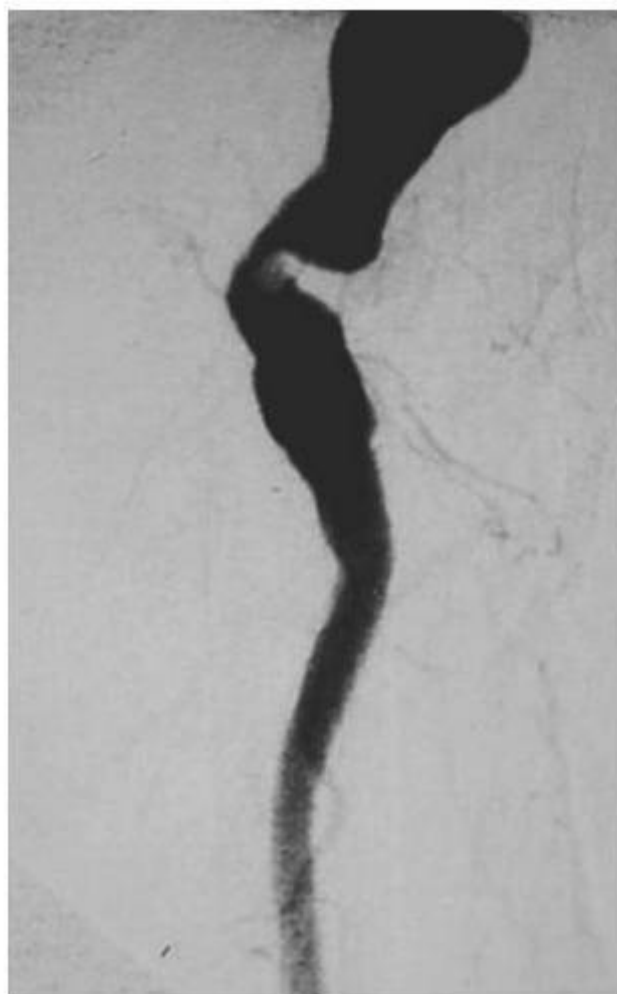

Figure 2 - Focal fusiform aneurysmal dilatation in the right gluteal region



**Figure 3 - Angiography showing sciatic artery with fusiform aneurysmal dilatation with stenosis in its proximal neck and following a descending route**

## Discussion

Incidence of persistent sciatic artery based on angiographic examinations is estimated to be in 0.05%,<sup>2</sup> and when assessed by angiographic tomography in patients with clinical status of acute and/or chronic ischemia, such incidence reaches approximately 1.63%.<sup>5</sup> So far there have been no studies to estimate its incidence in Brazil. Studies carried out by Brazilian authors reported cases including age and gender. Thus, Dias et al.,<sup>6</sup> Oliveira et al.,<sup>7</sup> Araújo et al.<sup>8</sup> and Bez et al.<sup>9</sup> described a variation between 58-74 years, with mean of 64.25 years, three cases being in women<sup>6-8</sup> and only one in the male gender.<sup>9</sup> Age ranged between 42-82 for Maldini et al.,<sup>10</sup> with mean of 62 years. The present study included a 55-year-old female patient.

Bilaterality in persistent sciatic artery, according to Mayschak & Flye,<sup>2</sup> is present in 50% of cases. Araújo et al.<sup>8</sup> described one bilateral case. Dias et al.<sup>6</sup> and Bez et al.<sup>9</sup> found persistence in the right lower limb, and Oliveira et al.<sup>7</sup> in the left lower limb. In our case, there was no bilaterality in persistent sciatic artery.

There are many types of persistent sciatic artery presentation. It is called complete when the sciatic artery serves as direct communication between the internal iliac artery and the popliteal artery. In such cases, the hypoplastic superficial femoral artery usually communicates with the popliteal artery through a variable network of collateral vessels.<sup>11</sup> Mayschak & Flye<sup>2</sup> reported that most cases found in their study included complete sciatic artery. Our study corroborates the reports performed by Dias et al.,<sup>6</sup> Oliveira et al.,<sup>7</sup> Araújo et al.<sup>8</sup> and Bez et al.,<sup>9</sup> and we found the complete type.

Presentation is called incomplete when there is partial involution of the sciatic artery. It becomes hypoplastic and communicates with the popliteal artery through a network of collateral vessels, besides presenting a normal femoral system.<sup>10</sup>

As to incidence of sciatic artery aneurysm, according to Mayschak & Flye<sup>2</sup> it corresponds to 15% of cases and usually occurs under the gluteus maximus muscle at the greater trochanter level. To Maldini et al.,<sup>10</sup> incidence may vary between 15-46%. In the surveyed literature, there were 87 reports of sciatic artery aneurysm until 2002. The basic etiology of aneurysmal dilatation in persistent sciatic artery has not been well established.<sup>10</sup> Compared to the iliac-femoral segment, persistent sciatic artery tends to a larger atheromatous degeneration and its posterior course to gluteal and thigh regions, where it is subject to recurrent traumas, favoring formation of aneurysm, rupture, thrombosis and atheroma embolization. Dias et al.,<sup>6</sup> Oliveira et al.<sup>7</sup> and Araújo et al.<sup>8</sup> reported three cases with presence of aneurysm. In the last study, a case of bilateral aneurysm was described, stressing that there was rupture with hematoma in the right side, besides sciatic artery occlusion and acute ischemia of the affected limb.

Diagnosis of persistent sciatic artery demands a high level of suspicion by the physician, besides being dependent on the patient's clinical presentation and physical examination. It should also be stressed the importance of anatomic configuration of the persistent sciatic artery and whether or not it presents associated aneurysm. Clinical signs and symptoms are usually determined by complications. It is very important to exclude history of recent trauma to avoid false diagnosis of aneurysm.<sup>2</sup> In more than 40% of cases, persistence is asymptomatic and diagnosed through accidental findings, unrelated to formation of aneurysm or other complications.<sup>10</sup>

To Wilson et al.,<sup>11</sup> absence of femoral pulses and presence of distal pulses represent a high level of suspicion of persistent sciatic artery. In hypoplasia or absence of femoral artery, the patient has palpable popliteal and pedal pulses, despite absence or slight reduction in femoral pulse amplitude. Such presentation, called Cowie's signal, is strongly suggestive of complete persistent sciatic artery.

Pain in the gluteal region is considered a nonspecific symptom.<sup>11</sup> It is admitted that it occurs due to proximity of sciatic artery and aneurysm with sciatic nerve, which can also cause sensitive or motor changes in the affected limb. Mayschak & Flye<sup>2</sup> and Maldini et al.<sup>10</sup> admit that presence of a painful mass in the gluteal region may occur. According to Mayschak & Flye,<sup>2</sup> that same mass is pulsatile and could represent aneurysmal dilatation of the artery. Ikezawa et al.<sup>4</sup> found gluteal mass in 25.7% of cases they investigated.

The most frequent clinical finding in persistent sciatic artery is lower limb ischemia. To Maldini et al.<sup>10</sup> it can occur in 63% of cases, and in 25% of them it can be manifested as critical ischemia. Ikesawa et al.<sup>4</sup> reported that 31.1% of patients with symptomatic persistent sciatic artery had ischemia. Wilson et al.<sup>11</sup> reported that rate of aneurysm formation in cases of persistent sciatic artery is high. For its diagnosis, the most widely used instrument is digital subtraction angiography.<sup>5</sup> It is still essential to determine vascularization pattern and provide necessary information to treatment planning.<sup>11</sup> Aziz et al.<sup>12</sup> emphasized the importance of angiography as the gold standard in the detection of vascular lesion, but stressed the need of having good experience

for a proper analysis of angiographic findings.

Color-flow Doppler ultrasound is another diagnostic resource that helps detect persistent sciatic artery. However, computed tomography and angiography stand out in diagnostic confirmation, since they show variation in anatomic configuration of sciatic and femoral arterial systems.<sup>13</sup> Angiographic tomography allows detection of occluded sciatic artery, which cannot be visualized by digital angiography, besides providing assessment of different complications, such as aneurysms, degree of intramural thrombosis, vascular anatomy, artery course and its relation with adjacent structures and possible associated venous anomalies.

In the present study, angiographic examination was performed, as well as in the studied by Oliveira et al.<sup>7</sup> and Araújo et al.<sup>8</sup> Dias et al.<sup>6</sup> added color-flow Doppler ultrasound to angiography, and Bez et al.<sup>9</sup> added angiographic tomography. Jung et al.<sup>5</sup> concluded that angiographic tomography could be used as the only instrument for pretherapeutic assessment of any thromboembolic complication or atherosclerotic change. Angiography through magnetic resonance can be considered as a good diagnostic instrument. However, high cost and technical difficulty restrict its use.<sup>12</sup>

In case of persistent sciatic artery, choice of therapeutic conduct is dependent on artery anatomy and occurrence of complications.<sup>13</sup> To Jung et al.<sup>5</sup> the asymptomatic form of that persistence, although it does not require surgical procedure, should be monitored due to a high risk of thromboembolic complications. Early detection, therefore, allows a more immediate surgical therapy to prevent potential and serious complications.<sup>2</sup>

In the presence of ischemic complications, indication of a surgical treatment is absolute, especially due to risk of chronic ischemia resulting from distal thromboembolism or from aneurysm thrombosis.<sup>14</sup> In complete aneurysm exclusion, suggestion is for some type of revascularization of the superficial femoral artery hypoplastic system.<sup>11</sup> In such cases, there are reports of some types of surgical procedures, such as aneurysm resection and direct anastomosis between two vessel extremities, graft interposition, artery exclusion with proximal and distal ligation, iliac or femoropopliteal *bypass* and endoaneurysmorrhaphy.<sup>14</sup> In our case, the patient was submitted to a surgical procedure in which the aneurysm was excised with graft interposition and removal of a large thrombus, followed by interposition of a Dacron graft with terminoterminal anastomosis. Based on the warning by Ishida et al.,<sup>15</sup> during aneurysm resection, we were careful enough not to cause any lesion to the sciatic nerve.

Surgical procedures, combined with endovascular techniques for aneurysm occlusion, according to Loh,<sup>16</sup> avoid need and risks of surgery on the sciatic artery. Simple arterial embolization is recommended by Song et al.<sup>3</sup> for the treatment of complete and incomplete sciatic artery aneurysms, when there is a good network of collateral vessels. Sogaro et al.<sup>14</sup> suggest choice of embolization using disposable balloons in cases of incomplete type. In complete types, a covered stent could be implanted by endovascular technique.

Most postsurgical complications occur in patients with complete persistent sciatic artery. These patients do not generally have a good network of collateral vessels.<sup>3</sup> Dias et al.<sup>6</sup> reported that, in one case, lower limb amputation was performed. According to Jung et al.,<sup>5</sup> those situations occur due to delay in search for medical treatment. In our case, the patient progressed uneventfully and, 1 month after the surgery, arterial Doppler ultrasound showed good graft patency.

## References

1. Mandell VS, Jaques PF, Delany DJ, Oberheu V. [Persistent sciatic artery: clinical, embryologic, and angiographic features.](#) AJR Am J Roentgenol. 1985;144:245-9.
2. Mayschak DT, Flye MW. [Treatment of the persistent sciatic artery.](#) Ann Surg. 1984;199:69-74.
3. Song HY, Chung GH, Han YM. [Nonoperative management of persistent sciatic artery aneurysm: a case report.](#) J Korean Med Sci. 1992;7:214-20.
4. Ikezawa T, Naiki K, Moriura S, Ikeda S, Hirai M. [Aneurysm of bilateral persistent sciatic arteries with ischemic complications: case report and review of world literature.](#) J Vasc Surg. 1994;20:96-103.
5. Jung AY, Lee W, Chung JW, et al. [Role of computed tomographic angiography in the detection and comprehensive evaluation of persistent sciatic artery.](#) J Vasc Surg. 2005;42:678-83.
6. Dias MH, Lins EM, Interaminense AW, et al. [Persistência da artéria ciática com aneurisma associada à artéria femoral superficial hipoplásica.](#) An Fac Med Univ Fed Pernamb. 1999;44:59-62.
7. Oliveira RSM, Oliveira MK, Maia T, Debs L, Nunes W. [Aneurisma de artéria ciática persistente.](#) Cir Vasc Angiol. 2000;16:130-4.
8. Araújo JD, Nakata LN, Araújo Filho JD, Ciorlin E, Faidiga EB, Hernandez LG. [Aneurisma roto de artéria ciática primitiva.](#) Cir Vasc Angiol. 2001;17:21-7.
9. Bez LG, Costa-Val R, Bastianetto P, et al. [Persistência da artéria isquiática: relato de caso.](#) J Vasc Bras. 2006;5:233-6.
10. Maldini G, Teruya TH, Kamida C, Eklof B. [Combined percutaneous endovascular and open surgical approach in the treatment of a persistent sciatic artery aneurysm presenting with acute limb-threatening ischemia: a case report and review of the literature.](#) Vasc Endovascular Surg. 2002;36:403-8.
11. Wilson JS, Bowser AN, Miranda A, et al. [Limb ischemia associated with persistent sciatic artery aneurysms: a report of 2 cases.](#) Vasc Endovascular Surg. 2005;39:97-101.
12. Aziz ME, Yusof NR, Abdullah MS, Yusof AH, Yusof MI. [Bilateral persistent sciatic arteries with unilateral complicating aneurysm.](#) Singapore Med J. 2005;46:426-8.
13. Urayama H, Tamura M, Ohtake H, Watanabe Y. [Exclusion of a sciatic artery aneurysm and an obturator bypass.](#) J Vasc Surg. 1997;26:697-9.
14. Sogaro F, Amroch D, Galeazzi E, Di Paola F, Mancinelli P, Ganassin L. [Non-surgical treatment of aneurysms of bilateral persistent sciatic artery.](#) Eur J Vasc Endovasc Surg. 1996;12:503-5.
15. Ishida K, Imamaki M, Ishida A, Shimura H, Miyazaki M. [A ruptured aneurysm in persistent sciatic artery: a case report.](#) J Vasc Surg. 2005;42:556-8.
16. Loh FK. [Embolization of a sciatic artery aneurysm an alternative to surgery: a case report.](#) Angiology. 1985;36:472-6.



 Correspondence:

Marco Antonio Prado Nunes

Av. Anízeo Azevedo, 351/502, Ed. Carlos Gomes, Praia 13 de Julho  
CEP 49020-240 – Aracaju, SE, Brazil

Tel.: (79) 3246.2918, (79) 9988.2862

Email: [manprado@uol.com.br](mailto:manprado@uol.com.br)

Manuscript received May 23, 2007, accepted January 14, 2008.